

# The Effect of NaF Mouthrinse, GC Tooth Mousse and GC MI Paste Plus on White Spot Inhibition: An Invitro Study

## Original Article

Navid Karimi Nasab<sup>1</sup>, Reza Davalloo<sup>2</sup>, Fereshteh Nasser Alavi<sup>3</sup>

<sup>1</sup> Associate Professor, Department of Orthodontics, Guilan University of Medical Science, Dental school, Rasht, Iran.

<sup>2</sup> Assistant Professor, Department of Operative Dentistry, Guilan University of Medical Science, Dental School, Rasht, Iran.

<sup>3</sup> Dentist, Guilan University of Medical Science, Dental School, Rasht, Iran.

**Received:** Sep 14, 2011

**Accepted:** Jan 18, 2012

### **Corresponding Author:**

**Fereshteh Nasser Alavi, DDS**

**Address:** Guilan University of Medical Science, Dental School, Imam Street, Opposite Pardis Hotel, Rasht, Iran.

**Telephone:** +98-131-3263622

**Fax:** +98-131-3263623

**E-mail:** [minanasserlavi@yahoo.com](mailto:minanasserlavi@yahoo.com)

## **Abstract**

**Introduction:** To compare the effects of 0.05% sodium fluoride (NaF) mouthrinse, GC Tooth Mousse and GC MI Paste Plus on white spot formation inhibition.

**Materials and Methods:** Thirty pairs of extracted human premolars were cut in half mesio-distally with a disc. The teeth were coated with nail varnish, except a part of the buccal and/or lingual enamel, which was used as the test area, and then divided into 4 groups randomly: A) control, B) 0.05% NaF mouthrinse, C) Tooth Mousse, D) MI Paste Plus. Therapeutic agents were applied once daily following the manufacturer's directions in a PH-cycling model over 35 days. At the end of the experiment, all the specimens were examined in order to detect white spot formation before and after drying (scoring 0-2). Mann Whitney test was used for statistical analysis.

**Results:** The mean of the white spot scores in groups B (0.16), C (1.4) and D (1.2) were significantly lower than group A (2). Significantly lower mean of white spot scores was found in NaF mouthrinse group compared with two other products. No significant difference was observed between Tooth Mousse and MI Paste Plus.

**Conclusion:** Although 0.05% NaF mouthrinse, GC Tooth Mousse and GC MI Paste Plus are effective preparations to inhibit white spot formation, NaF mouthrinse has better efficacy than CPP-ACP (casein phosphopeptide-amorphous calcium phosphate) products.

**Key words:** •Dental caries •Mouthwashes •Sodium Fluoride •Tooth Demineralization •Tooth remineralization

## Introduction

Enamel demineralization around orthodontic appliances is still an old problem in orthodontic treatments. Patients undergoing orthodontic therapy are exposed to a higher risk of enamel demineralization. Appliances are directly attached to tooth surface increasing the difficulty of achieving adequate oral hygiene. Thus, the incidence of the white spot lesions can be significantly higher among orthodontic patients with poor oral hygiene.<sup>(1,2)</sup> Prevalence of such lesions in patients after fixed orthodontic treatment varies between 15 and 85 percent.<sup>(3,4)</sup> Furthermore, lesions developing during 2 years of orthodontic treatment remineralize extremely slowly.<sup>(5,6)</sup>

The effectiveness of fluoride as a anticariostatic agent has been well established and topical fluoride applications are commonly used to arrest the progression of active caries.<sup>(7,10)</sup> With additional oral hygiene instruction and combined with daily use of a sodium fluoride rinse during orthodontic treatment, incipient caries have been reduced by 30 percent.<sup>(3,11)</sup> The sodium fluoride rinses are available as a 0.05 percent daily rinse (225 ppm) or a 0.2 percent weekly rinse (900 ppm). The daily rinse is probably more appropriate for children as it is a smaller dose, and a daily regime extends beyond a routine process and is less likely to be forgotten.<sup>(12)</sup>

Today, bioactive agents based on milk products have been also developed in order to release elements that enhance remineralization of the enamel and dentine, under cariogenic conditions.<sup>(13)</sup> So, these agents in paste formulas have become commercially available:

1-Tooth Mousse (GC Corp., Tokyo, Japan); Topical cream containing CPP-ACP (casein phosphopeptide-amorphous calcium phosphate).

2-MI Paste Plus (GC Corp., Tokyo, Japan); Topical cream containing CPP-ACPF (casein phosphopeptide-amorphous calcium phosphate fluoride). The level of fluoride in this cream is 0.2% (900ppm). Casein phosphopeptides bind to calcium and phosphates, in nano particles, preventing the crystals from growing to critical size and precipitating out of solution. The amorphous calcium phosphate is biologically active and able to release calcium and phosphate ions to maintain the supersaturated state.<sup>(14,15)</sup> The CPP-ACP technology has been demonstrated to have anti-

cariogenic activity in laboratory, animal and human insitu experiments as well as a randomized, controlled caries clinical trial.<sup>(16)</sup>

Since it is unclear which Topical preparations most effectively can inhibit enamel lesions, this study was designed to evaluate and compare the effects of 0.05% NaF mouthrinse, Tooth Mousse and MI Paste Plus on white spot formation inhibition, using an in vitro pH cycling method.

## Materials and Methods

Thirty pairs of extracted human premolars without any clinical sign of decalcification or enamel defects were selected. The teeth (N=60) were extracted from 30 orthodontic patients in the 11-15 age range at the time of the extraction. All the teeth, based on previous studies, were kept in 0.1% thymol solution to inhibit microbial growth, until use.<sup>(17)</sup>

Any soft tissue, calculus and/or bone remaining on the teeth following extraction were removed with a dental scaler. The teeth were cleaned with pumice and water; then, cut in half mesio-distally with a porcelain disk (Bredentcompany, Italy). A carbon pencil was used to map out a horizontal rectangular area (4×5mm) in the middle of the buccal and/or lingual enamel surface of each half of the tooth for exposed window, which was used as a test area. The outside areas of the mapped window were coated with two layers of acid resistant nail varnish (Nivea, Beiersdorf, France). The 120 specimens were divided into four groups randomly:

- A) Control (No treatment)
- B) 0.05% NaFmouthrinse (Behsa pharmaceutical, Arak, Iran)
- C) Tooth Mousse (GC Corporation, Tokyo, Japan)
- D) MI Paste Plus (GC Corporation, Tokyo, Japan)

The specimens in each group were immersed separately in a remineralizing solution for 11 hours and demineralizing solution for 1 hour. Both solutions were agitated constantly and maintained at room temperature. The remineralizing solution, which contained 1.5 mM CaCl<sub>2</sub>, 0.9 mM NaH<sub>2</sub>PO<sub>4</sub> and 0.15 M KCl had a pH of 7. This solution approximates to the supersaturation of apatitic minerals found in saliva.<sup>(18,19)</sup>

After 11 hours the specimens were removed, rinsed with distilled water and transferred to the demineralizing solution for 1 hour. The demineralizing solution which contained 2.2 mM CaCl<sub>2</sub>, 2.2 mM KH<sub>2</sub>PO<sub>4</sub> and 0.05 M acetic acid had a pH adjusted to 4.4 with 1 M KOH.<sup>(18)</sup> After the first caries challenge, the specimens of the group B were immersed in the NaFmouth-rinse for 1 minute. Tooth Mousse and MI Paste Plus were applied to the enamel windows of the groups C and D respectively for three minutes. All the specimens then were returned to the remineralizing solution again.

The specimens were immersed alternately in the remineralizing and demineralizing solution for 35 days (this period had been found in a pilot study to be sufficient to induce white spots in these groups). At this time, the experimental groups (B, C and D) were treated by the therapeutic agents once daily. The solutions were changed every day and their pH levels were monitored.

After a 35 day pH cycle, the nail varnish was removed carefully from each specimen, using acetone (Advanced Technology and Instruments, Co. Ltd, Hong Kong). The buccal and/or lingual enamel surfaces were examined in order to detect white spot formation, before and after drying. The following criteria were used for scoring the specimens:

**Score 0:** No white spot lesion

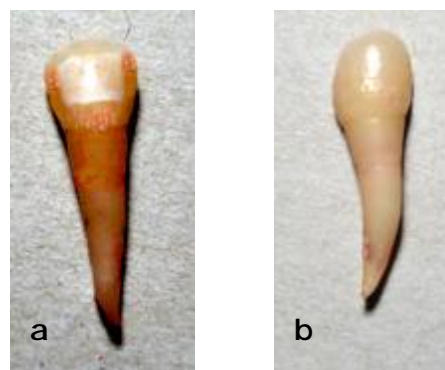
**Score 1:** White spot lesion only in dry enamel

**Score 2:** White spot lesion in humid enamel

The Mann-Whitney nonparametric test was used for statistical analysis.



**Figure 1.** Divided tooth with the test area. The surrounding tooth surface was coated with nail varnish



**Figure 2.** Specimen (a) with and (b) without the white spot formation

## Results

The Frequency of the distribution of white spot scores is given in Table 1.

The means of the white spot scores were significantly lower in the experimental groups (B, C and D) compared with the control group (A) ( $p < 0.0001$ ,  $p < 0.0001$ ,  $p < 0.0001$  respectively) (Table 2).

Result showed significantly lower mean of white spot score in group B compared with groups C and D ( $p < 0.0001$ ,  $p < 0.0001$  respectively). However, no significant difference was observed between groups C and D ( $p = 0.195$ ) (Table 3).

**Table 1.** Frequency of distribution of white spot scores in groups A, B, C and D.

Group	White spot score:n(%)			
	0	1	2	3
A	0 (0)	0 (0)	30 (100)	30 (100)
B	25 (83.3)	5 (16.7)	0 (0)	30 (100)
C	2 (6.7)	14 (46.7)	14 (46.7)	30 (100)
D	3 (10)	18 (60)	9 (30)	30 (100)

**Table 2.** Comparison of mean of white spot scores between experimental groups and control group.

Group(n)	Mean (SD)	P-value*
B(30)	0.16 (0.37)	<0.0001 **
A(30)	2(0)	
C(30)	1.4(0.62)	<0.0001 **
A(30)	2(0)	
D(30)	1.2(0.61)	<0.0001 **
A(30)	2(0)	

\*Mann-Whitney test

\*\*Significant

**Table 3. Comparison of the mean of white spot scores among the experimental groups.**

Group(n)	Mean (SD)	P-value*
B(30)	0.16 (0.37)	<0.0001 **
C(30)	1.4(0.62)	
B(30)	0.16 (0.37)	<0.0001 **
D(30)	1.2(0.61)	
C(30)	1.4(0.62)	0.195
D(30)	1.2(0.61)	

\*Mann-Whitney test

\*\*Significant

## Discussion

Enamel demineralization and white spot lesions are the common side effects occurring during the period of orthodontic therapy with fixed appliances.<sup>(20,23)</sup> After orthodontic treatment, white spots may present an esthetic problem even more than 5 years after treatment. Thus, such lesions appear to be very resistant to remineralization.<sup>(24)</sup>

The results of our study confirmed that a regular daily use of 0.05% NaF mouthrinse can significantly inhibit white spot formation. This finding is in agreement with the study of Meyerowitz et al., who found 0.05 NaF can prevent demineralization and enhance remineralization of enamel, *insitu*.<sup>(25)</sup> Following the application of fluoride, loosely bound fluoride or CaF<sub>2</sub> is formed on the enamel surface or in caries lesions.<sup>(7,26)</sup> CaF<sub>2</sub> is the major product formed when enamel is treated with topical fluoride to react with calcium and phosphate ions.<sup>(7,27,28)</sup> The final product of these reactions may be fluorapatite, which inhibits demineralization and enhances the remineralization of crystals.<sup>(7,29,30)</sup>

In the current study Tooth Mousse (CPP-ACP) and MI Paste Plus (FI-CPP-ACP) significantly reduced white spot formation. Karimi Nasab et al in an *in vitro* caries model study, confirmed that application of casein phosphopeptide preparation (Topacal C-5) can reduce demineralization of enamel by more than 50 per cent.<sup>(31)</sup> The efficacy of the CPP preparation in Karimi Nasab et al study<sup>(31)</sup> was superior to the current study. In their experiment, Topacal C-5 was applied to the specimens after each acid challenge (twice a day). Moreover, the solutions were not renewed every day. So the more amount of this agent remained in the saliva solution. The *in vivo*

study by Bailey et al showed positive effects of Tooth Mousse, during 12 weeks application, on the remineralization of white spot lesions formed during orthodontic treatment.<sup>(32)</sup> Brochner et al reported that topical treatment of white spot lesions after debonding of orthodontic appliances with a CPP-ACP cream (Tooth Mousse) significantly reduced lesions after 4 weeks. However, the improvement was not superior to natural regression with daily use of fluoride toothpaste.<sup>(33)</sup> Pulido et al. also didn't find any inhibitory effects of MI Paste (CPP-ACP) during a 6-day application time on the artificial enamel caries-like lesions progression.<sup>(34)</sup> Perhaps the period and frequency of application of this topical cream has an important role in its efficacy.

Reynolds and colleagues reported that CPP-ACP binds to the surface of the tooth. In this way CPP-ACP deposits a high concentration of ACP in close proximity to the tooth surface.<sup>(35,36)</sup> Under acidic conditions, localized CPP-ACP buffers the free calcium and phosphate ions, substantially increasing the level of calcium phosphate in plaque and therefore, maintaining a state of super saturation that inhibits enamel demineralization and enhances remineralization.<sup>(35-37)</sup>

Trajtenberg et al in an *in vitro* study showed that treatment of root surfaces with CPP-ACP and FI-CPP-ACP significantly improved caries resistance of root surfaces. In addition, the study showed better efficacy of FI-CPP-ACP compared with CPP-ACP.<sup>(38)</sup> In our investigation, although MI Paste Plus (FI-CPP-ACP) reduced white spot formation more than Tooth Mousse (CPP-ACP), its effectiveness wasn't statistically significant. Trajtenberg et al used polarized light microscopy to determine lesion depth of each specimen, but in the current study, only the presence or absence of the white spots (before and after drying the specimens) was scored, independent of the size of the lesions.

In the current study, NaF mouthrinse was more effectively compared with both topical creams, in inhibition of white spot formation. However, Hay and Thomson in an *in vivo* study didn't find significant difference between the caries preventive effect of a mouthrinse solution containing casein derivatives coupled with calcium phosphate (CD-CP) and 0.05NaF mouth-

rinse among individuals with dry mouth.<sup>(39)</sup> Reynolds et al reported, for every 2 fluoride ions, 10 calcium ions and 6 phosphate ions are required to form one unit cell of fluoroapatite [Ca<sub>10</sub>(PO<sub>4</sub>)<sub>6</sub>F<sub>2</sub>]. Hence, on topical application of fluoride ions, availability of calcium and phosphate ions can be limiting for net enamel remineralization to occur and this is exacerbated under xerostomic conditions.<sup>(40)</sup> In our study, the remineralizing solution approximated to the supersaturation of apatitic minerals found in saliva. However in individuals with dry mouth availability of the calcium and phosphate ions, which are needed for the effectiveness of topical fluoride application, are limited.

## Conclusion

Based on the data from this in vitro study it can be concluded that, 0.05% NaF mouthrinse, Tooth Mousse and MI Paste Plus can reduce white spot formation. Comparison among these

agents indicated that NaF mouthrinse has the best inhibitory effects on the enamel lesions.

These self-applied preparations can be recommended to the patients under fixed orthodontic treatments and with poor oral hygiene, in order to reduce enamel demineralization and lesion.

## Acknowledgement

The authors would like to thank the Department of Orthodontics for gathering the teeth.

## References

1. Domingo ST, Bagan JV, Jiménez Y, et al. Benign tumors of the oral mucosa: A study of 300 patients. *Med Oral Patol Oral Cir Bucal* 2008; 13:161-6.
2. Al-Mobeeriek A, AlDosari AM. Prevalence of oral lesions among Saudi dental patients ; *Ann Saudi Med* 2009;29:365-8.
3. Hussain Al-khateeb T. Benign oral masses in a Northern Jordanian Population-a Retrospective Study. *Open Dent J* 2009; 3: 147-153.
4. Mathew AL, Pai KM, Sholapurkar AA, Vengal M. The prevalence of oral mucosal lesions patients visiting a dental school in Southern India. *Indian J Dent Res* 2008; 19: 99-103.
5. Lin HC, Corbet EF, Lo EC. Oral mucosal lesions in Adult Chinese. *J Dent Res* 2001; 80:1486-90.
6. Kovac-Kavcic M, Skaleric U. The prevalence of oral mucosal lesion in a population in Ljubljana, Slovenia. *J Oral Pathol Med* 2000; 29: 331-5.
7. Sapp PJ, Eversole LR, Wysocki GP, (editores). *Patologia oral & maxilofacial contemporanea*. España: Editorial Harcourt Brace; 1998.pp. 277-318.
8. Jahanbani J, Sandvik L, Lyberg T, Ahlfors E. Evaluation of oral mucosal lesions in 598 referred Iranian patients. *Open Dent J* 2009; 27:42-7.
9. Hashemi Pour MA, Rad M, Mojtahedi A. A Survey of Soft Tissue Tumor-Like Lesions of Oral Cavity: A Clinicopathological Study. *I J P* 2008; 3:81- 87.
10. Zarei MR, Chamani G, Amanpoor S. Reactive hyperplasia of the oral cavity in Kerman province, Iran: A review of 172 cases. *Br J Oral Maxillofac Surg* 2007; 45: 288-92.
11. Cardona F. Tumores benignos de la mucosa y submucosa oral. In: Bagan JV, Scully C, (editores) *Medicina y patología oral*. Valencia: Medicina Oral; 2006.PP. 117-26.
12. Esmeili T, Lozada-Nur F, Epstein J. Common benign oral soft tissue masses. *Dent Clin N Am* 49; 2005:223-40.
13. Neville BW, Damn DD, Allen CM, Bouquot JE. *Oral and maxillofacial pathology*. 3rd ed. Philadelphia: WB Saunders Company; 2009. PP. 507-52.



## White spot inhibition

14. Regezi JA, Sciubba JJ. Oral pathology: clinical correlation. 5th ed. Philadelphia: WB Saunders Company; 2008. Pp. 155-78.
15. Tröbs RB, Mader E, Friedrich T, Bennek J. Oral tumors and tumor-like lesions in infants and children. *Pediatr Surg Int* 2003; 19:639-45.
16. Mashhadi Abbas F, Moharamkhani V, Houshmand B, et al. Prevalence of peripheral soft connective tissue lesions in patients referred to pathology department of Shahid Beheshti Dental School, 1981-2006. *Journal of Dental School* 2008; 26:79-84.
17. Chunmuang S, Jitpukdeebodintra S, Chuenarrom C, Benjakul P. Effect of xylitol and fluoride on enamel erosion in vitro. *J Oral Science* 2007; 49:293-7.
18. Kumar VLN, Itthagarun A, King NM. The effect of casein phosphopeptide-amorphous calcium phosphate on remineralization of artificial caries-like lesions: an in vitro study. *Aust Dent J* 2008; 53: 34-40.
19. Ten Cate JM, Duijsters PP. Alternating demineralization and remineralization of artificial enamel lesions. *Caries Res* 1982; 16:201-10.
20. Li S, Hobson RS, Bai Y, et al. A method for producing controlled fluoride release from an orthodontic bracket. *Europ J Orthod* 2007; 29:550-4.
21. Zachrisson B. A post treatment evaluation of direct bonding in orthodontics. *Am J Orthod* 1977; 17:173-89.
22. Artun J, Brobakken BO. Prevalence of carious white spots after orthodontic treatment with multibonded appliances. *Europ J Orthod* 1986; 8:229-34.
23. O'Reilly MM, Featherstone JD. Demineralization and remineralization around orthodontic appliances: an in vivo study. *Am J Orthod Dentofacial Orthop* 1987; 92:33-40.
24. Ogaard B. Prevalence of white spot lesions in 19-year-olds: A study on untreated and orthodontically treated person 5 years after treatment. *Am J Orthod Dentofacial Orthop* 1989; 96:423-7.
25. Meyerowitz C, Featherstone JD, Billings RJ, et al. Use of an intra-oral model to evaluate 0.05 % sodium fluoride mouthrinse in radiation-induced hyposalivation. *J Dent Res* 1991; 70:894-8.
26. Cruz R, Ogaard B, Rolla G. Uptake of KOH-soluble and KOH-insoluble fluoride in sound human enamel after topical application of a fluoride varnish (Duraphat) or a neutral 2 % NaF solution in vitro Scandinavian. *J Dent Res* 1992; 100:154-8.
27. Gerth HU, Dammaschke T, Schafer E, Zuchner H. A three layer structure model of fluoridated enamel containing  $\text{CaF}_2$ ,  $\text{Ca}(\text{OH})_2$  and FAp. *Dental Materials* 2007; 23:1521-1528.
28. Preston KP, Smith PW, Higham SM. The influence of varying fluoride dentinal lesions with differing lesion morphologies. *Arch Oral Biol* 2008; 53:20-6.
29. Hicks J, Garcia Godoy F, Flaitz C. Biological factors in dental caries: role of remineralization and fluoride in the dynamic process of demineralization (part3). *J Clin Ped Dent* 2004; 28:203-14.
30. Yamazaki H, Margolis HC. Enhanced enamel remineralization under acidic conditions in vitro. *J Dent Res* 2008; 87:569-74.
31. Karimi Nasab N, Dalili Kajan Z, Balalaie A. Effect of Topacal C-5 on enamel adjacent to orthodontic brackets, An in vitro study. *Aust Orthod J* 2007; 23: 46-9.
32. Bailey DL, Adams GG, Tsao CE, et al. Regression of post-orthodontic lesions by a remineralizing cream. *J Dent Res* 2009; 88:1148-53.
33. Brochner A, Christensen C, Kristensen B, et al. Treatment of post-orthodontic white spot lesions with casein phosphopeptide-stabilized amorphous calcium phosphate. *Clin Oral Invest* 2011; 15:369-73.
34. Pulido MT, Wefel JS, Hernandez MM, et al. The Inhibitory effect of MI Paste, fluoride and a combination of both on the progression of artificial caries-like lesions in enamel. *Oper Dent* 2008; 33:550-5.
35. Reynolds EC, Cain CJ, Webber FL, et al. Anti cariogenicity of calcium phosphate complexes of tryptic casein phosphopeptides in the rat. *J Dent Res* 1995; 74:1272-9.
36. Reynolds EC, Black CL, Cross KJ, et al. Advances in enamel remineralization :anticariogenic casein phosphopeptide-amorphous calcium phosphate. *J Clin Dent* 1999; 10:86-8.
37. Azarpazhooh A, Limeback H. Clinical efficacy of casein derivatives. *J Am Dent Assoc* 2008; 139:915-24.

38. Trajtenberg CP, Flaitz C, Hicks J. CPP-ACP paste with fluoride: In vitro root surface caries formation. *Canad J Dent Hygien* 2007; Abstract.
39. Hay KD, Thomson WM. A clinical trial of the anticaries efficacy of casein derivatives complexed with calcium phosphate in patients with salivary gland dysfunction. *Oral Surg Oral Med Oral Path Oral Rad Endod* 2002; 93:271-5.
40. Reynolds EC, Cai F, Chocrance NJ, et al. Fluoride and casein phosphopeptide amorphous calcium phosphate. *J Dent Res* 2008; 87:344-8.