

# Case Report: A Simple Technique For Creating An Improved Pre-Contoured Matrix Band



Seyedeh Maryam Tavangar<sup>1</sup> , Reza Tayefeh Davaloo<sup>1</sup> , Farideh Darabi<sup>1</sup> , Hoorieh Alsadat Hosseini Basti<sup>2</sup>

<sup>1</sup>Associate professor, Dental Sciences Research Center, Department of Restorative Dentistry, Faculty of Dentistry, Guilan University of Medical Sciences, Rasht, Iran

<sup>2</sup>Assistant professor, Dental Sciences Research Center, Department of Restorative Dentistry, Faculty of Dentistry, Guilan University of Medical Sciences, Rasht, Iran

Use your device to scan  
and read the article online



**Citation:** Tavangar M, Tayefeh Davaloo R, Darabi F, Hosseini Basti H. A Simple Technique For Creating An Improved Pre-Contoured Matrix Band. Journal of Dentomaxillofacial Radiology, Pathology and Surgery. 2023; 12(3):23-27. <http://dx.doi.org/10.32598/3dj.7.4.145>

<http://3dj.gums.ac.ir>



## ABSTRACT

When placing a proximal resin composite restoration, it is recommended to use a matrix system for restoring interproximal surfaces. Although sectional matrix systems are useful, they can be technique-sensitive and are passively placed. There is a need for an improved matrix band that overcomes these shortcomings. The objective of this study is to introduce a new technique for interproximal restoration of composite resin using a matrix system.

### Article info:

**Received:** 2023/03/11

**Accepted:** 2023/11/25

### Keywords:

Dental Caries

Composite Resins

Matrix Bands

### \* Corresponding Author:

**Hoorieh Alsadat Hosseini Basti**

**Address:** Faculty of Dentistry, Lakan,  
Rasht, Guilan, IRAN

Postal Code:41941-73774

**Tel:** +98 -13 33486416

**E-mail:** hosseini.hurieh@yahoo.com

## Introduction

### *Case report*

Advances in materials science and technology have led to the adoption of strategies that transform the mechanistic approach of dentistry into a biologic form. Composite resins have emerged as an aesthetically pleasing means of restoring cavities over the last few decades, prompting clinicians to adjust their protocols and principles for using metallic restorations. Techniques have rapidly evolved to address issues with posterior composites, such as polymerization shrinkage. The challenge of achieving contacts in posterior proximal restorations has also been acknowledged (1). The longevity of posterior composite resin is linked to factors like postoperative sensitivity, difficulties in achieving proximal contacts, and recurrent caries. Overcoming these challenges requires attention to clinical technique(2). Proximal surfaces should present a well-contoured reconstruction to establish good proximal contact, as deficient contouring can lead to microbial biofilm accumulation. In proximal restorations, the universal matrix or Tofflemire system is employed to restore anatomic contours and the contact area. The matrix band acts as an anatomical tooth-encircling wall. An ideal matrix should be rigid enough to achieve this goal and prevent gingival overhang. For the contour to facilitate matrix adaptation to tooth structure, the flat matrix should be burnished and shaped using a burnisher or the blunt end of an instrument rubbing back and forth, introducing curvature to the matrix band. The occlusal portion of the matrix band extends 1.5-2 mm above the marginal ridge of the adjacent tooth, while the gingival portion should be seated 0.5 mm below the gingival margin. The wedge used should not interfere with the curvature of the matrix. In challenging situations, such as deep cavosurface margins, achieving proper fitness can be difficult. Care should be taken to prevent the matrix band from being too tight, which can result in an open contact. Difficulties in adapting resin to cervical walls and adjusting proximal contacts are common challenges

in composite placement. The type and shape of the matrix system influence the restoration's performance. Using a spoon excavator or burnisher to burnish the band to the adjacent tooth is useful(3). The matrix band's role is akin to an anatomical tooth wall for the filling material, retaining the shape of the restoration material until it hardens. However, matrix bands have some disadvantages. They are made from flexible and ductile materials that pose challenges during placement, especially when distances are smaller than the band's thickness. In such cases, clinicians should carefully guide the band between the loosened wedge and the gingival margin(4). Sectional, pre-contoured matrices have been developed to address issues with rebuilding the lost proximal portion. These matrices are beneficial for creating proximal contacts and are used in combination with a separating ring to separate teeth and stabilize the matrix. Circumferential matrices result in inferior morphological contacts with reduced contact tightness. Factors related to the dental practitioner affect the quality of composite restorations(5). Annealing, a heat treatment process, enhances ductility, improves toughness, and reduces material hardness. A matrix band is a piece of metal composed of a network of crystal structures that cause stress to the metal with their placement. In the first stage of annealing, the internal stress can dissipate(6). Various matrix systems, including flat or pre-contoured bands, circumferential and sectional matrices, are available, made from either metal or plastic materials(7). The Tofflemire matrix system has flaws in creating tight and properly-contoured proximal contacts, leading to the use of the sectional matrix (8). Consensus in the literature indicates that pre-contoured matrices are superior to flat ones for creating interproximal contacts and profiles(9). The aim of this study was to introduce a simple technique for creating a pre-contoured matrix band that allows for the creation of a desired contour for dental restoration.

### *Technique*

The test tooth was positioned between two

other teeth to simulate physiological interproximal relations. A rubber dam (Sanctuary Latex Dental Dam, Malaysia) was used for the operation field isolation. One mesio-occluso-distal (MOD) cavity with cervical margins in enamel and dentin was prepared and restricted to the removal of carious tissue and assigned to a new treatment protocol (Figure 1).

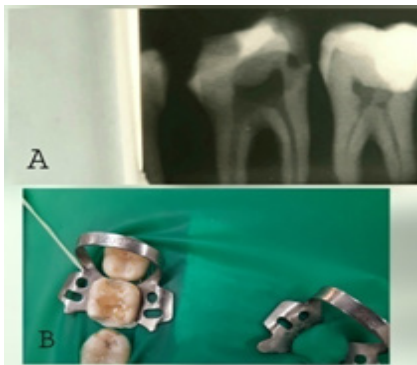


Figure 1: A: Pre-operative X-ray picture - B: Pre-operative intra oral picture

A thin, flexible metal matrix band (Arnel Dental Products, Tofflemire-type matrix bands, made in the USA) was shaped to the desired proximal contour. The metal band was deformed occlusogingivally with a burnisher (Kousha, Pakistan) using firm pressure. The No.26-28 burnisher is generally recommended. Then, it was annealed with a torch flame gun. It was held in place on a wooden stick, and a burnisher rubbed the matrix band back and forth to introduce a curvature into it (Figure 2).

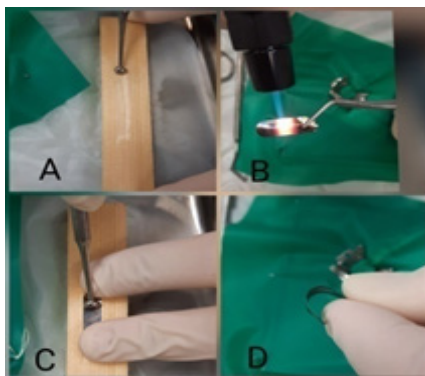


Figure 2: A: Wooden stick and burnisher- B: Torch usage - C: Matrix shaping - D: Final contour of dental matrix

The matrix was secured interdentally and cervically with wooden wedges and laterally at the vertical cavity margins with a separation ring. The contact area was burnished with a hand instrument so that no visual space was

left between the matrix and the adjacent tooth. Enamel and dentin were etched for 30 and 15 seconds, respectively, with 37% phosphoric acid gel (Super Etch, SDI, Australia), then rinsed with water spray, and dried. A two-step etch and rinse bonding agent (Ambar, FGM, Brazil) was applied for two consecutive layers and light-cured with an LED light curing device from the occlusal for 20 seconds (Blue Dent LED Light Cure, light intensity 1500mw/cm<sup>2</sup>, wavelength 410-490 nm, Bulgaria). The cavity was filled with composite (Opallis, FGM, Brazil) using a centripetal layering technique where the initial restoration involved the absent proximal wall and transferred the proximal cavity into an occlusal one. Each composite increment was light-cured from occlusal for 20 seconds. After the removal of the matrix system, the restoration was additionally light-cured for 20 seconds from the buccal, lingual, and occlusal aspects.

Care was taken during composite insertion to minimize finishing (Figure 3)

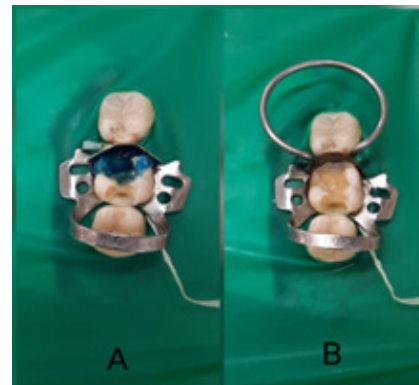


Figure 3: A and B: Steps of tooth restoration

Marginal quality was assessed using a periapical radiograph (Figure 4).

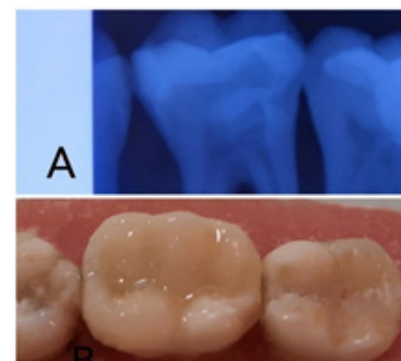


Figure 4: A and B: Final pictures

## Discussion

The evolution of adhesive systems and improvement of mechanical properties of materials have led to the application of tooth-colored materials in posterior teeth. These materials preserve the sound tooth structure and reinforce the restored tooth. Modern restorative dentistry focuses on high-quality, long-lasting restorations(10). Proximal cavities restored with composite resin should present a well-contoured reconstruction and achieve good proximal contact.

Matrix bands, commonly referred to as matrix strips are thin, strong, dead soft and memory free stainless steel bands for use with amalgam, composite, or other suitable materials that allow the creation of an ideal restoration contour and shield the sides of adjacent teeth from one another(11). Black recognized the importance of the matrix band and described several types. Green and Shellman reviewed their history. Today, improvements in the mechanical properties of adhesive materials have led to increased emphasis on aesthetics and the application of tooth-colored materials in posterior teeth(12). Proximal matrices should reconstruct a well-contoured structure for good proximal contact(13). The inherent polymerization shrinkage could cause marginal adhesion to break down. The main location of marginal breakdown and secondary caries is the cervical wall, which is the most prevalent reason for the replacement of restorations(14). The difficulty of adapting resin composite and correctly adjusting proximal contacts are problems associated with composite placement(15). Another factor that influences restoration performance is the proximal contour, which depends on the type and shape of the matrix system. The matrix band determines the shape of the proximal contour. Various restorative techniques have been suggested for composite proximal restoration, such as using translucent matrix bands that are difficult to attain proximal contact compared to metallic matrices, and higher amounts of proximal excesses could be expected(16). Marginal adaptation, staining,

anatomy, and recurrent caries could differentiate materials and techniques(17). Studies have shown that pre-contoured matrices are beneficial for creating proximal contacts. The Tofflemire matrix system may cause flaws in creating tight and properly-contoured proximal contacts. Heat treatment is used to alter the physical and mechanical properties of metal. Annealing allows bending metal and forming it into our desired shapes. The torch instrument can be used for annealing. The torches produce a flame with a stable heat of 2600 Fahrenheit by a rechargeable butane gas tank and a piezoelectric ignition system, which is used for forming, melting, and sterilizing. The incidence of food impaction is higher when the circumferential matrix is used. Tofflemire matrices cannot predictably establish anatomically-correct proximal contact with composite resins because of the low resistance of the matrix band to deformation, resulting in point contacts(7, 9). Poor contouring and repairing such proximal surfaces may lead to a plaque- and food-retentive area. The success or failure of composite restorations is a multifactorial process in which material, patient, and operator-related factors are combined. Dental practitioner-related factors, such as the selection of the dental matrix system, affect the quality of composite restorations. The main clinical advantage obtained with this method is easier handling of the matrix system and achieving a better contact and contour area.

## Conclusion

The present technique overcomes the drawbacks of dental matrix bands known in restorative procedures and can be used as a simple method to create a prefabricated dental matrix.

### *Acknowledgments*

None

### *Authors' contributions*

**Seyedeh Maryam Tavangar:** Conceptualization, Methodology, Writing - Review & Editing **Reza Tayefeh Davaloo:** Resources, Investigation, Visualization **Farideh Darabi:**



Data curation, Writing - Original Draft **Hoorieh Alsadat Hosseini Basti**: Project administration, Supervision, Funding acquisition

**Conflict of interest:**

The authors declare no conflict of interest.

**Ethics consideration:**

This article evaluated by research ethics committees of Guilan university of medical sciences and the approval ID is IR.GUMS.REC.1402.409.

**Financial support**

None

**Availability of data and material**

The datasets used and/or analyzed during the current study are available from the corresponding author on reasonable request.

**References**

1. Soares PV, Allig GR, Wobido AR, Machado AC. Composite resin in the last 10 years-literature review. Part 2: Mechanical properties. J Clin Dent Res. 2019;16(1):58-72. <https://doi.org/10.14436/2447-911x.16.1.058-072.oar>
2. Yadav S, Verma PK, Samant PS, Singh AR, Chauhan R. Failure of Composite Restorations: An Overview. Asian Journal of Oral Health & Allied Sciences Volume. 2019;9(1):28.
3. Torres CRG, Balsamo M, Imazato S. Composite Restoration on Posterior Teeth. Modern Operative Dentistry: Principles for Clinical Practice. 2020:577-630. [https://doi.org/10.1007/978-3-030-31772-0\\_15](https://doi.org/10.1007/978-3-030-31772-0_15)
4. Elyasaky MA, Elsharkawy DA. The Influence of Placement Technique and Composite Type on the Proximal Contact in Class II Resin Restorations. Al-Azhar Dental Journal for Girls. 2020;7(4-C):531-5. <https://doi.org/10.21608/adjg.2020.14048.1168>
5. Peumans M, Venuti P, Politano G, Van Meerbeek B. Effective protocol for daily high-quality direct posterior composite restorations. The interdental anatomy of the class-2 composite restoration. J Adhes Dent. 2021;23(1):21-34.
6. Ismail NM, Khatif NAA, Kecik MAKA, Shaharudin MAH, editors. The effect of heat treatment on the hardness and impact properties of medium carbon steel. IOP conference series: materials science and engineering; 2016: IOP Publishing. <https://doi.org/10.1088/1757-899X/114/1/012108>
7. Shaalan OO. Evaluation of matrix band systems for posterior proximal restorations among Egyptian dentists: a cross-sectional survey. Acta Stomatologica Cro-

- atica. 2020;54(4):392. <https://doi.org/10.15644/asc54/4/6>
8. Awad MM, Alradan M, Alshalan N, Alqahatani A, Alhalabi F, Salem MA, et al. Placement of posterior composite restorations: a cross-sectional study of dental practitioners in Al-kharj, Saudi Arabia. International Journal of Environmental Research and Public Health. 2021;18(23):12408. <https://doi.org/10.3390/ijerph182312408>
9. Ahmad MZ, Gaikwad RN, Arjumand B. Comparison of two different matrix band systems in restoring two surface cavities in posterior teeth done by senior undergraduate students at Qassim University, Saudi Arabia: A randomized controlled clinical trial. Indian Journal of Dental Research. 2018;29(4):459. [https://doi.org/10.4103/ijdr.IJDR\\_26\\_17](https://doi.org/10.4103/ijdr.IJDR_26_17)
10. Huerta JT, Bermudez JM, Quinteros DA, Allemandi DA, Palma SD. New trends, challenges, and opportunities in the use of nanotechnology in restorative dentistry. Nanobiomaterials in Dentistry. 2016:133-60. <https://doi.org/10.1016/B978-0-323-42867-5.00006-0>
11. El-Shamy H, Sonbul H, Alturkestani N, Tashkandi A, Loomans BA, Doerfer C, et al. Proximal contact tightness of class II bulk-fill composite resin restorations: An in vitro study. Dental materials journal. 2019;38(1):96-100. <https://doi.org/10.4012/dmj.2017-279>
12. Azeem RA, Sureshbabu NM. Clinical performance of direct versus indirect composite restorations in posterior teeth: A systematic review. Journal of conservative dentistry: JCD. 2018;21(1):2.
13. Deepak S, Nivedhitha M. Proximal contact tightness between two different restorative materials-An in vitro study. Journal of Advanced Pharmacy Education & Research. 2017;7(2).
14. Nedeljkovic I, De Munck J, Vanloy A, Declerck D, Lambrechts P, Peumans M, et al. Secondary caries: prevalence, characteristics, and approach. Clinical oral investigations. 2020;24:683-91. <https://doi.org/10.1007/s00784-019-02894-0>
15. Karacan AO, Ozyurt P. Effect of preheated bulk-fill composite temperature on intrapulpal temperature increase in vitro. Journal of Esthetic and Restorative Dentistry. 2019;31(6):583-8. <https://doi.org/10.1111/jerd.12503>
16. Hinton O. Proximal contact tightness for Class II direct composite resin restorations: a literature review. Dental Update. 2021;48(9):733-40. <https://doi.org/10.12968/denu.2021.48.9.733>
17. Estay J, Martín J, Viera V, Valdivieso J, Bersezio C, Vildosola P, et al. 12 years of repair of amalgam and composite resins: a clinical study. Operative Dentistry. 2018;43(1):12-21. <https://doi.org/10.2341/16-313-C>