

Research Paper: Evaluation the condylar bony changes in CBCT images of patients referring to Radiology Center of Shahid Beheshti Dental School in 2019



Mahkameh Moshfeghi¹ , Mona Golbar^{*2} , Yaser safi¹ , Neda Lotfi² , Farivar Dastan²

¹Assistant professor, Department of Oral and Maxillofacial Radiology, School of Dentistry, Shahid Beheshti University of Medical Sciences, Tehran, Iran

²Postgraduate Student of Orthodontics, Department Of Orthodontics, School of Dentistry, Shahed University of Medical Sciences, Tehran, Iran

Use your device to scan
and read the article online



Citation: Moshfeghi M, Golbar M, Safi Y, Lotfi N, Dastan F. Evaluation the condylar bony changes in CBCT images of patients referring to Radiology Center of Shahid Beheshti Dental School in 2019 Journal of Dentomaxillofacial Radiology, Pathology and Surgery. 2020; 9(3):13-17. <http://dx.doi.org/>



<http://3dj.gums.ac.ir>



ABSTRACT

Introduction: The temporomandibular joint's disease is a group of complex diseases, many of which have no clinical signs and are identified through diagnostic assays, including radiological images. One of the methods of imaging that provides information about this disease is CBCT imaging. The purpose of this study was to evaluate the condylar bony changes in CBCT images of patients referring to the Radiology Center of a Dental School in 2019.

Materials and Methods: In this descriptive cross-sectional study, CBCT radiographs of 206 patients (121 females and 85 males) referring to the Radiology Center of a Dental School were chosen in order to determine hypoplasia, hyperplasia, bifid condyle, sclerotic changes, flattening, erosion and osteophyte in both sides. These radiographs were studied by a trained dentistry student to determine the changes.

Results: The prevalence of condylar bony changes was 65.3% and no difference was observed between right and left condyles. The highest frequencies of condylar bony changes was related to flattening with a frequency of 131 condyles (31.7%), erosion with a frequency of 78 condyles (18.9%) and osteophyte with a frequency of 76 condyles (18.4%).

Conclusion: In the population of this study, there is a correlation between age and the prevalence of condylar bony changes and the prevalence of flattening, erosion, and osteophyte. Erosion also significantly increased in women and osteophyte increased in men.

Article info:

Received: 2020/10/05

Accepted: 2020/10/15

Keywords:

Humans,
Radiology,
Temporomandibular
Joint Disorders, Spiral
Cone-Beam Computed
Tomography disorders

* Corresponding Author:

Mona Golbar.

Address: Department Of Orthodontics,
School of Dentistry, Shahed University
of Medical Sciences,
Tehran, IR Iran

Tel: +98 9181333424

E-mail: Monagolbar@gmail.com

Introduction

The temporomandibular joint is one of the most important joints in body that has a close relationship with oral and dental cavities. The disease of this joint is a group of complex and heterogeneous diseases with different etiologies (1). It has various etiological factors such as stress, trauma, degenerative diseases, excessive muscle activity, infection, and orthopedic stability (2). Clinical signs of the disease include pain, click, restriction of the mouth opening, mandibular deviation when opening and closing the mouth, headache, earache, muscle tenderness, and malocclusion. Diagnosis of these diseases is usually by history, clinical examination, and imaging of the joint (3). Not all people with temporomandibular joint disease have clinical symptoms, so clinical examination should not be confined alone to diagnose degenerative changes and complementary diagnostic methods should also be used. One of these methods is proper imaging of the joint (4,5). One of the types of imaging is panoramic, despite its many benefits, it delivers thick image layers and an oblique and displaced image of the joint, thus a more advanced technique for temporomandibular joint examination is required (6). A new technique is CT, which is used to examine the cortical bone and the temporomandibular joint. New diagnostic techniques such as MRI and CBCT are used, because of the high cost and high dose of CT imposed on the patient (7). CBCT, as a new 3D imaging technique in dentistry, can accurately visualize articular structures and is more suitable for diagnosing bony changes than MRI (8, 9). Recent studies have confirmed the high accuracy of CBCT in evaluating the different dimensions of the temporomandibular joint (10). For example, the diagnostic power of this technique is 0.8 compared to macroscopic observation in autopsy specimens (11). As a result, CBCT is the method of choice for the examination the bony components of the temporomandibular joint (12). So far, little research has been done on the prevalence of condylar bony changes in Iranian society. Regarding to the importance of this subject, the present study

aimed to investigate the frequency of condylar bony changes and their frequency according to age and sex among patients referred to a Dental School.

Material and Methods

This descriptive study was performed on 206 patients (412 condyles) referred to a Dental School in 2019. In this study 121 (59.5%) patients were female and 85 (40.5%) were male. The mean age of the patients were 42 ± 16.9 years, ranging from at least 10 years to a maximum of 72 years. For this purpose, a CBCT radiographic file from these patients, prescribed for various therapeutic purposes, in which both right and left condylar images were visible, was selected. Age, sex, type of bony change, bilateral or unilateral and the involved side were assessed and recorded in the case file. At the beginning of the study, a senior dental student was trained by a resident of oral, maxillofacial radiology, and then CBCT files were examined. The device used for CBCT images was the NEW TOM VGI made in Italy. The images were selected from the archive with fields of 12*8 and larger and analyzed by NNT software. At first, the images were viewed as MPR overviews. Multipolar images were then viewed in sagittal and coronal sections with 1 mm Slice Thickness and 1 mm Interval. Bony changes that was studied in this article included flattening (fig a), erosion (fig b), osteophyte (fig c), hyperplasia, hypoplasia and sclerotic changes. Images in which only one condyle was visible or having any lesion, pathology, or fracture in the condyle or glenoid fossa were excluded.

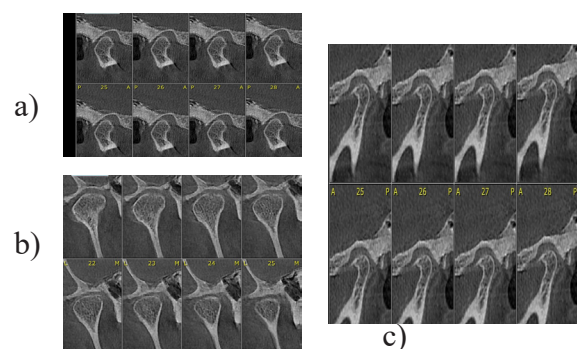


Fig1: flattening

The data were analyzed by SPSS Statistics for Windows, version 20. Descriptive statistical methods were used to evaluate the data. The Chi-square test and McNemar's test were used to evaluate comparisons. Significance was accepted at the $P < 0.05$ level.

Results

In this study, the highest frequency of condylar bony changes was related to the flattening with 131 (31.7%), erosion with 78 (18.9%) and osteophyte

with 76 (18.4%), respectively. The most frequent changes of the right condyles were erosion with 44 condyles (21.4%), flattening with 33 condyles (16%) and sclerotic changes with 18 condyles (8.7%). The most frequent changes of the left condylar bones were related to flattening with 30 condyles (14.6%), erosion 26 condyles (12.6%) and osteophyte 21 condyles (10.2%). In this study 64 patients had bilateral bony changes (Table 1).

Table 1: Examination of the types of condylar bony changes by location

Bony change The conflict side	Hypoplasia	Hyperplasia	Bifide Condyle	Sclerotic Changes	Flattening	Erosion	Osteophyte
Right condyle	3(1.5%)	1(0.5%)	1(0.5%)	18(8.7%)	33(16%)	44(21.4%)	17(8.3%)
Left condyle	3(1.5%)	1(0.5%)	0	7(3.4%)	30(14.6%)	26(12.6%)	21(10.2%)
two-sided	0	0	0	7(3.4%)	34(14.5%)	8(1.9%)	19(9.2%)
Total	6(1.5%)	2(0.5%)	1(0.25%)	39(9.5%)	131(31.7%)	78(18.9%)	76(18.4%)

There was a significant relationship between age and the prevalence of flattening

($P < 0.001$), erosion ($P = 0.004$) and osteophyte in condyle ($P = 0.005$) (Table 2).

Table 2: Examination of the types of bony changes by age

Bony change Age category	Flattening	Erosion	Osteophyte	Sclerotic Changes
Age 10-19	5(18.5%)	4(14.8%)	2(7.4%)	(0%)
Age 20-29	6(16.5%)	7(19.4%)	5(13.9%)	3(8.3%)
Age 30-39	18(48.4%)	13(34.2%)	9(23.7%)	6(15.8%)
Age 40-49	24(66.7%)	15(41.7%)	12(33.3%)	9(25%)
Age 50-59	26(68.4%)	21(55.3%)	16(42.1%)	7(18.4%)
60 years and older	18(58.1%)	14(45.2%)	13(41.9%)	7(22.6%)

Erosion was significantly higher in women ($p = 0.005$) and

osteophyte was significantly higher in men ($p = 0.041$) (Table 3).

Table 3: Examination of the types of bony change by sex

Bony change Gender	Flattening	Erosion	Osteophyte	Sclerotic Changes
woman	55	53	27	20
Man	42	21	30	12

Discussion

Temporomandibular joint disease is one of the painful craniofacial diseases that can affect the temporomandibular joint, masticatory

muscles, and musculoskeletal structures. In current guideline, complex etiology and multi factors have been mentioned for this condition (13). Temporomandibular disorders are usually

associated with degenerative bony changes such as erosion, flattening, osteophytes, and sclerotic changes so radiographic evaluation is an important part of the clinical evaluation of temporomandibular joint. In the last three decades, various imaging modalities have been introduced, however, there is no single method for a complete and accurate examination of all components of temporomandibular joint. Among radiographic methods, CBCT has better diagnostic accuracy than panoramic and has low dose and cost comparing to CT (14).

The results of the present study showed that the prevalence of condylar bony changes was 65.3% and there was no significant difference between the right and left condyle. In Shahidi's article reported prevalence of articular bony changes in 90% and 86.7% of patients with and without symptoms (15). Dos Anjos, reported a prevalence of 71% condylar bony changes and there was no difference between the right and left condyle (3). In the present study, the most common condylar bony changes were reported as flattening, erosion, and osteophyte, respectively. In a study which examined the temporomandibular bony changes with CBCT and its association with clinical symptoms and in another study which investigated the relationship between pain and degenerative condylar bony changes, the most common bony change was flattening (17, 16). de Holanda TA (2018), reported osteophyte the most common degenerative joint disease in a retrospective CBCT study (18). In Shetty's article like this study, the most common bony change in condyle were erosion, flattening and osteophyte (10).

According to the results of this study, there was a statistically significant relationship between age and condylar bony changes. In Shahab's (2017) study, there was no relationship between age and condylar bony changes, if there was more samples in the study, there might be relationship between these two variable factors (16). SC Sa (2017), also reported a statistically significant association between sex and condylar bony changes (19). Borahan (2016), reported an increase in the prevalence of condylar bony

changes with age over 60 years in his study (2).

According to the results of this study, the prevalence of flattening, erosion, and osteophyte significantly increased with age. The prevalence of erosion in women and osteophyte in men was also significantly higher. Koç N (2020), reported Significant differences in the mean ages with regard to the condylar erosion and osteophyte (20). Bae (2017), in his study, showed that the prevalence of osteophytes and erosions increased with age (21). Alexios reported a statistically significant difference in the mean age of patients with moderate erosion and no erosion in the study of severity of temporomandibular joint osteoarthritis in relation to age using CBCT (2009). In this study there was a significant difference between severe osteophyte and the absence of osteophyte in terms of mean age (22).

In conclusion, the results of this study showed that the prevalence of condylar bony changes was 65.3%, with no difference between the right and left condyle. The most frequent bony changes were flattening with 131 (31.7%), erosion 78 (18.9%) and osteophyte 76 (18.4%), respectively, and other changes in subsequent rankings.

Conclusion

There was a statistically significant relationship between bony changes and aging. There was also a relationship between flattening, erosion, and osteophyte with increasing age. Erosion was significantly higher in females and osteophytes in males.

Acknowledgement

None

Conflicts of interest

There are no conflicts of interest

References

1. Barghan S, Merrill R, Tetradis S. Cone beam computed tomography imaging in the evaluation of the temporomandibular joint. *Tex Dent J* 2012; 129: 289-302.
2. Borahan MO, Mayil M, Pekiner FN. Using cone beam computed tomography to examine the prevalence of condylar bony changes in a Turkish subpopu-

- lation. *Niger J Clin Pract* 2016; 19: 259-266. <https://doi.org/10.4103/1119-3077.164336>
3. dos Anjos Pontual ML, Freire JS, Barbosa JM, et al. Evaluation of bony changes in the temporomandibular joint using cone beam CT. *Dentomaxillofac Radiol* 2012; 41: 24-29. <https://doi.org/10.1259/dmfr/17815139>
 4. Al-koshab M, Nambiar P, John J. Assessment of condyle and glenoid fossa morphology using CBCT in South-East Asians. *PLoS One* 2015; 10: e0121682. <https://doi.org/10.1371/journal.pone.0121682>
 5. Ferraz Junior AM, Devito KL, Guimaraes JP. Temporomandibular disorder in patients with juvenile idiopathic arthritis: clinical evaluation and correlation with the findings of cone beam computed tomography. *Oral Surg Oral Med Oral Pathol Oral Radiol* 2012; 114:e51-e57. <https://doi.org/10.1016/j.oooo.2012.02.010>
 6. Honda K, Larheim TA, Maruhashi K, et al. Osseous abnormalities of the mandibular condyle: diagnostic reliability of cone beam computed tomography compared with helical computed tomography based on an autopsy material. *Dentomaxillofac Radiol* 2006; 35:152-157. <https://doi.org/10.1259/dmfr/15831361>
 7. Larheim TA, Abrahamsson AK, Kristensen ML, et al. Temporomandibular joint diagnostics using CBCT. *Dentomaxillofac Radiol*. 2015; 44:20140235. <https://doi.org/10.1259/dmfr.20140235>
 8. Manjula W. S, Faizal T, Murali R., et al. Assessment of optimal condylar position with cone-beam computed tomography in south Indian female population. *J Pharm Bioallied Sci* 2015; 7:121-124. <https://doi.org/10.4103/0975-7406.155855>
 9. Nah K.S. Assessment of Condylar bony changes in patients with temporomandibular disorders: a CBCT study. *Imaging Sci Dent* 2012; 42:249-253. <https://doi.org/10.5624/isd.2012.42.4.249>
 10. Shetty U.S, Krishna N.B, Venkatesh G.N, et al. Assessment of condylar changes in patients with temporomandibular joint pain using digital volumetric tomography. *Radiol Res Pract*, 2014; 2014:106059. <https://doi.org/10.1155/2014/106059>
 11. Talaat W, Al Bayatti S, Al Kawas S. CBCT analysis of bony changes associated with temporomandibular disorders. *CRANIO®* 2016; 34: 88-94. <https://doi.org/10.1179/2151090315Y.0000000002>
 12. Alkhader M, Kuribayashi A, Ohbayashi N, et al. Usefulness of cone beam computed tomography in temporomandibular joints with soft tissue pathology. *Dentomaxillofac Radiol* 2010; 39:343-348. <https://doi.org/10.1259/dmfr/76385066>.
 13. Geiger DI, Bae W.C, Statum S, et al. Quantitative 3D ultrashort time-to-echo (UTE) MRI and micro-CT (muCT) evaluation of the temporomandibular joint (TMJ) condylar morphology. *Skeletal Radiol* 2014; 43: 19-25. <https://doi.org/10.1007/s00256-013-1738-9>
 14. Salemi, F, Shokri A, Maleki FH, et al. Effect of Field of View on Detection of Condyle Bone Defects Using Cone Beam Computed Tomography. *J Craniofac Surg* 2016; 27: 644-648. <https://doi.org/10.1097/SCS.0000000000002592>
 15. Shahidi S, Salehi P, Abedi P, et al. Comparison of the Bony Changes of TMJ in Patients with and Without TMD Complaints Using CBCT. *J Dent (Shiraz)* 2018; 19: 142-149.
 16. Shahab S, Azizi Z, Taghavi Damghani F, et al. Prevalence of osseous changes of the temporomandibular joint in CBCT images of patients with and without temporomandibular disorders. *Biosci. Biotechnol. Res. Commun.* 2017; 10: 518-24. <https://doi.org/10.21786/bbrc/10.3/27>
 17. Hafez Maleki F, Shokri A, Hosseini Zarch H, et al. Cone Beam CT Evaluation of the Bony Changes in the Temporomandibular Joint and the Association with the Clinical Symptoms of Temporomandibular Joint Disorders. *JDMT* 2019; 8: 25-32.
 18. de Holanda TA, de Almeida RC, Silva AE, et al. Prevalence of Abnormal Morphology of the Temporomandibular Joint in Asymptomatic Subjects: A Retrospective Cohort Study Utilizing Cone Beam Computed Tomography. *Int J Prosthodont* 2018; 31: 321-326. <https://doi.org/10.11607/ijp.5623>
 19. Sa SC, Melo SL, Melo DP, et al. Relationship between articular eminence inclination and alterations of the mandibular condyle: a CBCT study. *Braz Oral Res* 2017; 30: 25-31. <https://doi.org/10.1590/1807-3107bor-2017.vol31.0025>
 20. Koç N. Evaluation of osteoarthritic changes in the temporomandibular joint and their correlations with age: A retrospective CBCT study. *Dent Med Probl* 2020; 57:67-72. <https://doi.org/10.17219/dmp/112392>
 21. Bae S, Park MS, Han JW, et al. Correlation between pain and degenerative bony changes on cone-beam computed tomography images of temporomandibular joints. *Maxillofac Plast Reconstr Surg* 2017; 39: 19. <https://doi.org/10.1186/s40902-017-0117-1>
 22. Alexiou K, Stamatakis H, Tsiklakis K. Evaluation of the severity of temporomandibular joint osteoarthritic changes related to age using cone beam computed tomography. *Dentomaxillofac Radiol* 2009; 38: 141-147. <https://doi.org/10.1259/dmfr/59263880>