

Mandibular Dimensional Changes with aging in Three Dimensional Computed Tomographic Study in 21 to 50 Year old Men and Women

Original Article

Roshanak Ghaffari¹, Abolfath Hosseinzade², Hossein Zarabi³, Marzieh Kazemi⁴

^{1,2} Assistant Professor, Department of Maxillofacial Radiology, Islamic Azad University, Khorasgan Dental Branch, Dental faculty, Isfahan, Iran

³ Radiologist, Isfahan, Iran

⁴ Dentist, Isfahan, Iran

Received: Jan 29, 2013

Accepted: Mar 5, 2013

Corresponding Author:

Roshanak Ghaffari, DDS

Address: Department of Maxillofacial Radiology, Islamic Azad University, Khorasgan Dental Branch, Dental faculty, Isfahan, Iran

Telephone: +03115354053

Fax: +98311534053

E-mail: Roshanakghaffari@yahoo.com.

Abstract

Introduction: Raising the knowledge of skeletal and soft tissue changes with aging has been highly essential due to an increasing demand for aesthetic facial surgery following aging. The aim of this study is to evaluate the three dimensional computed tomographic images and process of changes in mandible with aging.

Materials and Methods: In this descriptive study, the facial CT scans were obtained from 124 subjects (70 men and 54 women). The population of the study was categorized in three ages (21 to 30, 31 to 40, 41 to 50). Each CT image was reinforced under volume rendering three-dimensional reconstruction by using the three dimensional analysis software volume viewer. The specific parts of mandible consisting of bigonial width, mandibular body height, ramus breadth, ramus height, mandibular body length and mandibular angle were measured and the data were analyzed employing two-ways analysis of variance.

Results: In both genders, there was no significant changes in bigonial width with aging ($P=0.88$). Mandibular body height for both genders decreased with aging but the result was not statistically significant ($P=0.19$). Ramus breadth decreased with aging in both genders ($P=0.02$). Considering the obtained means, ramus height and mandibular body length did not show significant changes in different age categories ($P=0.09$) ($P=0.54$). In both genders mandibular angle increased with aging ($P=0.17$).

Conclusion: Mandibular angle in women is greater than men and also for ramus breadth. There is no significant difference between men and women.

Key words: •Aging • Imaging •Mandible •Three-Dimensional

Introduction

Skeletal bone is scaffold for the soft tissue.⁽¹⁾ Facial aging is a dynamic process involving the aging of soft-tissue and bony structures. Atrophy in skin, with the loss of tone and elasticity and distribution of facial fat coupled with gravity and muscle activity lead to wrinkling and folds.^(2,3) Aging of the lower face often includes ptosis of the soft tissues of the chin and banding or cording of the muscles of the anterior neck.⁽⁴⁾ The age related changes of bony morphology are not well defined.⁽¹⁾ Previous researches focused on changes in soft tissue and skin with aging but changes in bones and facial skeleton significantly affected the aging face (Figure 1).⁽²⁾

Any kind of changes in the mandibular projection, width, or height can affect the overall aesthetics.⁽³⁾ Reshaping of the face with ageing is the result of volume changes and loss of support.⁽⁵⁾

The ability of CT imaging to display fine bone details, makes it an ideal modality for lesions that involve bone. The three-dimensional CT has been applied to trauma and craniofacial reconstructive surgery, and has been used for both treatment of congenital and acquired deformities.⁽⁶⁾

The availability of the data in a three dimensional format has also allowed the construction of life-sized models that can be used for trial surgeries and the construction of surgical stents.⁽⁶⁾

Early literature analyzing facial bone aging, focused on the orbit and mid face. It was believed that the bony face continued to grow with age, particularly with the increase in facial width and depth. In contrast, many recent studies suggest that the bone aging of the orbit and mid face is a process primarily of contraction and morphologic changes.^(2,3,7)

Kahn et al., in study on 3D CT images of orbit, showed that the orbital aperture width and orbital aperture area in both genders have significantly increased with aging.⁽⁷⁾

Richard et al. showed that the glabellar, orbital, maxillary and pyriform angles all decreased with age.⁽³⁾

In a study which was carried out by Shaw et al. on 3D CT images, it was revealed that

there were no significant changes in bigonial width and ramus breadth across ages in both genders. Ramus height, mandibular body height and mandibular body length decreased with age for both genders and mandibular angle increased in both genders across ages.⁽²⁾

Raising the knowledge of skeletal and soft tissue changes with aging has been highly essential due to an increasing demand for aesthetic facial surgery following aging. The aim of this study is to evaluate of the 3-dimensional computed tomographic images and process of changes in mandible with aging in men and women with 21 to 50 years of age.

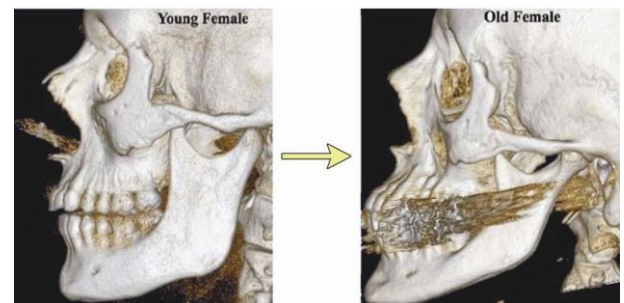


Figure 1. Changes of the mandibular bone in young & old females

Materials and Methods

In this descriptive study, facial 3-DCT images of 124 patients (70 men and 54 women) from 2011 to 2012 were investigated.

The images were produced by spiral CT machine (General Electric Company, New York, USA).

All measurements were obtained using a General Electric Advantage Windows Workstation with version 4.3 software. Each CT was reinforced under volume rendering 3-dimensional reconstruction using 3-dimensional analysis software volume viewer.

The specific parts of mandible on subjects which were measured (Figure 2):

1. Bigonial width (distance between right and left gonion)
2. Mandibular body height (distance between infradentale to gnathion)
3. Ramus breadth (minimum breadth of mandibular Ramus)
4. Ramus height (Mandibular condyle to gonion)

5. Mandibular body length (anterior margin of chin to gonion)

6. Mandibular angle (the angle formed by the mandibular body and ramus)

The above measurements were all taken from the right side of the mandible for each subject, assuming no significant difference between mandible sizes in the same subject.

All measurements were obtained using General Electric Advantage Windows Workstation with version 4.3 software (Figure 3). The data were analyzed by spss10. Two way analysis of variance was carried out to analyze the data.

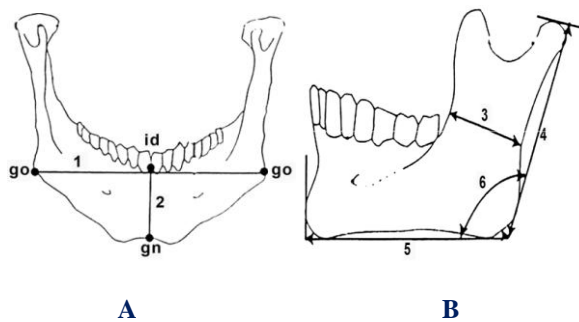


Figure 2. Mandible in sagittal (A) & coronal plan(B)

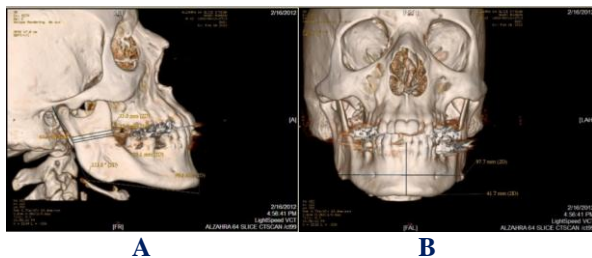


Figure 3. Measurements on 3D CT images for man with 42 years old in Alzahra hospital (A,B)

Results

In this study, 124 3D CT images (70 men, 54 women) were evaluated.

In our male and female study populations, the bigonial width did not change significantly with increasing age (P value=0.88) (Table 1). The mean measurements for female subjects were smaller than male subjects in all 3 age groups (P value= 0.001).

The mandibular body height decreased with increasing age for both male and female subjects but the result was not statistically

different (P value<0.192). The mean measurement for men subjects was greater than female subjects in 3 age groups (P value<0.001)(Table 1).

The two ways analysis of variance revealed that there was not a statistical difference between the mean of ramus breadth with sex (P value= 0.145). In our population the mean of ramus breadth decreased with the increasing age for both genders (P value <0.02) (Table 1).

The mean of ramus height and mandibular body length in our population decreased with increasing age but the result was not statistically different (P value=0.09) (P value= 0.54). The mean measurements in our female subjects is smaller than men subjects (P value= 0.001) (P value =0.001) (Table 1).

The mandibular angle increased significantly with increasing age. The mean of mandibular angle for female subjects was significantly larger than male subjects in three age groups.

Discussion

Soft tissue augmentation was added to the treatment plan for facial rejuvenation. At the other hand, bony components of the face are important because they provide the framework for soft tissue drapes, and any change in this bony component can affect the soft tissues.⁽²⁾

We used the three dimensional CT images, since these images allow for more accuracy in the obtained measurements compared with the previous studies.

In our population, the mean of bigonial width did not change significantly with increasing age. In a similar study by Shaw et al. on 3D CT images, also the mean of bigonial width did not change significantly with increasing age.

In this study, the result of groups 21 to 30 and 31 to 41 was compared with that of 20 to 40 of Shaw et al. research⁽²⁾ and the group 41 to 50 of our study was compared with that of Shaw et al.⁽²⁾ which included 41 to 64 years old. We had limitation of taking the samples with ≥ 60 years old that led to taking samples up to 50 years old.

Results of this research and Shaw et al.⁽²⁾ were different from that of Pessa et al. Pessa et al. evaluated the frontal radiographs and reported that there was an increase in mandible width and height with increasing age. The shape in both male and female subjects was statistically different from that of the individuals with the same age. The shape changed because some areas continued to grow faster than other areas. The mean age for youth was 16.2 for both genders, In other words, this samples were in maturity period.⁽⁸⁾

In each three studies; (Present study, Pessa et al.⁽⁸⁾ and Shaw et al.) the mean of bigonial width in men was greater than in

women.

According to our results, the mean of mandibular angle in both genders increased with age and the total mean of mandibular angle was 125.62 for men and 120.67 for women which was which was in agreement with that of Shaw.

In Shaw et al.,⁽²⁾ the same increase was observed in female subjects aging. In another study run by Pecora et al., it was found that women had a downward and backward rotation in mandible but men had a forward rotation in mandible. Hence, the increase in mandibular angle in females is more than in men.⁽⁹⁾

Table1. The mandibular measurements(mean±SD) for male & female in all three age categories

Location	Sex	Age Category (year)		
		21-30	31-40	41-50
Bigonial width(mm)	Male	107.9±8.6	106.9±8.5	106.7±4.9
Bigonial width(mm)	Female	96.1±7.5	96.4±5.4	95.7±5
Mandibular body height(mm)	Male	39.6± 4.2	38±3	37.7±4.2
Mandibular body height(mm)	Female	33.3±3.6	33.2±4	37.7±3.4
Ramus breadth (mm)	Male	33.7±4.3	32.3±3.	31.2±2.5
Ramus breadth (mm)	Female	32.5±2.6	31.4±3.7	30.3±3.7
Ramus height(mm)	Male	73.3±10	71.3±6	70.1±7.1
Ramus height(mm)	Female	64.1±4.9	61±7.8	60.7±6.5
Mandibular body length(mm)	Male	95.1±13	96.3±8.2	93.5±8.5
Mandibular body length(mm)	Female	85.6±9.2	83.3±11.1	82.3±5.9
Mandibular angle(degrees)	Male	119±7.1	121.5±6.3	123±6.4
Mandibular angle(degrees)	Female	124.3±5.2	125.2±3.7	128.2±5.2

The increase in mandibular angle may result in blunting or loss of definition of the lower border of the face. A blunted mandibular angle creates a softer oval appearance of the lower face, as there is a loss of jawline definition.⁽²⁾

The results show that the mean of mandibular body length in men is greater than in women. In this study, there is a decrease in mandibular body length with increasing age, but the result was not statistically different. Shaw found that the mean of mandibular body length in women was 86.9 mm for young age group and 80.9 for middle age group and in men 90.4 mm

for young age group and 83.1 for middle age group. He concluded that mandibular body length show a significant decrease with increasing age for both male and female, and these bony changes may result in the appearance of decreased chin projection.⁽²⁾

The results of Pecora et al. show forward rotation of mandible and increase in chin projection in men population.⁽⁹⁾ Pecora et al. concluded that the length of mandible in both genders increased with increasing age and the skeletal changes from late adolescence to mid adulthood is significant.⁽⁹⁾

In the present study, mandibular body

height for male and female subjects decreased with increasing age but this decrease was not statistically different. Mandibular body height in men was greater than in women. This parameter in Shaw et al. study decreased with increasing age (from 35.4 mm to 32.9 mm for men and from 31.5 mm to 30.6 mm for women). Male population had a statistically decrease from young to middle age group but female population had a statistically decrease from middle to old age group.⁽²⁾

Decrease in bone and alveolar ridge with increasing age can a reason for this result. Our male population had a greater ramus height rather than female population but with increasing age a little decreased occurred in ramus height. Shaw et al didn't not report significant decrease in ramus height from young to middle age group.⁽²⁾

Our results show that the mean of ramus breadth did not show a significant difference in men and females. For both genders, ramus breadth decreased with increasing age but these results were different from the study by Shaw et al.

Shaw et al found that the mean measurement for female subjects was significantly smaller than for male subjects only in the young age group.⁽²⁾

Mandibular volume loss also affected the aging of neck, as it may contribute to the increased laxity of the platysmal and soft tissue of the neck.⁽²⁾ Cadaver study by Reece et al. reported the presence of mandibular

septum. That is adherent to the mandibular body, which separates the jowl from the submandibular fat. This septum will recede with the mandible as it ages and thus allows the soft tissue to roll over the border of the mandible.⁽¹⁰⁾

The primary goal of facial aesthetic surgery is to restore and rejuvenate the aging face to a more youthful appearance, achieving balance and harmony.⁽¹¹⁾ Any change in mandibular projection, width, or height can affect the overall aesthetics. Patients with a normal mandibular ramus height and length of the mandibular body have an excellent support for soft tissue repositioning, but in contrast those with a short ramus, obtuse mandibular angle, and decreased mandibular projection have a poor skeletal support for mid-face and lower face soft tissue repositioning. These patients often benefit from volumetric augmentation to enhance their skeletal support.⁽²⁾

Conclusion

Mandibular angle in women is greater than in men and for ramus breadth there is no significant difference between men and women. Other measurements for male subjects were greater than female ones. Better understanding of the changes in facial aging can be an effective approach to facial rejuvenation, to compensate for the loss of bony volume and masking the change with age.

References

1. Richard MJ, MorrisC, Deen BF, Gray L, Woodward JA. Analysis of the Anatomic Changes of the aging facial Skeleton Using Computer-assisted Tomography. *Ophthal Plast Reconstr Surg* 2009; 25(5): 382-3862.
2. Shaw RB Jr, Katzel EB, Koltz PF, Kahn DM, Giroto JA, Langstein HN. Aging of the Mandible and its Aesthetic Implications. *Plast Reconstr Surg*. 2010; 125(1): 332-342.
3. Shaw RB Jr, Katzel EB, Koltz PF, et al. Aging of the facial Skeleton: Aesthetic Implications and Rejuvenation Strategies. *Plast Reconstr Surg* 2011; 127(1):374-83.
4. Sykes JM. Rejuvenation of the aging neck. *FacialPlast Surg* 2001; 17(2):99-107.

5. Levine RA, Garza JR, Wang PT, et al. Adult facial growth: applications to aesthetic surgery. *AestheticPlast Surg* 2003 ;27(4):265-268.
6. White Sc, Pharoah MJ. *Oral Radiology Principles and interpretation*. 6th ed. St. louis: Mosby Elsevier; 2009. pp. 209-211.
7. Kahn DM, Shaw RB Jr. Aging of the bony orbit: A three dimensional Computed Tomographic Study. *Aesthetic Surg J* 2008; 28(3) 258-264.
8. Pessa JE, Slice DE, Hanz KR,et al. Aging and the Shape of the Mandible. *PlastReconstr Surg*. 2008; 121(1): 196-200.
9. Pecora NG, Baccetti T, Mcnamara JA. The aging Craniofacial Complex: A Longitudinal Cephalometric Study from late adolescence to late adulthood. *Am J orthod Dentofacial Orthop* 2008; 134(4): 496-505.
10. Reece EM, Pessa JE, Rohrich RJ. The mandibular septum: anatomical observations of the jowls in aging-implications for facial rejuvenation. *Plast Reconstr Surg* 2008; 121(4):1414-1420.
11. Choe KS, Stucki- McCormicksu. Chin augmentation. *Facial Plast Surg* 2000; 16(1):4554.