

The Relationship between Dental Maturity based on Demirjian's Method and Cervical Vertebrae Maturation Stages in Gilan patients

Somayeh Nemati¹, Fateme Azimi², Mahsa Rouhi³, Zahra Tafakhori⁴

ARTICLE INFO

Article type:

Original Article

Article history:

Received: Oct 30, 2016

Accepted: Mar 15, 2017

Available online:

¹ Assistant Professor, Department of Oral and Maxillofacial Radiology, Faculty of Dentistry, Gilan University of Medical Sciences, Rasht, Iran.

² Assistant Professor, Department of Oral and Maxillofacial Radiology, Faculty of Dentistry, Arak University of Medical Sciences, Arak, Iran.

³ Dentist, faculty of dentistry, Gilan University of Medical Sciences, Rasht, Iran.

⁴ Assistant Professor, Department of Oral and Maxillofacial Radiology, Faculty of Dentistry, Rafsanjan University of Medical Sciences, Rafsanjan, Iran.

Corresponding Author:

Fateme Azimi

Address:

Department of Oral and Maxillofacial Radiology, Arak University of Medical Sciences, Arak, Iran.

E-mail: f.azimi@arakmu.ac.ir

Telephone: +9886-32219541

Fax: +9886-32724524

Abstract

Introduction:

Dental maturation is a useful indicator of growth. Moreover, skeletal maturation is assessed by the cervical vertebrae maturation (CVM) stages, using lateral cephalometric radiographs. This study aimed to investigate the association between Demirjian's method and CVM stages and also to analyze the diagnostic performance of the dental maturation stages for identification of growth phases in Gilani subjects.

Materials and methods:

Digital panoramic and lateral cephalometric radiographs of 200 healthy subjects (73 boys and 127 girls, ranging from 6 to 18 years of age) were examined. Dental maturity was assessed by Demirjian's method, whereas skeletal maturity was estimated by the CVM stages. Diagnostic performances were evaluated based on the identification of the growth phases using positive likelihood ratios (LHR+). The Spearman rank-order correlation coefficient was used to measure the association between the CVM stages and dental calcification stages.

Results:

Correlation between the dental developmental stages and CVM stages was statistically significant (moderate for males, $r = 0.515$ and high for females, $r = 0.889$). Three teeth revealed positive LHRs greater than 10 only for identification of the prepubertal growth phase, with value from 36.46 for second molar (stage E) and 19.75 for canine and first premolar (stage F in both).

Conclusion:

Despite the moderate to high correlation between the dental and skeletal maturity in Gilani subjects, diagnostic performances of the dental maturity for the identification of pubertal growth spurt would be limited. Thus, the second molar (stage E) has the highest diagnostic performance only in the identification of prepubertal phase.

Key words:

•Tooth •Radiograph, Panoramic •Cervical Vertebrae

Copyright: [2017] Journal of Dentomaxillofacial Radiology, Pathology, and Surgery.

> **Please cite this paper as:**

Nemati S, Azimi F, Rouhi M. *The Relationship between Dental Maturity based on from Demirjian's Method and Cervical Vertebrae Maturation Stages in Gilani patients.* 3DJ 2017;6(2):1-9.

Introduction

Chronological age is not adequate to determine the stage of development and somatic

maturity; hence, biological age should be considered. Biological age is determined by

the morphological, skeletal, and dental age and by onset of puberty.⁽¹⁾ Dental development is a useful indicator of growth, because the teeth are less affected by the endocrine diseases and environmental damage in comparison to the other tissues of the body.⁽¹⁾

Tooth development may be assessed by tooth formation or tooth eruption. Tooth eruption is a variable and discontinuous parameter that may be influenced by malnutrition, early loss of deciduous teeth, and dental caries and crowding. Tooth formation is a better parameter due to high reliability, less variety, and resistance to environmental effects.⁽²⁻⁵⁾ Furthermore, dental maturity is a valuable parameter and may be used in orthodontics.⁽⁶⁾ One of the widely known methods to measure the dental age is Demirjian's method that was initially described in 1973, based on a study on large population of French– Canadian children.⁽⁷⁻¹⁰⁾

Demirjian's method is studied in different populations. Determination of maturity based on the Demirjian's method presents differences between countries and also between geographic regions or cities within a country.⁽¹¹⁾

Skeletal maturity is determined by the biological parameters such as height, weight, chronological age, dental development, and development of the cervical spine, wrist, and finger bones; however, the fingers and wrist radiographs are considered as the best and most reliable biological markers.

Since the formation of the hand bones differs considerably between individuals, determining the skeletal age by the hand radiographs alone may not be accurate.

In this method, patients received radiation for the wrist radiographs in addition to the radiation of the usual method, like panoramic and lateral cephalometric radiographs, that routinely check for early orthodontic assessments.

In several studies, the developmental stages of the second to the sixth cervical vertebrae are classified in six stages based on the size and shape of the vertebrae. Therefore, skeletal development is assessed by the development of cervical vertebrae (CVM) using lateral cephalometric radiographs.⁽¹²⁻¹³⁾ Assessment of teeth development is a diagnostic tool for detecting the skeletal development.⁽¹⁴⁻¹⁶⁾

It is a simple process and can be evaluated by the

panoramic views or intraoral radiographs that are prescribed for various purposes with least patient dose.⁽¹⁶⁾

Mappes et al. reported that geographical conditions, nutrition, and socioeconomic factors influence the racial differences.⁽¹⁶⁾ Presumably, the relationship between the dental and skeletal puberties differs between various geographical areas and races.⁽¹⁷⁻¹⁹⁾

Due to insufficient study in the Guilan population and controversies about the clinical performance of dental maturation to identify the skeletal maturation stages, this study was designed to investigate the diagnostic performance of the circumpubertal phases of dental maturation in order to identify the skeletal maturation phases separately.

Materials and Methods

This retrospective analytical cross-sectional study included a total of 200 Guilani subjects (73 males and 127 females, age range of 6–18 years) with mean age of 13.1 ± 2.76 years, seeking orthodontic treatment for first time, in a private orthodontic clinic and in the Dental School of Guilan University of Medical Sciences. This study was registered with the code of ethics of IR.GUMS.REC.1394.445. Informed consent was obtained from all the patients.

The exclusion criteria of the subjects were the presence of systemic diseases affecting the dental development (such as hypophosphatemia, hypophosphatasia,...), hormonal, nutritional, and growth disturbances affecting the dental development, missing or impaction of mandibular permanent teeth, except for the third molar, and having positive history of extraction of mandibular permanent teeth. After selecting the patients, high quality digital panoramic and lateral cephalometric radiographs of the subjects were examined, and their chronological age, based on their date of birth and date of radiography, was calculated by subtracting the value obtained and shown to a decimal number (year and month) and lateral radiographs and panoramic coded with an identifier code. Age and gender was unknown for the examiner. Panoramic radiographies interpreted by an oral and maxillofacial radiologist and lateral radiographs were reviewed and evaluated by an orthodontist.

Dental maturity was assessed by calcification stages of the mandibular first and second incisors, canines, first and second premolars, and first and second molars whereas, skeletal maturity was estimated by the cervical vertebrae maturation stages. During evaluation of the stages, Demirjian's method was used to calcify the mandibular teeth and dental maturity (Figure 1). Demirjian has classified the dental development stages in eight steps (A to H), and the calcification stages of teeth were determined according to this method. In absence of any indicated left teeth the right mandibular teeth was replaced. In the absence of both, the sample was removed. The maturity stages of the cervical spine were determined using Baccetti method.⁽²⁰⁾ (Table 1 and Figure 2). The developmental stages of the cervical spine were assessed for the cervical ver-

tebrae C2, C3, C4, and the presence or absence of concavity on the border of the lower vertebrae in the 6th-stage (CS1–CS6). The evolutionary stage of the cervical spine was recorded for each patient.

Furthermore, in this study, the growth phases were divided into:

(CVMS 1–CVMS 2): (prepubertal)

(CVMS 3–CVMS 4): (pubertal)

(CVMS 5–CVMS 6): (postpubertal)

Diagnostic performances were evaluated based on the identification of the growth phases using positive likelihood ratios (LHR+). The Spearman rank-order correlation coefficient was used to measure the association between the CVM stages and dental calcification stages of the individual teeth. P value < 0.05 was considered as statically significant.

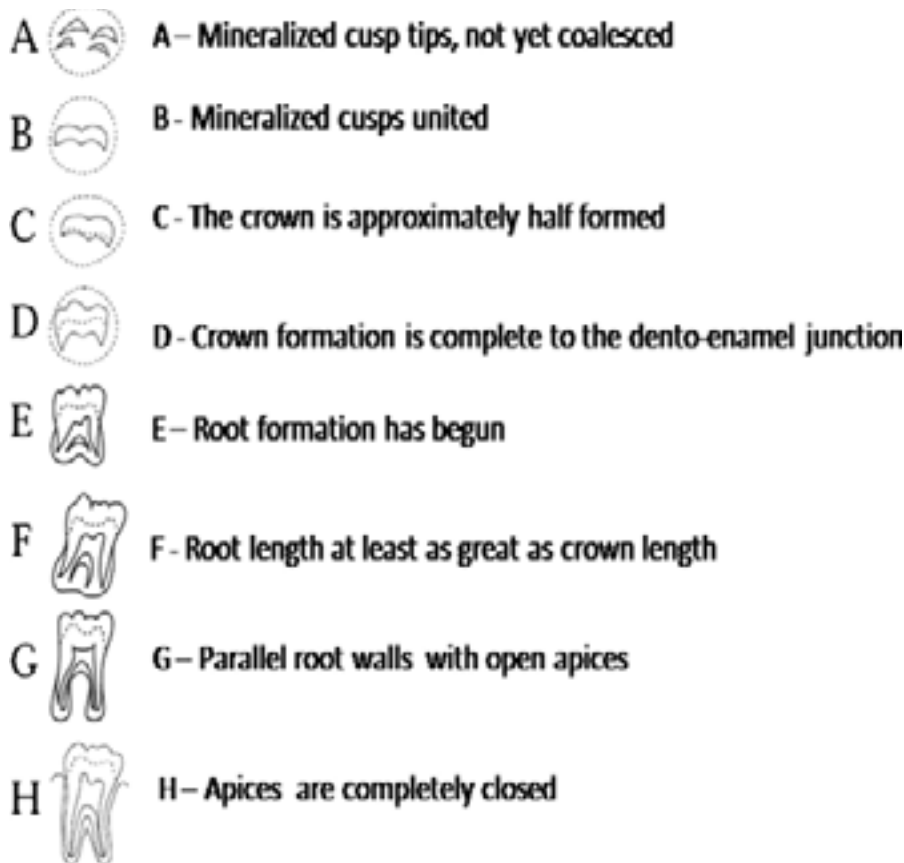


Figure 1. Dental maturation phases according to Demirjian's method

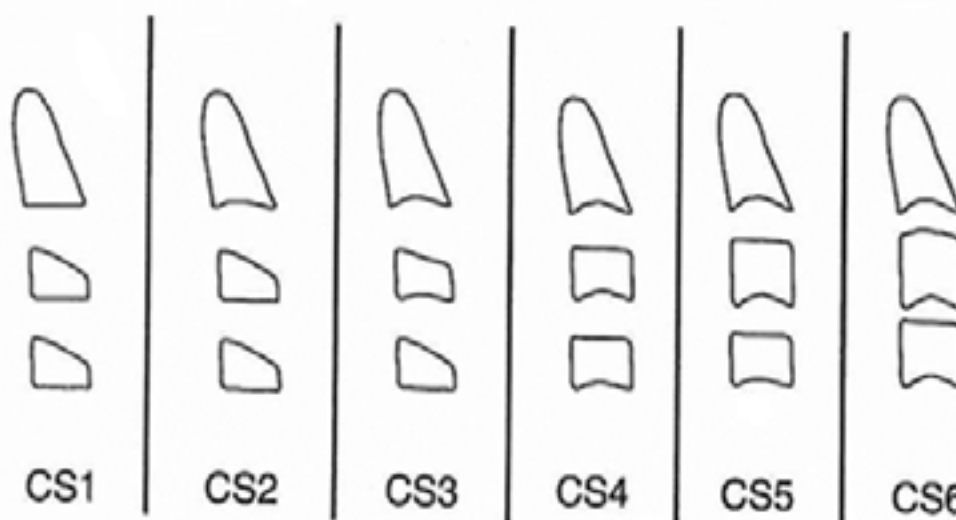


Figure 2. Cervical vertebrae maturation phases according to Baccetti's method

Table 1. Cervical vertebrae maturation stages, based on Baccetti's method

CVM stage
<p>Cervical stage 1: The lower borders of all the three vertebrae (C2–C4) are flat. The bodies of both C3 and C4 are trapezoid in shape (the superior border of the vertebral body is tapered from posterior to anterior). The peak in the mandibular growth will occur approximately 2 years after this stage.</p>
<p>Cervical stage 2: A concavity is present at the lower border of C2 (in four of five cases, with the remaining subjects still revealing cervical stage 1). The bodies of both C3 and C4 are still trapezoid in shape. The peak in the mandibular growth will occur approximately 1 year after this stage.</p>
<p>Cervical stage 3: Concavities at the lower borders of both C2 and C3 are present. The bodies of C3 and C4 may be either trapezoid or rectangular horizontal in shape. The peak in the mandibular growth will occur during the following year after this stage.</p>
<p>Cervical stage 4: Concavities at the lower borders of C2, C3, and C4 now are present. The bodies of both C3 and C4 are rectangular horizontal in shape. The peak in the mandibular growth has occurred within 1 or 2 years before this stage.</p>
<p>Cervical stage 5: The concavities at the lower borders of C2, C3, and C4 still are present. At least one of the bodies of C3 and C4 is squared in shape. If not squared, the body of the other cervical vertebrae still is rectangular horizontal. The peak in the mandibular growth has ended at least 1 year before this stage.</p>
<p>Cervical stage 6: The concavities at the lower borders of C2, C3, and C4 still are evident. At least one of the bodies of C3 and C4 is rectangular vertical in shape. If not rectangular vertical, the body of the other cervical vertebra is squared. The peak in the mandibular growth has ended at least 2 years before this stage.</p>

Results

Samples included 36.5% (n = 73) males and 63.5% (127) females. In terms of age, the mean age was 13.1 ± 2.76 years, and the youngest subject aged 7 years and the oldest was 18 years of age. In relation to dental maturity, girls were 3.27 months ahead of boys and girls in skeletal puberty were 10.4 months ahead of boys. In both cases the difference was not significant. Dental maturity in boys was 75.86 months ahead of maturity occurs in skeletal maturity and dental maturation in girls was 68.73 months ahead of skeletal maturity. Herein, the differences were statistically significant.

Table 2 presents the highest and lowest associations found between dental maturity and skeletal maturity, according to gender.

Detailed results of the association between the cervical maturation and dental maturation, according to the pubertal phase, are summarized in Table 3.

Table 4 presents the sensitivity, specificity, positive predictive value (PPV), and negative predictive value (NPV) in teeth with positive LHR greater than 10 in the prepubertal phase.

Table 2. The highest and lowest association found between dental maturity and skeletal maturity according to gender

		Boys		Girls	
CS1	Highest	H stage of the central incisor		H stage of central incisor	
	Lowest	G stage of central and lateral incisors		H stage of the first premolar	
CS2	Highest	H stage of central and lateral incisors		H stage of central and lateral incisors	
	Lowest	H stage of second premolar and E stage of second molar		G stage of the central and lateral incisors	
CS3	Highest	H stage of central and lateral incisors and first molar		H stage of central and lateral incisors	
	Lowest	H stage of second premolar and E and F stages of second molar		F stage of canine and first premolar	
CS4	Highest	H stage of central and lateral incisors and first molar		H stage of central and lateral incisors and first molars	
	Lowest	G stage of first premolar and F stage of second molar		F stage of second molars	
CS5	Highest	stage H of central and lateral incisors, first molar, canine and first premolar		stage H of central and lateral incisors and the first molar	
	Lowest	stage G of the second premolars		G stage of canine and first premolar and F stage of the second molar	
CS6	Highest	H stage of all teeth except than the central and canines		H stage of all teeth	
	Lowest	G stage of canine		G stage of canine	

Table 3. Percentage distribution of dental maturation stages obtained from the 3-phases growth by Demirjian following the maturity of the cervical spine

		Tooth number													
		31.00		32.00		33.00		34.00		35.00		36.00		37.00	
		Gender		Gender		Gender		Gender		Gender		Gender		Gender	
		Girls	Boys	Girls	Boys	Girls	Boys	Girls	Boys	Girls	Boys	Girls	Boys	Girls	Boys
		%	%	%	%	%	%	%	%	%	%	%	%	%	%
Prepubertal	D	0.0	0.0	0.0	0.0	0.0	0.0	0.0	0.0	0.0	0.0	0.0	0.0	11.1	8.0
	E	0.0	0.0	0.0	0.0	0.0	0.0	16.7	8.0	25.0	12.0	0.0	0.0	33.3	16.0
	F	0.0	0.0	0.0	0.0	44.4	40.0	47.2	36.0	50.0	44.0	2.8	0.0	41.7	24.0
	G	2.8	4.0	13.9	4.0	38.9	44.0	22.2	32.0	25.0	36.0	25.0	4.0	11.1	52.0
	H	97.2	96.0	86.1	96.0	16.7	16.0	13.9	24.0	0.0	8.0	72.2	96.0	2.8	0.0
	Total	100.0	100.0	100.0	100.0	100.0	100.0	100.0	100.0	100.0	100.0	100.0	100.0	100.0	100.0
Pubertal	D	0.0	0.0	0.0	0.0	0.0	0.0	0.0	0.0	0.0	0.0	0.0	0.0	0.0	0.0
	E	0.0	0.0	0.0	0.0	0.0	0.0	0.0	0.0	0.0	0.0	0.0	0.0	0.0	3.6
	F	0.0	0.0	0.0	0.0	3.7	7.1	3.7	7.1	25.9	25.0	0.0	0.0	22.2	7.1
	G	0.0	0.0	0.0	0.0	22.2	46.4	33.3	25.0	48.1	50.0	0.0	0.0	59.3	67.9
	H	100.0	100.0	100.0	100.0	74.1	46.4	63.0	67.9	25.9	25.0	100.0	100.0	18.5	21.4
	Total	100.0	100.0	100.0	100.0	100.0	100.0	100.0	100.0	100.0	100.0	100.0	100.0	100.0	100.0
Postpubertal	D	0.0	0.0	0.0	0.0	0.0	0.0	0.0	0.0	0.0	0.0	0.0	0.0	0.0	0.0
	E	0.0	0.0	0.0	0.0	0.0	0.0	0.0	0.0	0.0	0.0	0.0	0.0	0.0	0.0
	F	0.0	0.0	0.0	0.0	0.0	0.0	0.0	0.0	0.0	0.0	0.0	0.0	1.6	0.0
	G	0.0	0.0	0.0	0.0	1.6	0.0	1.6	0.0	17.2	5.0	0.0	0.0	25.0	10.0
	H	100.0	100.0	76.2	100.0	98.4	100.0	98.4	100.0	82.8	95.0	100.0	100.0	73.4	90.0
	Total	100.0	100.0	76.2	100.0	100.0	100.0	100.0	100.0	100.0	100.0	100.0	100.0	100.0	100.0

Table 4. Sensitivity, specificity, PPV, and NPV in teeth with positive LHR greater than 10 in the prepubertal phase.

Teeth with LHR+ \geq 10	Sensitivity % (CI)	Specificity % (CI)	PPV % (CI)	NPV % (CI)
Canine (F stage)	42.62(30.05–55.94)	97.84(93.81–99.53)	89.66(72.62–97.69)	79.53(72.70–85.31)
First premolar (F stage)	42.62(30.05–55.94)	97.84(93.81–99.53)	89.66(72.62–97.69)	79.53(72.70–85.31)
Second molar (E stage)	26.23(15.80–39.07)	99.28(96.04–99.88)	94.12(71.24–99.02)	75.41(68.51–81.46)

Discussion

Relationship between the panoramic radiographs with lateral cephalometric radiograph findings is statistically significant in both genders and all the teeth except the central incisor.

This relationship was moderate in males but higher in females. The relationship order from highest to the lowest is described as follows: second premolar, second molar, first premolar, canine, first molar, lateral incisor, and central incisor.

In both genders, three cervical vertebrae maturation phases of growth (prepubertal, pubertal and postpubertal) were statistically significant in all the teeth except the central incisors.

A similar study was conducted by Basaran et al. in the Turkish population, which reported significant correlation between the development of teeth and skeletal maturation.⁽¹⁵⁾ In this study, among boys, the lowest correlation was related to the third molars and central incisors and the highest correlation was related to the second molars; whereas among girls, the lowest correlation was related to the third molars and canines and the highest correlation was related to the second molars.⁽¹⁵⁾

This finding is in accordance with the findings of the present study in most related teeth (second molars and second premolars). The minimum related teeth, that is, central incisors, in the present study did not reveal any significant correlation and the lowest correlation was related to the lateral incisors. In the study by Basaran et al., the lowest correlation was related to the third molars (which is not explained in the present study) and to the central incisors in boys and the third molars and canines in girls.

In a similar study by Chen et al. in the Chinese population, Spearman correlations between the stages of tooth development and maturation of cervical vertebrae significantly changed from 0.391 to 0.582 in girls and 0.464 to 0.496 in

boys.⁽²¹⁾

In the aforementioned study by Chen, in CS1 for both genders, the highest correlation was related to the premolars (girls 61.3%, boys 46%) and the second molar revealed the lowest correlation in both girls and boys. In the present study, the highest correlation in females was related to the central incisor (100%), and in males, it was related to the central and lateral incisors and first molar (all 100%). The lowest correlation in females was related to the first premolars (6.7%), and in males, it was related to the H phase of the central incisor, lateral incisor, first molar, and canine (all 10%), respectively.

In CS2, the highest correlation was related to the second molars, in females (57.1%) and males (61.1%). In the present study, the highest correlation were related to the central and lateral incisors on stage H (95.2%) in females and central incisor, lateral incisor, and first molar on stage H (100%) in males.

This study reports that the mean chronological age of females at every developmental stage of the cervical vertebrae was less than that of males. This finding indicates that puberty in females occurs earlier than in males and is compatible with the previous studies that found gender differences in the skeletal maturation.^(19, 22-23)

According to the present study, dental maturation and skeletal maturation occur 3.27 and 10.4 months earlier in females compared to males, respectively.

Dental maturation occurs 68.73 and 75.86 months earlier than skeletal maturation in females and males, respectively.

These findings are in accordance with the study by Rozylo et al., who reported that skeletal maturation occurs 6 months earlier in females compared to males.⁽²⁴⁾

This study revealed the chronological age orders from the highest to lowest relevance to cervical

vertebrae maturation (CVM), three growth phases of puberty (prepubertal, pubertal, and postpubertal), and dental maturity stages.

The study by Rozylo et al. in Poland reported the highest correlation in the second premolars and canines and the lowest correlation in the central incisors in both genders.⁽²⁴⁾

The results of the previous studies may differ due to the differences in the sample size, age range, racial differences, climate, nutrition, methods, and the inclusion and exclusion criteria.

Current study by Perinetti study⁽¹²⁾ used LHR+ to predict the cervical vertebrae maturation based on dental maturation; however, other previous studies have not used this important statistical index.

Accordingly, our study revealed that only a small number of dental maturation phases, had LHR 10+ or more to predict the prepubertal phases.

Based on the findings of this study, the second molar E (34.46), canines F (19.75), and first premolar F (19.75), had LHR+ greater than 10 and were suitable to predict the prepubertal phase (CS2 and CS1). Other stages of dental maturity revealed disperse distribution in the cervical vertebrae maturation stages.

In our study, the highest LHR+ was found in stage E of the second molar with sensitivity of 23.26%, specificity of 99.28%, PPV of 94.12%, and NPV of 75.41%. Based on these findings, E stage of the second molar tooth revealed the highest diagnostic value for predicting the prepubertal phase. Previous studies reported close association between the G and F stages of canine and skeletal maturity spurt indicators without using LHR+.^(15, 17-18, 22, 24)

Based on the findings of the present study, other dental maturity stages are not reliable for accurate prediction of the pubertal and postpubertal maturation phases of the cervical vertebrae.

According to a study by Perinetti⁽¹²⁾, most positive LHR teeth for prediction of phase included: F canine, E first premolar, E second premolar, E second molar, and D second molar in the prepubertal phase. Based on the five criteria of sensitivity, specificity, PPV, NPV, and LHR+, the E stage of the second premolar was found to be of the highest diagnostic value in determining the prepubertal growth phase; however, the other stages of dental development did not reveal any diagnostic value in predicting the pubertal

stages. These findings are in accordance with the present study.

Perinetti found that only the H stage of the second molar just below the value of 10 (9.1) was compatible with the postpubertal stage. This is in accordance with our study that revealed similar findings with LHR 7.48.

No other study, apart from the present study and the study by Perinetti, reported the higher correlation of the first premolar tooth with the cervical vertebrae maturation. Certain previous studies reported a strong correlation between the stages of canine development and skeletal maturity stages in both genders. F, G, and H stages represent the prepubertal, pubertal, and postpubertal phases of skeletal growth.⁽¹³⁾

In this study, the F stage of canine with LHR+ as 19.75 was introduced as an indicator for the prepubertal stage.

According to a study by Imani Moghaddams et al., correlation between the canine and skeletal maturation was the most significant finding (Correlation coefficient $r = 0.72$ for females and 0.59 for males). They revealed that the G stage of canine had a significant association with the skeletal growth spurt.⁽²⁵⁾

The present study used LHR for accurate prediction of correlation between the maturation stages of cervical vertebrae separately (prepubertal, pubertal, and postpubertal) and dental maturation. A threshold of a positive LHR of 10 or more was considered for assessment of satisfactory reliability of any dental maturation stage in identifying any of the CVM stages or growth phases. The study found that the E stage of the second molar has the most diagnostic value to indicate the prepubertal skeletal growth phase.

The differences in the results of the present study may be related to the differences in the sample size, racial differences, procedures, and criteria used to evaluate the skeletal and dental maturation processes.

Conclusion

There is a significant relationship between the calcification stages of teeth and the maturation stage of cervical vertebrae.

Teeth in the order of highest to the lowest correlation are: second premolar, second molar, first premolar, canine, first molar, and lateral incisor,

respectively.

Considering LHR+, the E stage of the second molar reveals the highest diagnostic value (LHR+ = 36/46) for predicting the prepubertal phase of growth. Furthermore, maturation stages of the mandibular teeth have a satisfactory diagnostic value for predicting the prepubertal phase of growth and are not reliable for predicting the pubertal growth spurt.

Skeletal and dental maturation of females occur 10.4 ± 6.9 and 3.27 ± 3.22 months earlier than males, respectively. In CS3, the average chronological age of females and males were 11.80 and 12.79 years, respectively, which indicates earlier puberty of females compared to males.

References

1. Saunders S, DeVito C, Herring A, Southern R, Hoppa R. Accuracy tests of tooth formation age estimations for human skeletal remains. *Am J Phys Anthropol.* 1993;92(2):173–88.
2. Demirjian A, Buschang PH, Tanguay R, Patterson DK. Interrelationships among measures of somatic, skeletal, dental, and sexual maturity. *Am J Orthod.* 1985;88(5):433–8.
3. Liversidge HM, Molleson T. Variation in crown and root formation and eruption of human deciduous teeth. *Am J Phys Anthropol.* 2004;123(2):172–80.
4. Moorrees CF, Kent RL, Jr. Interrelations in the timing of root formation and tooth emergence. *Proc Finn Dent Soc.* 1981;77(1-3):113–7.
5. Pelsmaekers B, Loos R, Carels C, Derom C, Vlietinck R. The genetic contribution to dental maturation. *J Dent Res.* 1997;76(7):1337–40.
6. Nykanen R, Espeland L, Kvaal SI, Krogstad O. Validity of the Demirjian method for dental age estimation when applied to Norwegian children. *Acta Odontol Scand.* 1998;56(4):238–44.
7. Demirjian A, Goldstein H, Tanner JM. A new system of dental age assessment. *Hum Biol.* 1973;45(2):211–27.
8. Frucht S, Schnegelsberg C, Schulte-Monting J, Rose E, Jonas I. Dental age in southwest Germany. A radiographic study. *J Orofac Orthop.* 2000;61(5):318–29.
9. Demirjian A, Goldstein H. New systems for dental maturity based on seven and four teeth. *Ann Hum Biol.* 1976;3(5):411–21.
10. Chen JW, Guo J, Zhou J, Liu RK, Chen TT, Zou SJ. Assessment of dental maturity of western Chinese children using Demirjian's method. *Forensic Sci Int.* 2010;197(1-3):119 e1–4.
11. San Roman P, Palma JC, Oteo MD, Nevado E. Skeletal maturation determined by cervical vertebrae development. *Eur J Orthod.* 2002;24(3):303–11.
12. Perinetti G, Contardo L, Gabrieli P, Baccetti T, Di Leonarda R. Diagnostic performance of dental maturity for identification of skeletal maturation phase. *Eur J Orthod.* 2012;34(4):487–92.
13. Coutinho S, Buschang PH, Miranda F. Relationships between mandibular canine calcification stages and skeletal maturity. *Am J Orthod Dentofacial Orthop.* 1993;104(3):262–8.
14. Sierra AM. Assessment of dental and skeletal maturity. A new approach. *Angle Orthod.* 1987;57(3):194–208.
15. Basaran G, Ozer T, Hamamci N. Cervical vertebral and dental maturity in Turkish subjects. *Am J Orthod Dentofacial Orthop.* 2007;131(4):447 e13–20.
16. Mappes MS, Harris EF, Behrens RG. An example of regional variation in the tempos of tooth mineralization and hand-wrist ossification. *Am J Orthod Dentofacial Orthop.* 1992;101(2):145–51.
17. Spencer RP. Pubertal height gain: male-female and interpopulation comparisons. *Med Hypotheses.* 2002;59(6):759–61.
18. Chaillet N, Nystrom M, Demirjian A. Comparison of dental maturity in children of different ethnic origins: international maturity curves for clinicians. *J Forensic Sci.* 2005;50(5):1164–74.
19. Demisch A, Wartmann P. Calcification of the mandibular third molar and its relation to skeletal and chronological age in children. *Child Dev.* 1956;27(4):459–73.
20. Baccetti T, Farnchi L, and James A. McNamara, Jr. The cervical vertebral maturation (CVM) method for the assessment of optimal treatment timing in dentofacial orthopedics. *Semin Orthod.* 2005; 11:119–29.
21. Jianwei chen, Haikun Hu, Jing Guo, Zeping Liu, RenkaiLiu, etc. Correlation between dental maturity and cervical vertebral maturity. *Oral Surg Med Oral Pathol Oral Radoil Endod.* 2010;110:777–83.
22. Al-Shehri MA, Mostafa OA, Al-Gelban K, Hamdi A, Albarkhi M, Altrabolsi H, et al. Standards of growth and obesity for Saudi children (aged 3 -18 years) living at high altitudes. *West Afr J Med.* 2006;25(1):42–51.
23. Prah Andersen B, Kowalski CJ. A mixed longitudinal, interdisciplinary study of the growth and development of Dutch children. *Growth.* 1973;37(3):281–95.

Acknowledgement

This study resulted from the final thesis of the undergraduate student of dentistry doctoral degree with registration number of 1386. We appreciate the valuable cooperation of Dr Jalil Khademi (famous orthodontist in Rasht) for conducting this research. Unfortunately, we lost him forever.

Conflict of Interest

The authors declare that they have no conflict of interest.

24. Rozylo-Kalinowska I, Kolasa--Raczka A, Kalinowski P. Relationship between dental age according to Demirjian and cervical vertebrae maturity in Polish children. *Eur J Orthod.* 2011;33(1):75–83.
25. Heravi F, Imanimoghaddam M, Rahimi H. Correlation between cervical vertebral and dental maturity in Iranian subjects. *J Calif Dent Assoc.* 2011;39(12):891–6.