

Histiocytic Necrotizing Lymphadenitis: A Case Report

Case Report

Laleh Maleki¹, Hoda Farmanara², Nooshin Afshar Moghaddam³, Iman Arfa⁴

¹Assistant Professor, Department of Oral and Maxillofacial Pathology, Yazd University of Medical Sciences, Yazd, Iran.

²Resident of Oral Medicine, Department of Oral Medicine, Yazd University of Medical Sciences, Yazd, Iran.

³Professor, Department of Oral and Maxillofacial Pathology, Yazd University of Medical Sciences, Yazd, Iran.

⁴Dentist, Ajman University of Science & Technology, United Arab Emirates.

Received: Aug 15, 2016

Accepted: Oct 7, 2016

Corresponding Author:

Hoda Farmanara

Address:

Department of Oral Medicine, School of Dentistry, Yazd University of Medical Sciences, Yazd, Iran.

Telephone: +989133260625

Email: hoda.farmanara@yahoo.com

Abstract

Introduction:

Kikuchi-Fujimoto disease or histiocytic necrotizing lymphadenitis is a rare, benign, self-limited condition characterized by constitutional symptoms, lymphadenopathy, and skin lesions and often affects young adult females. The etiology is unknown although viruses and auto-immune mechanisms has been suggested. Diagnosis is fundamentally based on the affected lymph node biopsy. The patient was a 34 years old female, referred without any history of fever, rash, loss of weight associated with right cervical submandibular lymphadenopathy and earache. Laboratory data were normal other than a little increase of ESR, CRP. Finally Cervical lymph node excisional biopsy was performed and Necrotizing Lymphadenitis was diagnosed. Then she was treated with steroids and lymph nodes were shorten within 1 month but recurred. Finally with possible diagnosis of Human Herpes Virus and after prescription of Acyclovir patient's lymphadenopathy absolutely resolved and it didn't recur within 6 months.

Key words:

• *Histiocytic Necrotizing Lymphadenitis*
• *Lymphadenopathy* • *Lymphatic Diseases.*

Case Report

The patient, 34 years old female, was referred to an internal specialist with chief complaints of toothache, earache, and the right submandibular lymphadenopathy, without any recent history of fever, chills, rash, and loss of weight. The patient was initially treated with azithromycin and cefixime. Subsequently, there was a slight reduction in the size of lymphadenopathy. Approximately after 3 weeks, the size of two submandibular and one supraclavicular lymph nodes enlarged. The patient referred to ENT specialist. Abnormal finding was not observed in ENT examinations. The patient referred to an infectious specialist, and cervical sonography and blood tests were performed in order to evaluate the infectious agents. She was treated with clindamycin, and it resulted in reduction of submandibular lymph nodes. Using sonography, a nodule in the left thyroidal lobe and benign-appearing adenopathy with diameters of 17.7×6.4 mm in the left submandibular region were observed. In addition, there were round and well-defined lesions with diameters of 10×9.7 mm and 8.4×4.9 mm in the right posterior auricular and behind the right parotid gland (Figure 1).

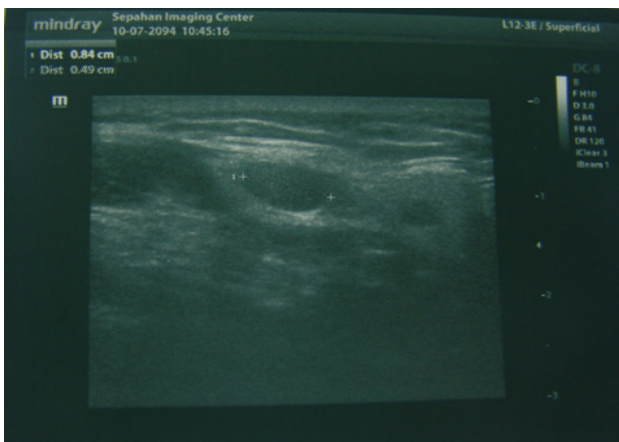


Figure 1. Sonography: Round and well-defined lesions in the right posterior auricular and behind the right parotid gland.

In laboratory tests, only ESR elevated and leukopenia existed, leukocytosis was not observed. LDH was in normal range, and Anti-ds-DNA (ANA) tests were negative. Wrights, Combs wright, Wright agglutination, 2ME, Toxoplasma Ab, and CMV Ab tests were also negative. Spleen, pelvis, and abdomen sonography was normal. Then, the patient was referred to an endocrinologist. FNA from left thyroid

nodule, and right submandibular and supraclavicular lymph nodes (particularly for ruling out of thyroid papillary carcinoma) were performed, and the results were reactive lymph node and benign follicular (nodular goiter), respectively. Because malignancy was still a strong possibility, an excisional biopsy of the right supraclavicular lymph node was performed. Microscopic evaluation showed focal necrotizing areas, abundant karyorrhectic debris, scattered fibrin deposits, and collections of large mononuclear cells. Plasma cells and neutrophils are very scant. A few follicular structures were observed. Diagnosis was necrotizing lymphadenitis (Figures 2).

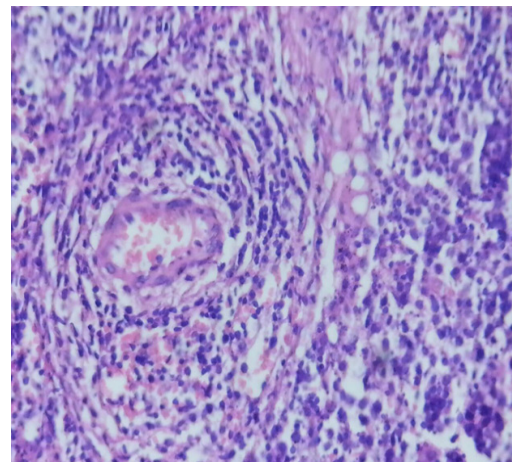


Figure 2. H&E staining, x40

Immunohistochemical tests were performed to rule out different kinds of lymphomas:

1-CD20: Focally positive in lymph node with focal immunoreactivity in adjacent fatty tissue (Figure 3)

2-BCL2: Focal lymphoid follicles were highlighted (Figure 4)

3-CD10, CD30, CD68, TdT: Negative (Figures 5 and 6)

4-CD3: Positive in interfollicular area

Then, the patient was treated with oral corticosteroid (Prednisolon). MRI was performed and the result involved no deep cervical lymph nodes and the possibility of lymphoma was ruled out. In MRI, several oval and round lesions were observed. The largest size of the lymph nodes observed in the right submandibular area was 16.3x27.4 mm. They decreased obviously within 1 month. After 1 month, small post auricular lymph nodes and burning and pain in oral mucosa developed from the retromolar area of the right side of the mandible to premolar teeth at the same side; earache also occurred without

any symptoms of infections. Therefore, based on aforementioned symptoms and treatments, possible diagnosis of human herpes virus was performed through administration of acyclovir. After treatment with acyclovir, the patient's lymphadenopathy completely disappeared. There was no disease symptom or recurrence within 6 months after diagnosis.

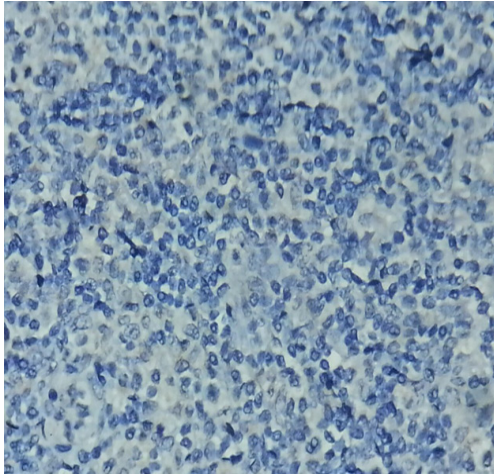


Figure 3. Immunohistochemical staining used CD20, x40

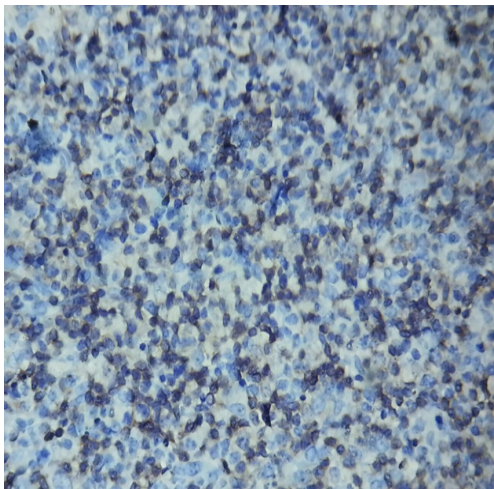


Figure 4. Immunohistochemical staining used BCL2, x40

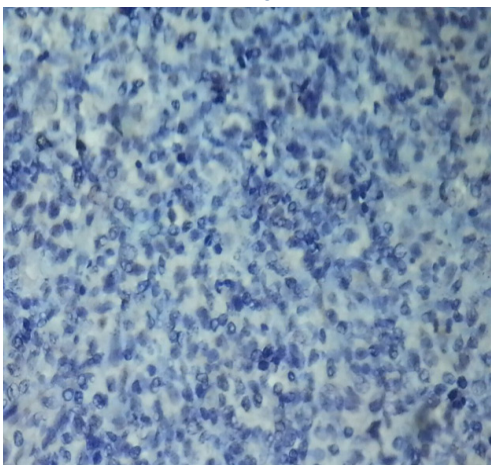


Figure 5. Immunohistochemical staining used CD30, x40

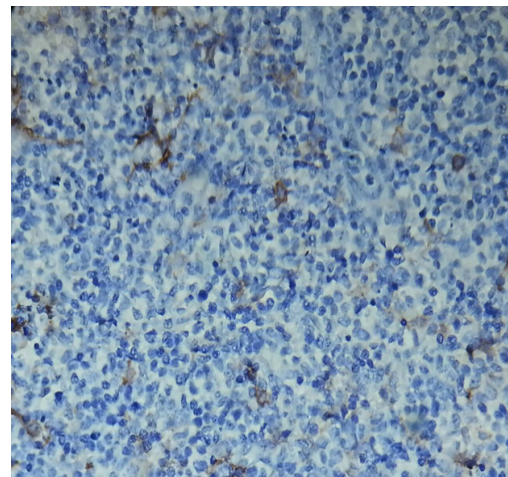


Figure 6. Immunohistochemical staining used CD68, x40

Discussion

Kikuchi-Fujimoto disease or histiocytic necrotizing lymphadenitis is an inflammatory rare benign disorder, involving young patients, predominantly females of less than 40 years of age. This disorder is more prevalent in Asian population.⁽¹⁾ It is characterized by fever and lymphadenopathy. Lymphadenopathy is usually located in the cervical area, and is mostly unilateral and tender.⁽²⁾

Although some kinds of viruses and autoimmune mechanisms has been suggested for its existence, its etiology is unknown. However, no causal relationship is established.^(3,4) In general, the histopathologic characteristics exhibited necrotic foci surrounded by histiocytic aggregates with the absence of granulocytes and the paucity of plasma cells.

Kikuchi-Fujimoto disease has been classified into three histological subtypes. It is assumed to progress from proliferative type (>50%) to necrotizing type (30%) and finally resolve into xanthomatous type (<20%).⁽⁵⁾ An association with systemic lupus erythematosus (SLE) is also shown. There are no specific laboratory tests for this disorder. Because laboratory data are often normal, diagnosis is fundamentally based on the affected lymph node biopsy.^(2,6,7)

In our analysis, the laboratory data of the patient were normal other than elevated ESR and CRP. Also clinical findings were normal other than right submandibular lymphadenopathy and earache. Patient had no recent history of fever, chills, rash, loss of weight, hepatomegaly, and splenomegaly. Histologically, the lesions affect-

ed the cortical and paracortical areas of the node. Differential diagnoses should include malignant lymphoma, infectious diseases such as toxoplasmic lymphadenitis, tuberculous lymphadenitis and cat scratch disease, SLE, CMV, HIV, HSV, and infectious mononucleosis, Kawazaki, yersiniosis, and metastatic carcinoma that are differentiated by biopsy and serologic examinations.^(8,9)

It has a benign evolution process, with a spontaneous healing in some weeks or months. There is no particular treatment for this disorder, and it is supportive and symptomatic (analgesics–antipyretics, nonsteroidal anti-inflammatory drugs, and rarely corticosteroids).^(3,9) In severe or chronic recurrent diseases, steroids and hydroxychloroquine are used. In patients presenting with LAP and other constitutional characteristics (such as fatigue, fever, and weight loss; more cutaneous and mucosal signs), it is important to rule out infection and malignancy first.⁽¹⁾ After diagnosis

regarding the persistence of lymphadenopathy despite prescribing Antibiotics, the patient was treated with Prednisolone, which was effective but mild symptoms relapsed again. After treatment with Acyclovir, the symptoms completely resolved, and the patient had no problems in the follow-up period. In several studies, the disease has progressed to lupus erythematosus.^(10,11,12)

Therefore, it is essential to follow-up patients particularly for the development of symptoms of lupus erythematosus and other autoimmune diseases for few years.⁽⁴⁾

Conclusion

In patients presenting with cervical lymphadenopathy and no definite diagnosis, long term treatment with broad-spectrum antibiotics should be avoided and must be noticed to other differential diagnosis.

References

- 1.Sasapu A, Casperson JB, Craver R, Gedalia A. A 16-Year-Old African American Girl With Necrotizing Lymphadenitis. *ClinPediatr (Phila)*.2012 ;51(10):998-1000.
- 2.Astudillo L. Kikuchi-Fujimoto disease. *Rev Med Interne*.2010 ;31(11):757-65.
- 3.Pandit S, Das A, Choudhury S, Das SK. A rare case of Kikuchi-Fujimoto disease. *J Nat SciBiol Med*. 2013;4(2):490-2.
- 4.Andriamampionona Tsiotery F, Ranaivomanana VF, Laza O, Randrianjafisamindrakotroka NS. Kikuchi-Fujimoto disease: a rare cause of adenopathy mimicking lymphoma or tuberculosis. *Med Sante Trop*. 2015;25(4):441-445.
- 5.Uslu E, Gurbuz S, Erden A, Aykas F, Karagoz H, Karahan S, et al. Disseminated intravascular coagulopathy caused by Kikuchi-Fujimoto disease resulting in death: first case report in Turkey. *Int Med Case Rep J*. 2014 ;7:19-22.
- 6.Lebe E. Kikuchi-Fujimoto disease. *Kulak Burun BogazI this Derg*.2014 ;24(3):164-7. (Turkish)
- 7.Al-Bishri Jamal. Kikuchi Fujimoto disease.*Clin Med Insights Arthritis Musculoskelet Disord*.2012; 5: 63–66.
- 8.Askari SE, Nemati Sh, Sadeghi AA. A Case Report of Kikuchi-fujimoto Disease. *Journal of Guilan University of Medical Sciences*.2010 ;78: 84-87. (Persian)
- 9.Rezayat T, Carroll MB, Ramsey BC, Smith A. A case of relapsing kikuchi-fujimoto disease. *Case Rep Otolaryngol*. 2013: 364-795.
- 10.Sopeña B, Rivera A, Vázquez-Triñanes C, Fluiters E, González-Carrero J, del Pozo M, et al. Autoimmune manifestations of Kikuchi disease.*Semin Arthritis Rheum*.2012; 41(6):900-6.
- 11.Patra A, Bhattacharya SK. SLE Developing in a Follow-Up Patient of Kikuchi’s Disease: A Rare Disorder. *J Clin Diagn Res*.2013;7(4): 752-3.
- 12.Jamal AB. Kikuchi Fujimoto disease. *Clin Med Insights Arthritis Musculoskelet Disord*. 2012;5:63-6. doi: 10.4137/CMAMD.S9895.