

# Evaluation of Anatomical Variations of Paranasal Sinuses in Cone-beam Computed Tomography (CBCT) of Patients with Chronic Rhinosinusitis in Comparing with Normal Individuals

## Original Article

Rahmatollah Banan <sup>1</sup>, Zahra Dalili <sup>2</sup>, Ali Khalighi Sigaroudi <sup>3</sup>, Mohammad Javad Sedaghati <sup>4</sup>

<sup>1</sup> Associate Professor, Department of Ear, Nose and Throat, Research center of allergic diseases of nose and sinuses, Guilan University of Medical Sciences, Rasht, Iran.

<sup>2</sup> Professor, Department of Maxillofacial Radiology, Research center of allergic diseases of nose and sinuses, Guilan University of Medical Sciences, Rasht, Iran.

<sup>3</sup> Assistant Professor, Department of Maxillofacial Surgery, Guilan University of Medical Sciences, Rasht, Iran.

<sup>4</sup> Dentist, Department of Maxillofacial Radiology, Guilan University of Medical Sciences, Rasht, Iran.

Received: Dec 20, 2015

Accepted: Feb 9, 2016

### Corresponding Author:

**Zahra Dalili**

### Address:

Guilan University of Medical Sciences, Rasht, Iran

**E-mail:** zahradalili@yahoo.com

**Telephone:** +98-1333486428

## Abstract

### Introduction:

An exact knowledge of the anatomical variations of the paranasal sinuses (PNS) is critical for surgeons performing endoscopic sinus surgery and for radiologists involved in making preoperative evaluations. An important aspect is the determination of correlation between the anatomical variations of PNS and the presence of chronic rhinosinusitis (CR). Cone-beam computed tomography (CBCT) has a very important role in evaluating the maxillofacial structures. The purpose of this pilot study was to evaluate the anatomical variations of PNS in patients with CR as compared with normal individuals.

**Materials and methods:** This cross-sectional study evaluated the CBCT scans of 57 patients with CR and 28 patients without CR. Anatomical variations observed in the multiplanar images were investigated. Data were processed using SPSS software. Fisher's exact test was used for comparing the incidence of different anatomical variations in the control (normal) and CR (experimental) groups

**Results:** The most frequent anatomical variation was septal deviation in 85.7% of normal individuals and 93% of patients with CR. No statistically significant difference existed between the prevalence of anatomical variations in both groups. In contrast, middle concha bullosa was more prevalent in normal individuals than in patients with CR.

**Conclusion:** Anatomical variations occurring in the PNS alone can not lead to CR. It may be accompanied by systemic, local, and environmental factors that could increase the susceptibility of the patient to this disease.

### Key words:

•Sinusitis •Paranasal Sinuses •Cone-Beam Computed Tomography.

## Introduction

Anatomical variations in the paranasal sinuses (PNS) and their pathological outcomes should be considered to improve treatment strategies and prevent the probable side effects of endoscopic sinus surgery. The impact of some of these variations on the pathogenesis of PNS has been reported, which could change the steps involved in functional endoscopic sinus surgery.<sup>(1)</sup>

Computed tomography (CT) scans have played an important role in evaluating PNS diseases. Because of the feasibility of creating multiplanar reconstruction (MPR) images having high resolution and contrast, CT scans can be an appropriate choice for investigating the complex anatomy of PNS.<sup>(2,3)</sup> Flat-panel cone-beam CT (CBCT) can be a suitable substitute for a conventional multidetector CT scanner. The advantages of achieving greater spatial resolution at lower patient radiation doses and easier image generation can also be the reasons for making this substitution.

Although some studies<sup>(1,4-9)</sup> have reported anatomical variations in PNS to be potential factors leading to the development of chronic rhinosinusitis (CR), only a few studies have compared the prevalence of these variations between normal individuals (control) and CR (experimental) patients. Hence, considering the different theories regarding the association between the anatomical variations of PNS and CR, this study was designed to evaluate the anatomical variations observed in patients with a positive history of CR in comparison with normal individuals. In addition, because of the recent application of CBCT in the field of otolaryngology<sup>(10-13)</sup> and the use of MPR that provides the possibility of making both simultaneous and dynamic investigation of the anatomic structures from different perspectives, we used the CBCT scans.

## Materials and Methods

This cross-sectional study involving the identification and selection of control and experimental groups was carried out for about a year, from June 2013 to August 2014. Based on the patients' clinical examination results, having three or more of the primary symptoms, i.e., mucopurulent nasal secretion, nasal congestion, a feeling of fullness combined with pressure and

pain or anosmia, was necessary to categorize the subjects as patients with a history of CR. Moreover, these patients had never had a history of trauma or syndromal disease. All patients with the aforementioned criteria of CR referred to a designated maxillofacial radiology clinic to undergo a CBCT scan by co-investigator otolaryngologists were included in this study.

In addition, the CBCT images (full mode; 9-inch FOV) of normal individuals, who did not have a history of CR, that were taken for other reasons such as sinus lifting, evaluation of facial trauma, assessment of impacted teeth, and determination of appropriate implant site, were also included. The CBCT scans were obtained by NewTom VG equipment (QR SRL Company, Verona, Italy) in full mode (9-inch FoV, 0.25–0.3 mm voxel size). Exposure parameters for the full mode were 110 kV, 12.85–15.85 mAs, and 3.6 s. After the acquisition of volumetric images, axial images (1 mm thickness and interval) and coronal and sagittal images (2 mm thickness and interval) were prepared to construct the study images. In summary, MPR images were used to diagnose the anatomical variations more accurately (Figures 1A & B).

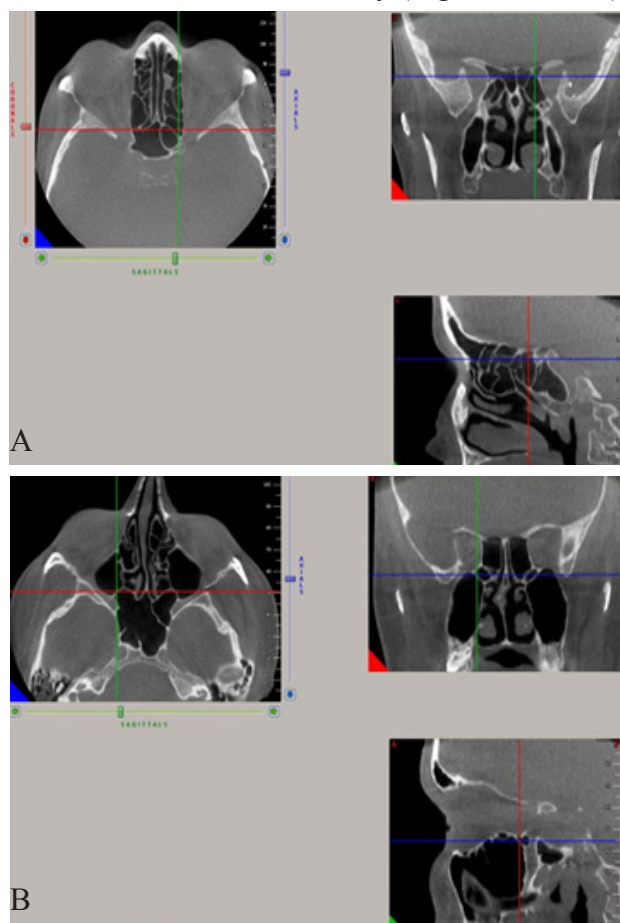


Figure 1. A) Onodi cell; B) Sphenomaxillary plate in reconstructed multiplanar CBCT images

After recording the demographic information of individual patients, a maxillofacial radiologist with more than 15 years of experience evaluated the study images of the CBCT scans of subjects in both normal and CR patient groups. A total of 26 anatomical variations in the PNS and nasal components were assessed. CBCT images were evaluated through the NNT viewer software program used with NewTom imaging system. The relative frequencies of each finding were reported. Chi-square ( $\chi^2$ ) and Fisher's exact tests were used to compare CBCT findings in normal

and CR patient groups. All statistical analyses were performed using the Statistical Package for Social Sciences (SPSS) Version 19.0 for Windows (SPSS; Chicago, USA).

### Results

The study sample consisted of 57 CBCT scans of patients diagnosed with CR and 28 CBCT scans from a normal population, resulting in a total of 85 subjects. The average age range was  $34.21 \pm 13.5$  years in the normal and  $34.24 \pm 14.2$  years in the CR patient group.

**Table 1.** Frequency of anatomical variations observed in frontal sinuses

Frontal sinuses	Side	Normal patients Number (%)	CR Patients Number (%)	P value*
Frontal sinus agenesis	right	2 (7.1)	1(1.8)	0.25
	left	0 (0)	1(1.8)	1
	total	2 (7.7)	2(3.5)	0.59
Septation	right	9 (32.1)	22(38.6)	0.63
	left	10 (35.7)	21(36.8)	1
	total	13 (46.4)	29(50.9)	0.81
Incomplete septation	right	2 (7.1)	9(15.8)	0.32
	left	7(25)	9(15.8)	0.37
	total	7(25)	12(21.1)	0.78
Extension of the frontal sinuses to the lesser wings	right	9(32.1)	20(35.1)	1
	left	8(28.6)	20(35.1)	0.62
	total	10(35.7)	27(47.4)	0.35

\*Fisher-Exact test

**Table 2.** Distribution of anatomical variations found in the maxillary sinuses

Maxillary sinus	Side	Normal patients Number (%)	CR Patients Number (%)	P value*
maxillary sinus agenesis	right	0 (0)	0(0)	-
	left	0 (0)	0(0)	-
	total	0(0)	0(0)	-
Maxillary sinus septation	right	3(10.7)	9(15.8)	0.74
	left	3(10.7)	5(8.8)	1
	total	4(14.3)	10(17.5)	1
Maxillary sinus duplication	right	2(7.1)	0(0)	0.1
	left	2(7.1)	4(7)	1
	total	2(7.1)	4(7)	1
Pneumatization of the uncinate process	right	1(3.6)	2(3.5)	1
	left	7(25)	9(15.8)	0.37
	total	7(25)	9(15.8)	0.37
Absent uncinate process	right	0(0)	3(5.3)	0.54
	left	0(0)	2(3.5)	1
	total	0(0)	4(7)	0.29
Attachment of the uncinate process to the inferior rim of the orbit	right	0(0)	2(3.5)	1
	left	1(3.6)	3(5.3)	1
	total	1(3.6)	4(7)	1

\*Fisher-Exact test

The normal group consisted of 39.3% males and 60.7% females. In the CR patient group, there were 52.6% males and 47.4% females. There was no significant difference between the mean age ( $P = 0.99$ ) and the distribution of sex ( $P = 0.26$ ) in either group.

The most prevalent anatomical variation detected was septal deviation (85.7% in normal subjects and 93% in CR patients).

The frequencies of the anatomical variations observed in PNS and the nasal cavity in each group are presented in Tables 1–5.

No significant difference was observed between the frequencies of anatomical variations observed in the two groups, except for middle concha bullosa that was significantly more prevalent in normal subjects (78.6%) in comparison with CR patients (49.1%).

**Table 3.** Frequency of anatomical variations occurring in ethmoid air cells

Ethmoidal sinuses	side	Normal patients Number (%)	CR Patients Number (%)	P value*
Haller cells	right	9(32.1)	8(14)	0.08
	left	6(21.4)	12(21.1)	1
	total	9(32.1)	13(22.8)	0.43
Agger nasi cells	right	4(14.3)	13(22.8)	0.4
	left	7(25)	16(28.1)	1
	total	9(32.1)	23(40.4)	0.48
Supraorbital ethmoid air cells	right	4(14.3)	4(7)	0.43
	left	2(7.1)	3(5.3)	1
	total	4(14.3)	4(7)	0.43
Ethmoid bulla	right	7(25)	21(3.8)	0.33
	left	10(35.7)	19(33.3)	1
	total	11(39.3)	24(42.1)	1

\*Fisher-Exact test

**Table 4.** Anatomical variations detected in sphenoid sinuses

Sphenoid sinus	side	Normal patients Number (%)	CR Patients Number (%)	P value*
Sphenoid sinus agenesis	right	0(0)	0(0)	-
	left	0(0)	0(0)	-
	total	0(0)	0(0)	-
Onodi cells	right	6(21.4)	6(10.5)	0.19
	left	5(17.9)	15(26.3)	0.43
	total	7(25)	18(31.6)	0.61
Pneumatization of the anterior clinoid process	right	5(17.9)	13(22.8)	0.77
	left	6(21.4)	8(14)	0.53
	total	8(28.6)	14(24.6)	0.79
Sinus overlap	right	1(3.6)	8(14)	0.26
	left	1(3.6)	5(8.8)	0.65
	total	1(3.6)	9(15.8)	0.15
Carotid bulge	right	8(28.6)	15(26.3)	1
	left	8(28.6)	16(28.1)	1
	total	8(28.6)	20(35.1)	0.62
Sphenomaxillary plate	right	5(17.9)	5(8.8)	0.28
	left	3(10.7)	7(12.3)	1
	total	5(17.9)	7(12.3)	0.51
Extension of the sphenoid sinus to the greater wing	right	8(28.6)	13(22.8)	0.59
	left	8(28.6)	18(31.6)	1
	total	10(35.7)	12(33.3)	1

\*Fisher-Exact test

**Table 5.** Anatomical variations found in the nasal cavity

Nasal cavity	Direction	Normal patients Number (%)	CR Patients Number (%)	P value*
Right concha bullosa	superior	1(3.6)	5(8.8)	0.51
	middle	15(53.6)	21(36.8)	
	inferior	0(0)	1(1.8)	
Left concha bullosa	superior	1(3.6)	-	0.12
	middle	17(6.07)	-	
	inferior	0(0)	-	
Total concha bullosa	-----	23(82.1)	34(59.6)	0.05
Paradoxical curvature of the middle turbinate	right	1(3.6)	6(10.5)	0.41
	left	2(7.1)	3(5.3)	1
	total	2(7.1)	7(12.3)	0.71
Protrusion of the superi- or concha	right	0(0)	2(3.5)	1
	left	0(0)	0(0)	-
	total	0(0)	2(3.5)	1
Bifid middle turbinate	right	0(0)	3(5.3)	0.54
	left	1(3.6)	2(3.5)	1
	total	1(3.6)	4(7)	1
Septal deviation	-----	24(87.5)	53(93)	0.43
Pneumatization of the septum	-----	8(28.6)	15(26.3)	1

\*Fisher-Exact test

## Discussion

The present study demonstrated that the most frequent anatomical variation was septal deviation in both normal individuals and CR patients. Similarly, Arslan et al. also reported the most common anatomical variation to be nasal septal deviation (36%) in their study involving 200 patients with CR.<sup>(7)</sup>

Kayalioglu et al.<sup>(14)</sup> who investigated the same aspect reported concha bullosa to be the most prevalent anatomical variation with a frequency of 26.83% in 82 normal subjects and 28.88% in 90 patients with CR. However, our study showed the frequency of this variation to be 82.1% in the normal group and 59.6% in the CR patient group. Another study by Sivash et al.<sup>(6)</sup> reported that the most prevalent variation detected in pediatric patients with chronic sinusitis was middle concha bullosa (58%), which concurs with the findings of Al-Qudah et al. (59.6%).<sup>(4)</sup>

In our study, the bifid middle turbinate was the least frequently seen variation, with 3.6% in the normal group and 7% in the CR patient group, a finding that is comparable with the frequency reported by Kantarci et al. (2.5%).<sup>(1)</sup>

The frequency of pneumatization occurring in the uncinata process in the normal group was

2.5%, whereas it was 15.8% in the CR patient group, which is higher than the 5% frequency observed in pediatric patients reported by Al-Qudah et al.<sup>(4)</sup>

The frequency of pneumatization in the anterior clinoid process was 28.6% in the normal group and 24.6% in the CR patient group, which is higher than 1.22% in non-sinus and 5.55% in sinus patients reported by Kayalioglu et al.<sup>(14)</sup>

In contrast to other studies,<sup>(5,15)</sup> the prevalence of concha bullosa in the normal group (78.6%) was more than that in the CR group (49.1%).

No statistical differences were apparent in the frequency of anatomical variations occurring in CR patients and normal individuals, except for the middle concha bullosa. Therefore, these findings indicate no relationship between the anatomical variations of PNS and CR. This result is in agreement with studies by Al-Qudah et al.<sup>(4)</sup> and Sivash et al.<sup>(6)</sup> However, Kayalioglu et al.<sup>(14)</sup> reported that anatomical variations increase the patient's susceptibility to CR.

## Conclusion

The presence of anatomical variations in the PNS and the nasal cavity alone cannot lead to CR. However, these variations should be considered while evaluating the prognosis of every



treatment besides other factors such as systemic, local, and environmental factors.

### Acknowledgment

We would like to thank Julie Monti Safari for her dedicated effort in editing this manuscript. In

addition, we would like to express our gratitude to the Vice Chancellor of Research and Technology and also to the Research Center for Allergic Diseases of Paranasal Sinuses of Guilan University of Medical Sciences in Rasht, Iran, for the financial support.

### References

1. Kantarci M, Karasen RM, Alper F, et al. Remarkable anatomic variations in paranasal sinus region and their clinical importance. *Eur J Radiol* 2004; 50: 296-302.
2. Huizing EH. Functional surgery in inflammation of the nose and paranasal sinuses. *Rhinology* 1988; 5: 5-15.
3. Kuhn JP. Imaging of the paranasal sinuses: current status. *J Allergy Clin Immunol* 1986; 77: 6-8.
4. Al-Qudah M. The relationship between anatomical variations of the sino-nasal region and chronic sinusitis extension in children. *International Journal of Pediatric Otorhinolaryngology* 2008; 72: 817-821.
5. Ting-Kuang C. Uncommon anatomic variations in patients with chronic paranasal sinusitis. *Otolaryngology-Head and Neck Surgery* 2005; 132: 221-225.
6. Sivash E, Şirikçi A, Bayazıt YA, et al. Anatomic variations of the paranasal sinus area in pediatric patients with chronic sinusitis. *Surg Radiol Anat* 2002; 24: 400-405.
7. Arslan H, Aydinlioğlu A, Bozkurt M, et al. Anatomic variations of the paranasal sinuses: CT examination for endoscopic sinus surgery. *Auris Nasus Larynx* 1999; 26: 39-48.
8. Başak S, Akdilli A, Karaman Z, et al. Assessment of some important anatomical variations and dangerous areas of the paranasal sinuses by computed tomography in children. *International Journal of Pediatric Otorhinolaryngology* 2000; 55: 81-89.
9. Campbell PD, Zinreich SJ, Aygun N. Imaging of the paranasal sinuses and in-office CT. *Otolaryngol Clin North Am* 2009; 42: 753-764.
10. Zoumalan RA, Lebowitz RA, Wang E, et al. Flat panel cone beam computed tomography of the sinuses. *Otolaryngology-Head and Neck Surgery* 2009; 145: 841-844.
11. Minni A, Messineo D, Attanasio G, et al. 3D cone beam (CBCT) in evaluation of frontal recess: findings in youth population. *Eur Rev Med Pharmacol Sci*. 2012; 16: 912-918.
12. Güldner C, Pistorius SM, Diogo I, et al. Analysis of pneumatization and neurovascular structures of the sphenoid sinus using cone-beam tomography (CBT). *Acta Radiol* 2012; 53: 214-219.
13. Robinson M, Donlon D, Harrison H, et al. Variations of the paranasal sinuses in Melanesians as observed by CT. *Rhinology* 2010; 48: 11-17.
14. Kayalioglu G, Oyar O, Govsa F. Nasal cavity and paranasal sinus bony variations: a computed tomographic study. *Rhinology* 2000; 38: 108-113.
15. Meloni F, Mini R, Rovasio S, et al. Anatomic variations of surgical importance in ethmoid labyrinth and sphenoid sinus. A study of radiological anatomy. *Surg Radiol Anat* 1992; 14: 65-70.