

Maxillary Non-ossifying Fibroma: A Case Report and Review of the Literature

Case Report

Amirabbas Jafari ¹, Adineh Javadian Langaroodi ²,
Abbas Shokri ³, Neda Yazdani ⁴, Arash Dehghan ⁵,
Mohammad Jafari ⁶, Amin Mahdavi Asl ¹

¹Postgraduate Student, Department of Oral & Maxillofacial Radiology, Faculty of Dentistry, Hamadan University of Medical Science, Hamadan, Iran

²Assistant Professor, Department of Oral and Maxillofacial Radiology, Faculty of Dentistry, Mashhad University of Medical Sciences, Mashhad, Iran

³ Assistant Professor , Department of Oral and Maxillofacial Radiology, Faculty of Dentistry , Hamadan university of Medical Sciences, Hamadan, Iran

⁴Postgraduate student, Department of Oral & Maxillofacial Radiology, Faculty of Dentistry , Mashhad University of Medical Science, Mashhad, Iran

⁵Assistant Professor , Department of Pathology, Faculty of Medicine, Hamadan University of Medical Sciences, Besat Hospital, Hamadan, Iran

⁶ Assistant Professor, Department of Pathology, Faculty of Medicine, Hamadan University of Medical Sciences, Hamadan, Iran

Received: Feb 19, 2013

Accepted: Mar 16, 2013

Corresponding Author:

Neda Yazdani, DDS

Address: Faculty of Dentistry, Vakilabad Blvd, P.O
Box: 91735-984, Mashhad, Iran

Telephone: +98-511-8829501

Fax: +98-511-7626058

E-mail: Yazdanin891@mums.ac.ir

Abstract

Introduction: Non-ossifying Fibroma (NOF) is a relatively common benign and non-neoplastic lesion in long bones of children and adolescents. As far as very few cases of NOF have been reported in jaws and what was managed to be found regarding all reported cases having occurred only in the mandible, in this article we are going to report a case of maxillary NOF in a 38-year-old female.

Key words: •Case report •Maxilla •Non-ossifying, Fibroma

Case Report

A 38-year-old woman with the chief complaint of postnasal drip was referred to the Oral Medicine Department of the Hamadan Dental School (Hamadan, Iran). There was no history of pain or swelling. In CBCT (cone beam computed tomography)

images a well-corticated radiolucent lesion was observed in the tuberosity of maxilla that caused cortical thinning. It also caused mesial displacement of the maxillary second molar roots and superior displacement of the maxillary sinus floor with an intact cortical border. (Figure 1 A-D)

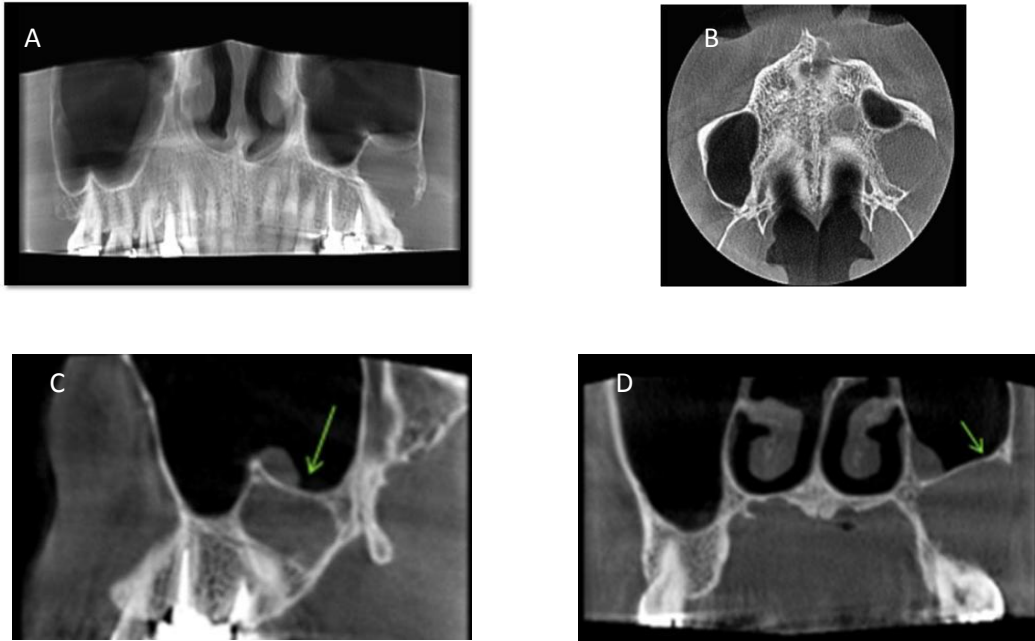


Figure1. A-D: Reconstructed panoramic (A) and axial view (B) of CBCT showing a unilocular radiolucent lesion of the posterior maxilla. Thinned, bowed, and slightly expanded bony cortex is observed in the area. Note to the superior displacement of the maxillary sinus floor in coronal and sagittal views(C&D).

The lesion was excised by curettage in the department of oral and maxillofacial surgery. The specimen (1×1×0.7 cm) had a creamy white nodular appearance with elastic consistency. The specimen was sent for histopathological evaluations.

Hematoxylin and eosin (H&E) staining revealed mesenchymal benign proliferation covered with erosive squamous epithelium and proliferated fibroblasts without atypical nucleus or mitotic function, organized heterogeneously in interlacing bundles. No evidence of tumor tissue necrosis, ameloblastic components, and osteogenesis was present (Figure 2 A, B). According to the histopathological characteristics, NOF was diagnosed for the specimen. Six months later radiological and

clinical follow up showed no evidence of recurrence.

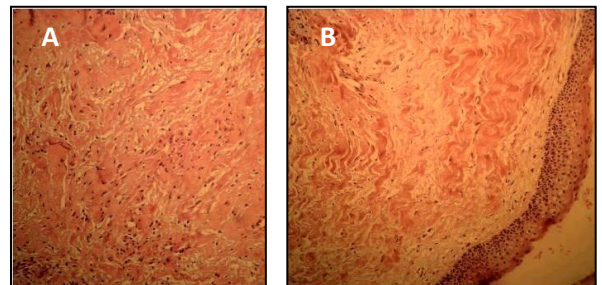


Figure2. A) Fibroblasts proliferation without atypical nucleus or mitotic function, organized heterogeneously in interlacing bundles (H&E stain ×250 magnification) B) Extension of the fibrocytic tissue to the gingival submucosa (H&E stain ×100 magnification)

Discussion

Non-ossifying fibroma (NOF) is a common non-neoplastic lesion of children and adolescents, occurring in growing portions of long bones, especially distal femur and tibia.⁽¹⁻⁷⁾ It was initially described by Sontag and Pyle in 1941⁽⁸⁾ and Lichtenstein and Jaffey in 1992.⁽⁹⁾ Due to its various histopathological characteristics, different terms have been used to define this condition including non-osteogenic fibroma, histiocytic fibrous defect, fibrous cortical defect (FCD), metaphyseal fibrous defect (MFD), benign fibrous histiocytoma (BFH), histiocytic xanthoma, fibroxanthoma, histiocytic xanthogranuloma, and fibrous xanthoma.^(1,2) Although, in most cases these terms could be interchangeable, some studies have mentioned differences between these terms. For instance, despite histopathological similarity between NOF and FCD, they could be differentiated according to the extent of bone involvement. NOF is larger than FCD, also it is elongated and parallel to long axis of bones. Furthermore, there is the possibility of medullary involvement in NOF. Hence, it is possible to differentiate these two entities according to the different features.⁽³⁾ The exact pathogenesis of NOF has yet to be completely identified. Originally, it was considered to be the result of proliferation and migration of the remaining cartilage rests. However, following microscopic evaluation it was assumed to be a benign lesion originating from bone marrow spaces and thus the term NOF was coined.^(1,2)

Hatcher was the first to state questions about the neoplastic nature of this lesion and proposed endochondral growth disorder due to vascular anomaly as the etiologic factor for this lesion and entitled it MFD.⁽¹⁰⁾ Trauma has also been suggested as another etiologic factor. Other proposed etiologies include defect in ossification and disturbance of growth or an aberrance of calcification. At the present time, NOF is regarded as a non-neoplastic lesion; however, a published study cytogenetic effect on NOF reinforced the idea that the presence of clonal chromosomal changes suggests a neoplastic nature for NOF.^(1,2)

Lichtenstein and Jaffey stated that although this lesion had only been observed in

long bones, it could occur in any bone.⁽⁹⁾ Bone lesions are rarely observed in the jaw.⁽¹⁾ Whenever NOF is observed in mandible, it has a tendency to occur in the posterior of mandibular areas and ramus. The reason for this tendency to the posterior portion of mandible and ramus is unknown. However, since these areas are believed to contain mandibular growth centers, the etiology of the mandibular NOF may be similar to the presumed etiology of the long bones.⁽²⁾ Some studies have related this anatomic predilection to the posterior areas of mandible due to the higher amount of bone marrow in these areas.^(1,3) Based on what we managed to find in the related literature, no NOF in maxilla has been reported yet⁽¹⁾ and our recent case would be the first reported case. The involved area in this case, was also the posterior portion of maxilla. Table 1 summarizes the clinical and radiological findings of reported cases of NOF.

NOF is mostly found in individuals younger than 20 years of age. The mean age for mandibular lesion is reported as 21 years.^(1,3,6) Having a 38 year old patient in our study, the mean age is higher than the average reported age of patients with mandibular lesions. However, there are some reports of these lesions occurring at older ages. Rudy reported the oldest case of NOF in 1964 in a 49-year-old patient.⁽¹¹⁾ Cale et al. suggested classifying those lesions that have similar histopathological characteristics to NOF but show different clinical characteristics such as occurrence in older ages, symptoms of pain and swelling, and tendency to recurrence without metastasis as benign fibrous histiocytoma (BFH).⁽¹²⁾ However, since our patient had no complaints of pain or swelling, BFH was considered with a low probability.

NOF in jaws is more prevalent among females and a female to male ratio of 2.2 to 1 has been reported.⁽¹⁾ There seems to be some clinical differences between NOF in mandible and long bones. Men tend to have these lesions in long bones while most mandibular NOFs occur in females. Mandibular lesions could be asymptomatic or lead to slight swelling.^(1,4) Most long bone lesions are asymptomatic and have a limited size and cause little

deformity. Occasionally, these lesions are capable of gross enlargement that can finally result in pathological fracture. However, some cases may resolve spontaneously.⁽⁴⁾

Unlike NOFs of long bones that can be accurately diagnosed by radiography, due to rarity of them in jaws, a definite radiological

diagnosis is not possible^(1,4) and the lesion could be easily mistaken with odontogenic tumors or cysts.^(1,2) In most cases, NOF is displayed as a round or oval radiolucent lesion with well-defined borders, and smooth and lobulated edges surrounded by sclerotic bone.⁽¹⁾

Table.1: Summary of clinical and radiographic characteristics of reported NOFs

Case	Author	Age/gender	Location	Radiographic feature	Treatment
1	Rudy and Scheingold 1964 ⁽¹¹⁾	49/F	Body/Ramus	Multilocular	Curettage
2	Quinn et al. 1970 ⁽¹⁶⁾	21/F	Angle	Unilocular	Curettage
3	Liaw et al. 1979 ⁽¹⁵⁾	17/F	Posterior of mandible	Unilocular	Resection
4	Makek 1980 ⁽⁷⁾	20/M	Condyle	Multilocular	Resection
5	Ide et al. 1982 ⁽¹⁷⁾	37/F	Body(mandible)	Multilocular	Curettage
6	Mirra et al 1982 ⁽¹⁸⁾	12/F	Body(mandible)	Unilocular	Curettage
7	Park et al 1982 ⁽¹⁹⁾	21/F	Body(mandible)	Unilocular	Curettage
8,9	Elzay et al 1984 ⁽⁶⁾	11/F	Ramus	Multilocular	Curettage
		11/F	Ramus/Angle	Multilocular	Curettage
10	Bessho et al 1986 ⁽²⁰⁾	28/M	Body (mandible)	Unilocular	Curettage
11	Aldred et al 1989 ⁽⁴⁾	18/F	Condyle	Multilocular	Resection
12	Mizukawa et al 1997 ⁽²¹⁾	7/M	Body (mandible)	Unilocular	Curettage
13	Uçkan et al. 1999 ⁽²²⁾	16/F	Body (mandible)	Multilocular	Curettage
14	Baily et al. 2001 ⁽³⁾	6/F	Angle	Multilocular	Curettage
15	Hudson et al 2003 ⁽²³⁾	13/M	Condyle	Unilocular	Curettage
16,17	Abdelsayed et al. 2010 ⁽²⁾	14/F	Ramus	Multilocular	Curettage
		27/M	Ramus	Multilocular	Curettage
18	Chracanovic et al 2011 ⁽¹⁾	15/M	Angle	Unilocular	Curettage
19	Present case	38/F	Tuberosity(maxilla)	Unilocular	Curettage

Although the lesion could be multilocular,⁽³⁾ half of the reported NOFs were unilocular.⁽¹⁾ In addition, cortical thinning or expansion might be present.⁽³⁾ It seems that the mandibular radiographic features of NOF of jaw are similar to typical lesions in long bones with scalloped sclerotic margins producing multilocular views.⁽⁴⁾ In the present case, NOF was displayed as a lytic unilocular lesion in the posterior maxilla causing superior displacement of the maxillary sinus floor and a little expansion in the posterior aspect of maxilla. Initial differential diagnoses proposed according to radiographic view include odontogenic myxoma, odontogenic keratocyst, and ameloblastoma. No straight septum as the typical sign of myxoma was observed in the lesion.⁽¹³⁾ Besides, unilocular myxoma usually occurs in

the anterior portion of jaws.⁽¹⁴⁾ Unlike the expected radiographic feature of ameloblastoma, curved and coarse septa, significant cortical expansion; and root resorption were not present in our patient.⁽¹³⁾ Some researchers have been suspicious about the occurrence of NOF in jaws. They have suggested that central giant cell granuloma (CGCG) is the mandibular presentation of long bone NOF. However, there are some major histopathological differences.⁽³⁾ Histopathological identification of NOF is defined by whorled storiform fibrous connective tissue, spindle-shaped fibroblasts, multinucleated giant cells, and variable presence of foam cells or xanthoma cells that seem to be derived from transformed fibroblastic cells, and lack of bone production in the lesion.⁽³⁾ Three histopathological

characteristics for the differentiation of NOF and CGCG are whorled connective tissue stroma which is specific in NOF and only seen as local patches in CGCG, absence of foam cells in CGCG that are present in 25% of NOFs, and finally absence of osteogenesis that is common in CGCG.^(1,3) Since various lesions including CGCG, benign fibrous histiocytoma, cherubism, fibrous dysplasia, and malignant fibrous histiocytoma are considered as differential diagnoses for NOF^(1,2), a detailed histopathological evaluation is necessary. Also, whenever microscopical differentiation is not possible, careful radiological and clinical investigations are required.

NOF is usually treated by curettage or enucleation.^(1,2) Regardless of how extensive surgical interventions are, recurrence has not been reported.⁽¹⁾ However, large lesions require more extensive surgeries such as

segmental resection.⁽¹⁵⁾ Radiation is not recommended for treatment of NOF.⁽⁷⁾

In our case, curettage was used to treat the lesion and no evidence of recurrence was observed after a 6- months follow up.

Conclusion

Non-ossifying fibroma especially in the maxilla is quite a rare lesion; therefore, it can result in diagnostic problems for clinicians, radiologists and pathologists. Important factors which can help differentiate these lesions are asymptomatic nature, radiologic feature and finally histopathologic findings. The treatment of this lesion is simple curettage.

Acknowledgement

The authors wish to appreciate the heartfelt contributions of oral pathology and radiology departments of Hamadan Dental School.

References

1. Chrcanovic BR, Albanese AL, Freire-Maia B, et al. Non-ossifying fibroma (metaphyseal fibrous defect) of the mandible. *Oral Maxillofac Surg* 2011; 15:233–7.
2. Abdelsayed RA, Sharma S, Ferguson H, Augusta. Fibrous cortical defect (Non-ossifying fibroma) of the mandibular ramus: report of 2 cases. *Oral Surg Oral Med Oral Pathol Oral Radiol Endod* 2010; 110:504-8.
3. Bailey JS, Nikitakis NG, Lopes M, Ord RA. Non-ossifying Fibroma of the Mandible in a 6-Year-Old Girl: A Case Report and Review of the Literature. *J Oral Maxillofac Surg* 2001; 59: 815-8.
4. Aldred MJ, Breckon JJW, Hollands CS. Non-osteogenic fibroma of the mandibular condyle. *Br J Oral Maxillofac Surg* 1989; 27(5):412-6.
5. Peuchmaur M, Forest M, Tomeno B, Abelanet R. Multifocal nonosteogenic fibroma: report of a case with ultrastructural findings. *Hum Pathol* 1985; 16: 751-3.
6. Elzay RP, Mills S, Kay S. Fibrous defect (Non-ossifying fibroma) of the mandible. *Oral Surg* 1984; 54: 402-7.
7. Makek M. Non-ossifying fibroma of the mandible. A common lesion with unusual location. *Arch Orthop Trauma Surg* 1980; 96(3):225–7.
8. Sontag LW, Pyle DI. The appearance and nature of cyst-like areas in distal femoral metaphyses of children. *Am J Roentgenol Radiat Ther* 1941; 46:185-8.
9. Jaffe HL, Lichtenstein L. Non-osteogenic fibroma of bone. *Am J Pathol* 1942; 18:205–20.
10. Hatcher CH. The pathogenesis of localized fibrous lesions in the methaphyses of long bones. *Ann Surg* 1945; 122: 1016-30.
11. Rudy HN, Scheingold SS. Solitary xanthogranuloma of themandible: Report of a case. *Oral Surg Oral Med Oral Pathol* 1964; 18:262–71.
12. Cale AE, Freedman PD, Kerpel SM, Lumerman H. Benign fibrous histiocytoma of the maxilla. *Oral Surg Oral Med Oral Pathol* 1989; 68:444-50.

13. White SC, Pharoah MJ .Oral Radiology: principles and interpretation. 6th ed. St.luis: Mosby; 2009. pp: 375,386.
14. Wood NK, Goaz PW. Differential diagnosis of oral and maxillofacial lesions.5th ed. St.luis: Mosby; 1997.pp:343.
15. Liaw WJ, So TK, Yao YT. Non ossifying fibroma of mandible. A case report. J Formos Med Assoc 1979; 78:795–802.
16. Quinn JH, Graves LR, Leonard GI. Unusual histiocytic lesion of the mandible: report of a case. J Oral Surg 1970; 28:528–30.
17. Ide F, Kusuhara S, Onuma H,Miyake T, Umemura S . Xanthic variant of the Non-ossifying fibroma (so called xanthofibroma) of the mandible: an ultrastructural study. Acta Pathol Jpn1982 ; 32:135–42.
18. Mirra JM, Gold RH, Rand F. Disseminated Non-ossifying fibromas in association with café-au-lait spots (Jaffe-Campanacci syndrome). Clin Orthop Relat Res 1982; 168:192–205.
19. Park JK, Levy BA, Hanley JB. Non-ossifying fibroma of the mandible: report of a case. J Baltim Coll Dent Surg1982; 35:1–5.
20. Bessho K, Murakami K, Nishida M, et al. Non-ossifying fibroma of the mandible: case report and review of literature. Jpn J Oral Maxillofac Surg 1986; 32:291–6.
21. Mizukawa N, Nishijima Y, Nishijima K. Metaphyseal fibrous defect (Non-ossifying fibroma) in the mandible. A case report. Int J Oral Maxillofac Surg1997; 26:129–30.
22. Uçkan S, Gürol M, Mutlu N, Güngör S. Non-ossifying fibroma of the mandible: report of a case. Br J Oral Maxillofac Surg1999; 37:152–4.
23. Hudson JW, Livesay KW, McCoy JM. Condylar clesion. J Oral Maxillofac Surg 2003; 61: 824–6.