

The Effect of Oral Curcumin on Pain and Clinical Appearance of Oral Lichen Planus

Seyed Javad Kia¹, Maryam Basirat², Leila Estakhr³

ARTICLE INFO

Article type:

Original Article

Article history:

Received: Oct 30, 2016

Accepted: Mar 15, 2017

Available online:

¹Assistant Professor, Dental Sciences Research Center, Department of oral and maxillofacial medicine, Faculty of Dentistry, Guilan University of Medical Sciences, Rasht, Iran.

²Assistant Professor, Dental Sciences Research Center, Department of oral and maxillofacial medicine, Faculty of Dentistry, Guilan University of Medical Sciences, Rasht, Iran.

³Dentist.

Corresponding Author:

Maryam Basirat

Address:

Department of Oral Medicine, Guilan University of medical sciences, Rasht, Guilan, Iran.

E-mail: mbasirat2010@gmail.com

Telephone: +98981333486422

Fax: +981333486423

Abstract

Introduction:

Lichen planus is an inflammatory mucocutaneous disease that its etiology is still unknown. Various treatments are used to mitigate the pain, inflammation, and duration of lesions. Due to the lack of a definitive treatment and the side effects of current treatments, many efforts still have been making to find new treatments. As curcumin has been shown to have anti-inflammatory, analgesic, antimicrobial, and anti-tumor properties, this study was designed to study the effect of oral curcumin in treating oral lichen planus.

Materials and methods:

Ten patients with oral atrophic, erosive lichen planus participated in a pilot clinical trial intervention study. The patients were treated with 3 strips of Sina Curcumin capsules 80 mg, one capsule every day after breakfast for 4 weeks. The clinical appearance of lesions (based on the Thongprasom score) and pain severity (based on the Visual Analogue Score) were recorded before treatment and at the end of the first, second, and fourth weeks of the intervention.

Results:

Using repeated measures analyses of variance, there were statistically significant differences in pain intensity ($P = 0.043$) and clinical appearance of oral lesions ($P = 0.001$) in patients treated with curcumin before and after treatment. At the end of the treatment period, pain was reduced in 50% of the patients and full recovery was observed in 20% of the patients. Clinical appearance of oral lesions indicated recovery in 20% of the patients.

Conclusion:

Using a nanomicell formulation of oral curcumin could be considered as an alternative treatment for oral lichen planus. This drug is safe and has few side effects. However, it needs further studies with larger sample sizes and follow up periods.

Key words:

•Aphthous •Curcumin •Triamcinolone Acetonide •Therapeutics.

Copyright: [2017] Journal of Dentomaxillofacial Radiology, Pathology, and Surgery.

> **Please cite this paper as:**

Kia SJ, Basirat M, Estakhr L. The Effect of Oral Curcumin on Pain and Clinical Appearance of Oral Lichen Planus. 3DJ 2017;6(1):1-7.

Introduction

Lichen planus is an inflammatory mucocutaneous disease.⁽¹⁾ Although its etiology is still unknown⁽²⁾, it is clear that complex

immunological processes that lead to the degeneration of basal keratinocytes have a role in its etiology.^(1, 3-4)

Local inflammatory responses are elevated in this disease due to sustained generation of cytokines such as tumor necrosis factor- α (TNF- α), interleukin-6 (IL-6), granulocyte-macrophage colony-stimulating factor (GM-CSF), interleukin-12 (IL-12), and interleukin-1 β (IL-1 β), as well as oxidant/antioxidant imbalances.^(5, 6) The disease's outbreak has been reported about 1%- 5% .^(1, 7) Although oral lichen planus can be found in any age, its highest incidence is in middle aged persons, ages 30–60 years old, and it occurs more commonly in women.^(1,2,7) Oral involvement is common in this disease and the only observable location of the disease may be the buccal mucosa; however, the tongue, gums, labial mucosa, and lower lip vermilion may also be involved.^(1-3, 5)

The aim of all current therapeutic strategies is to reduce or eliminate the disease's symptoms.^(1,7)

Corticosteroids are useful in OLP treatment due to their anti-inflammatory and immunosuppressant effects that inhibit the function of T-cells.^(1,7) Topical immunosuppressive drugs like cyclosporine, tacrolimus, pimecrolimus⁽⁸⁾, and vitamin A metabolites are used in lichen planus treatment.⁽⁹⁾ Due to the side effects of the aforementioned drugs, there is an ongoing effort to find an effective herbal drug as a treatment.^(10,11) Natural drugs such as the G2 vaccine⁽¹²⁾ and laser therapy have also been used to treat this disease.⁽¹³⁾

Curcumina longa is a perennial plant from the Zingiberaceae family that has been used in Indian traditional medicine due to its anti-inflammatory effects.⁽¹⁴⁾ The main constituents of Curcumina longa are three curcuminoids including curcumin, the main constituent responsible for its yellow color and anti-inflammatory effect, dimethoxycurcumin, and bismethoxycurcumin; the plant also contains volatile oils, sugars, proteins, and resins. All three effective components have antioxidant effects. It has been reported that the curcuminoids, even at high doses, are very safe and have few side effects.⁽¹⁴⁻¹⁵⁾

Curcumin inhibits phospholipase, lipo-oxygenase, and cyclooxygenase-2 enzymes, and decreases the expression of inflammatory cytokines such as IL-12, TNF- α , IL-6, and IL-1 β , and also down regulates of protein kinase C, which modulates the inflammation and the proliferation of tumor cells.⁽¹⁶⁻¹⁷⁾ Moreover, curcum-

in can increase the secretion of cortisol from the adrenal gland, and some studies have reported that increased adrenal steroids including cortisol can decrease IL-1, IL-6, and TNF- α .

Curcumin regulates the function of inducible nitric oxide synthesized (iNOS). Inflammatory cytokines can activate iNOS during inflammatory processes, which releases large amounts of nitric oxide; and nitric oxide inhibits the growth of microorganisms.⁽¹⁶⁻¹⁸⁾

By considering curcumins effects, this research was conducted to study the effects of oral curcumin on the pain and clinical appearance of lichen planus.

Materials and Methods

Patients:

The present research is pilot clinical trial intervention study. Thirteen patients with clinical symptoms of atrophic, erosive oral lichen planus who had been referred to the clinic at Guilan Dental University in 2016 were selected; their disease was confirmed by two oral and maxillofacial specialists and by histopathological examination.

Three of them did not return for follow-up treatment, therefore they were excluded from the research. Ten patients participated till the end of the research.

The patients with atrophic, erosive lichen planus had stopped using topical corticosteroids 2 weeks before the study and systemic corticosteroids one month prior to the study were selected. Pregnancy and breastfeeding, peptic ulcers, a history of gallstones, and high liver enzyme levels were exclusion criteria.

Patients with existing orthodontic treatments, alcohol consumption, drug and narcotic abuse, patients receiving anticoagulants such as warfarin, or who were taking immunosuppressive, chemotherapeutic or immunomodulator medications, and patients who could not understand the consent form were excluded.^(17,18) Age, gender, medical history, smoking, type and location of the oral lesion, duration of illness, and type of treatment that the patient had previously received for his or her lichen planus disease were recorded in a check list. Pain intensity and the clinical appearance of oral lesions at the beginning of the study and at the end of the first, sec-

ond, and fourth weeks of treatment were also recorded in the check list. We obtained informed consent from all participants.

The information was gathered confidentially and was used solely for research objectives. In addition, a written instruction leaflet was handed to them. The patients were advised, in case of adverse effects, to inform us. The registration number of the clinical trial is IRCT201607032950N4.

Taking Medication:

The patients were treated with 3 strips of Sina Curcumin capsules 80 mg (Exir Nono Sina Company and Mashhad University of Medical Science) following the manufacturer's instructions. Each strip contained 10 capsules.

The patients were informed about their disease and about the Sina Curcumin capsules, and took one capsule every day after breakfast for 4 weeks.

Clinical evaluation, pain scaling and clinical appearance of lesions:

The visual analogue scale (VAS) was used for evaluating the pain and burning sensation at each session. We asked the patients about the degree of pain on a score of 0–10, where 0 indicates no pain and 10 indicates the most severe pain. In order to evaluate the clinical appearance of lesions, the Thongprasom scale was used. Its rating is as follows.

0- No lesion.

1- Mild white striae and no area with erythematous.

2- White striae with atrophic area smaller than 1 cm².

3- White striae with atrophic area larger than 1 cm².

4- White striae with erosive (ulcerative) area smaller than 1 cm².

5- White striae with erosive (ulcerative) area larger than 1 cm².⁽¹⁹⁾

In this study we determined a complete remission to entail when the signs and symptoms of disease decreased by 100%, and when the signs and symptoms decreased 50% or more it was considered a good response. When the signs decreased less than 50%, it was a poor response. If the status of lesions showed no change, it was considered to be no response.

The data were analyzed by SPSS (Version 21) using t-test to evaluate and compare the states

before and after taking oral curcumin. In order to compare VAS at different times, t-test and repeated measure ANOVA test were used. (P<0.05)

Results

In this research, 10 patients with symptomatic oral lichen planus were studied. Three patients were excluded due to non-cooperation. The average age of the patients was 49.8 years old and the average duration of the illness was 26 month (Table 1).

Among them, the youngest patient was 31 years old and the oldest one was 64 years old; and the shortest duration of the illness was 6 months and the longest duration was 50 months. In most patients there were 3 affected areas (50%). There were 26 affected areas in total patients. The most affected area was the buccal mucosa (34.6%), followed by the gums and mandible (26.9%) (Table 1).

The mean VAS score was 3.8±3.61 at baseline, which increased to 4.1±3.38 at the second visit and decreased to 3.5±2.99 and 2.7±3.16 at the third and fourth visits, respectively. Using repeated measures ANOVA, there were statistically significant differences in pain intensity in patients treated with curcumin before and after treatment (P = 0.043) (Table 2,3).

The mean Thongprasom score was 3.5 ± 1.08 at baseline, which decreased to 3.4 ± 1.17, 3.0 ± 1.24, and 2.5 ± 1.17 at the second, third, and fourth visits, respectively. Using repeated measures ANOVA, there was a significant statistical difference in the clinical appearance of oral lesions in patients treated with curcumin (P = 0.001) (Tables 2, 3).

At the end of the four-week treatment period, pain and burning sensations improved in 50% of the patients and complete remission was observed in 10% of the patients (Figures 1, 2).

At the end of the four week treatment period, the clinical appearance of oral lesions improved in 80% of the patients and good responses were observed in 20%. No patient had complete remission (Figures 1, 2).

The Effect of Oral Curcumin on Oral Lichen Planus

Table 1.Demographics and ulcer history of participants

Demographic	Age	Gender (F/M)	Disease duration	Site Involvement						
				Total	Upper gum	Lower gum	Buccal mucosa	Tongue	Floor of mouth	Other sites
Mean ± SD	49.8 ± 10.13	-	26.0 ± 16.35	-	-	-	-	-	-	-
Number(%)	-	9/1	-	26 (100)	5(19.3)	7(26.9)	9(34.6)	2(7.7)	1(3.8)	2(7.7)

SD: Standard Deviation

Table 2.Demographics, VAS, and Thongprasom score (Tg) of lesions of sample before treatment and at the end of weeks 1, 2, and 4 of treatment

Case	Age	Gender	VAS0	VAS1	VAS2	VAS4	Tg0	Tg1	Tg2	Tg4
1	52.00	female	2.00	2.00	2.00	2.00	2.00	2.00	2.00	2.00
2	47.00	female	2.00	8.00	2.00	.00	3.00	3.00	3.00	3.00
3	31.00	female	3.00	3.00	2.00	1.00	3.00	3.00	2.00	2.00
4	50.00	female	6.00	4.00	4.00	4.00	5.00	5.00	4.00	4.00
5	47.00	Male	2.00	3.00	3.00	2.00	3.00	3.00	2.00	2.00
6	57.00	female	1.00	1.00	1.00	1.00	3.00	2.00	2.00	1.00
7	56.00	female	10.00	8.00	7.00	6.00	5.00	5.00	5.00	4.00
8	64.00	female	10.00	10.00	10.00	10.00	5.00	5.00	5.00	4.00
9	36.00	female	2.00	2.00	4.00	1.00	3.00	3.00	3.00	2.00
10	58.00	female	.00	.00	.00	.00	3.00	3.00	2.00	1.00

VAS: visual analogue score

Tg: Thongprasom score

Table 3.VAS and Thongprasom score of lesions before and after treatment

	Week 0	Week 1	Week 2	Week 4	
Vas	3.8 ± 3.61	4.1 ± 3.38	3.5 ± 2.99	2.7 ± 3.16	F = 5.54, P=0.043
Thongprasom score of lesion	3.5 ± 1.08	3.4 ± 1.17	3.0 ± 1.24	2.5 ± 1.17	F = 23.43, P=0.001

VAS: visual analogue score

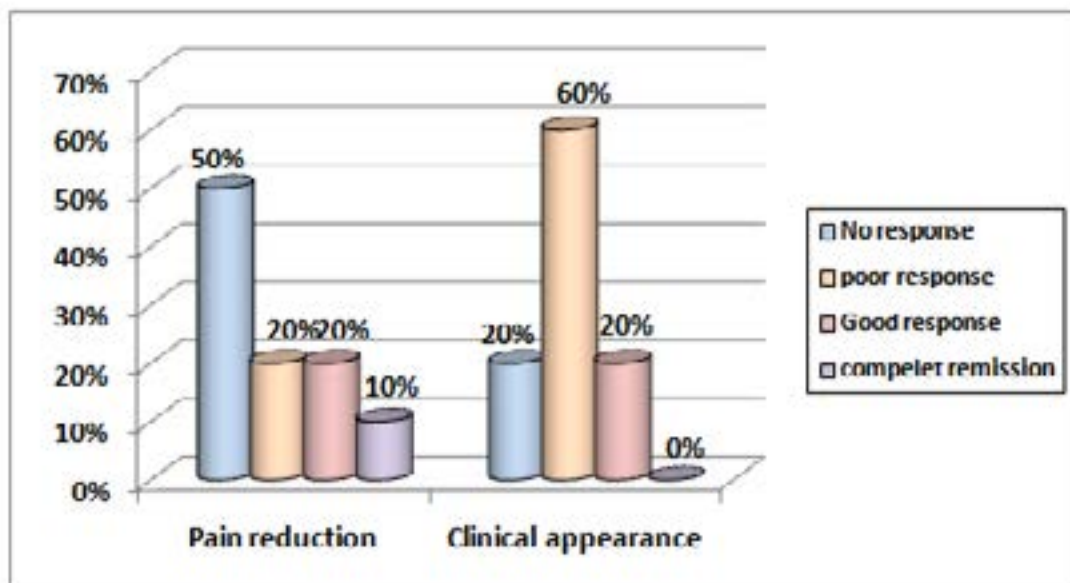


Figure 1. Comparison of pain reduction (based on VAS scale) and clinical appearance (based on Thongprasom score) at the end of treatment

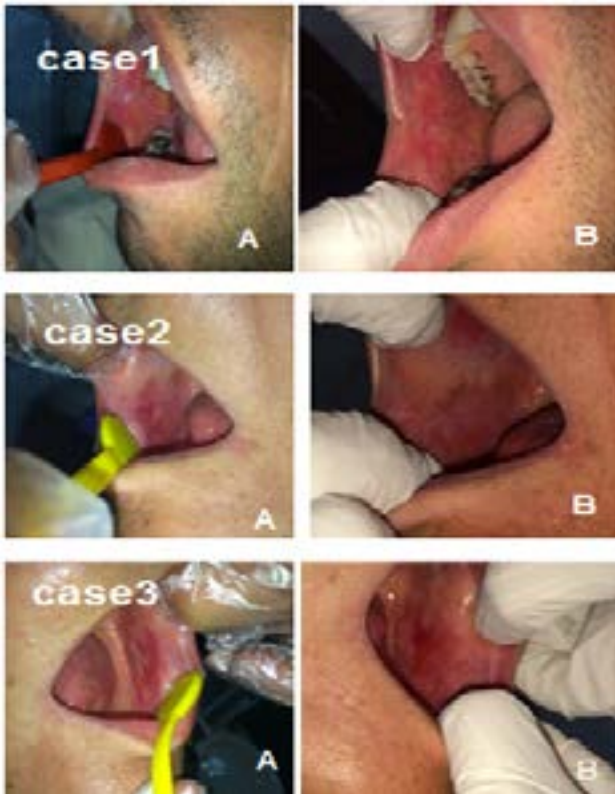


Figure 2. Pictures of oral lichen planus lesions before (A) and after (B) treatment during treatment in 3 cases.

Discussion

The research objective was to study the effects of oral curcumin on oral lesions associated with lichen planus, and the results showed that oral curcumin is effective at reducing pain, burning sensations, and the clinical appearance of oral lesions in patients.

Nowadays, using natural and herbal medicines (remedies) are taken into consideration in disease treatments. Aloe vera gel⁽²⁰⁾, cedar honey⁽²¹⁾, oral lycopene⁽²²⁾, ignatia homeopathic remedy⁽²³⁾, angustifolia⁽²⁴⁾, and curcuminoids⁽²⁵⁻²⁸⁾ have been used in treating oral lichen planus.

Recent studies suggest that increased oxidative stress and imbalances of antioxidant defenses affect lichen planus etiology. Imbalance of antioxidant defense can lead to lipid peroxidation, DNA oxidative damage, and changes in dermis proteins.^(6,29) Therefore, a factor with both anti-inflammatory and antioxidant effects can be help to improve the lesions in lichen planus.

Flavonoids, carotene-like substances, polyphenols, enzymes (glucose oxidase and catalase), organic acids, amino acids, and proteins have antioxidant effects.^(30,31)

Curcumin is a hydrophilic polyphenol with antioxidant effects.^(26,32) Different studies have identified anti-inflammatory, antioxidant, anti-bacterial and antitumor features of curcumin.^(14, 33) In the present study, a nanomicell formulation of oral curcumin was prescribed that can increase the bioavailability of this drug. In this study, the healing of oral lesions was clear, which is consistent with the study by Chainani et al.⁽²⁷⁾ They found that lichen planus lesions respond to high dose curcumin (600 mg per day in 3 doses) and tolerated this dose very well; but high doses of curcumin caused diarrhea in the patients.

The criteria for measuring of pain was different in the two studies. Our findings were inconsistent with the results of Chainani et al.⁽²⁸⁾ They used 200 mg doses of curcumin for 7 weeks in order to treat the oral lesions of lichen planus in comparison with placebo and completed the treatment with predniselone. Amirchaghmaghi et al. used 500 mg of curcumin tablets twice daily in patients with oral lichen planus in comparison with a placebo and completed the treatment with dexamethasone mouth rinse and nystatin, as an antifungal. They found the effectiveness of curcumin was low and believed that curcumin can only be effective in high doses.⁽²⁶⁾ bioavailability of curcumin is low due to its low absorption, rapid metabolism, and rapid systemic elimination.⁽⁴⁾ In recent years, its bioavailability has been increased using nanotechnology and producing nanomicelle formulations that can improve its effectiveness. This could explain the differences in the results of the present study and the two other^(26, 28) studies.

At the end of the four-week treatment period, pain and burning sensation was improved in 50% patients and good clinical appearance responses were observed in 20% of the patients, but 20% showed no response to treatment.

This could be due to a short follow-up period and other factors such as psychological factors. They should be considered in future studies. Some studies have reported that psychological stressors can intensify the lichen planus lesions and psychological treatments have been effective in such conditions.

Conclusion

Using a nanomicell formulation of oral curcumin could be considered as an alternative treatment for oral lichen planus. This drug is safe and has few side effects. However, it needs further studies with larger sample sizes and longer follow-up periods.

Conflict of Interest

The authors declare that they have no conflict of interest.

Ethical approval

This study was approved by IRCT201607032950N4. All procedures performed in studies involving human participants were in accordance with the ethical standards of the institutional and national research committee and with the 1964 Helsinki declaration and its later amendments or comparable ethical standards.

References

1. Glick M. *Burket's Oral Medicine*. 11th ed. People's Medical Publishing House; 2014: chapter 12, 176-9.
2. Farhi D, Dupin N. Pathophysiology, etiologic factors, and clinical management of oral lichen planus, part I: facts and controversies. *Clin Dermatol*. 2010;28(1):100-8.
3. Payeras MR, Cherubini K, Figueiredo MA, Salum FG. Oral lichen planus: focus on etiopathogenesis. *Arch Oral Biol*. 2013;58(9):1057-69.
4. Kia SJ, Mansourian A, Nikkhah M, Nikparto N, Shanbezadeh N. Type and Portions of Peripheral Blood T Lymphocytes in Oral Lichen Planus. *Avicenna Journal of Dental Research*. 2013;5(1):1-4.
5. Roopashree M, Gondhalekar RV, Shashikanth M, George J, Thippeswamy S, Shukla A. Pathogenesis of oral lichen planus—a review. *J Oral Pathol Med*. 2010;39(10):729-34.
6. Mishra SS, Maheswari TU. Evaluation of oxidative stress in oral lichen planus using malonaldehyde: A systematic review. *Journal of Dermatology & Dermatologic Surgery*. 2014;18(1):2-7.
7. van der Waal I. Oral Lichen Planus: Diagnosis and Management. *Journal of Dentistry Indonesia*. 2015;22(3):89-92.
8. Singhi R, Vahanwala S, Pagare S. A Study of Role of Tacrolimus in the Treatment of Lichen Planus. *International Journal of Contemporary Medicine*. 2013;1(2):78.
9. Petruzzi M, Lucchese A, Lajolo C, Campus G, Lauritano D, Serpico R. Topical retinoids in oral lichen planus treatment: an overview. *Dermatology*. 2013;226(1):61-7.
10. Kurago ZB. Etiology and pathogenesis of oral lichen planus: an overview. *Oral Surg Oral Med Oral Pathol Oral Radiol*. 2016;122(1):72-80.
11. Rivas-Tolosa N, Requena C, Llombart B, Alcalá R, Serra-Guillen C, Calomarde L, et al. Antimalarial Drugs for the Treatment of Oral Erosive Lichen Planus. *Dermatology*. 2015;232(1):86-90.
12. Kia S, Sahebamee M, Mighani G, Tohidastekrad Z, Vahedi M. The Impact of Immunotherapeutic G2 Vaccine on Treatment of Oral Lichen Planus. *Journal of Dentistry of Shiraz University of Medical Sciences*. 2011;11:29-34.
13. Basirat M. The Effects of Low Power Lasers in Healing of Oral Ulcers. *J Lasers Med Sci*. 2012;3(2):79.
14. Jurenka JS. Anti-inflammatory properties of curcumin, a major constituent. *Altern Med Rev*. 2009;14(2):141-53.
15. Hossain CF, Al-Amin M, Rahman KMM, Sarker A, Alam MM, Chowdhury MH, et al. Analgesic principle from *Curcuma amada*. *J Ethnopharmacol*. 2015;163:273-7.
16. Anand P, Kunnumakkara AB, Newman RA, Aggarwal BB. Bioavailability of curcumin: problems and promises. *Mol Pharm*. 2007;4(6):807-18.
17. Chainani-Wu N. Safety and anti-inflammatory activity of curcumin: a component of tumeric (*Curcuma longa*). *J Altern Complement Med*. 2003;9(1):161-8.
18. Asher GN. Clinical utility of curcumin extract. *Altern Ther Health Med*. 2013;19(2):20.
19. Thongprasom K, Luangjarmekorn L, Sererat T, Taweewasap W. Relative efficacy of fluocinolone acetonide compared with triamcinolone acetonide in treatment of oral

Informed consent

Informed consent was obtained from all patients.

Acknowledgement

The authors would like to thank Mahmood Hafezi and Zahra Pourhabibi for performing statistical analysis and all patients participated in this research.

- lichen planus. *J Oral Pathol Med.* 1992;21(10):456-8.
20. Salazar-Sánchez N, López-Jornet P, Camacho-Alonso F, Sánchez-Siles M. Efficacy of topical Aloe vera in patients with oral lichen planus: a randomized double-blind study. *J Oral Pathol Med.* 2010;39(10):735-40.
21. Sanatkhani M, Mosannen Mozafari P, Amirchaghmaghi M, Najafi Fathi M, Sanatkhani M, Sarjami N, et al. Effect of cedar honey in the treatment of oral lichen planus. *Iran J Otorhinolaryngol.* 2014;26(3):151-61.
22. Saawarn N, Shashikanth M, Saawarn S, Jirge V, Chaitanya NC, Pinakapani R. Lycopene in the management of oral lichen planus: a placebo-controlled study. *Indian J Dent Res.* 2011;22(5):639.
23. Mousavi F, Sherafati S, Mojaver YN. Ignatia in the treatment of oral lichen planus. *Homeopathy.* 2009;98(1):40-4.
24. Taheri JB, Anbari F, Maleki Z, Boostani S, Zarghi A, Pouralibaba F. Efficacy of *Elaeagnus angustifolia* topical gel in the treatment of symptomatic oral lichen planus. *J Dent Res Dent Clin Dent Prospects.* 2010;4(1):29-32.
25. Kia SJ, Shirazian S, Mansourian A, Fard LK, Ashnagar S. Comparative Efficacy of Topical Curcumin and Triamcinolone for Oral Lichen Planus: A Randomized, Controlled Clinical Trial. *Journal of Dentistry of Tehran University of Medical Sciences.* 2015;12(11):789-796.
26. Amirchaghmaghi M, Pakfetrat A, Delavarian Z, Ghala-vani H, Ghazi A. Evaluation of the Efficacy of Curcumin in the Treatment of Oral Lichen Planus: A Randomized Controlled Trial. *J Clin Diagn Res.* 2016; 10(5): ZC134–ZC137.
27. Chainani-Wu N, Madden E, Lozada-Nur F, Silverman S. High-dose curcuminoids are efficacious in the reduction in symptoms and signs of oral lichen planus. *J Am Acad Dermatol.* 2012;66(5):752-60.
28. Chainani-Wu N, Silverman S, Reingold A, Bostrom A, Mc Culloch C, Lozada-Nur F, et al. A randomized, placebo-controlled, double-blind clinical trial of curcuminoids in oral lichen planus. *Phytomedicine.* 2007;14(7):437-46.
29. Chaiyavit P, Ma N, Hiraku Y, Pinlaor S, Yongvanit P, Jintakanon D, et al. Nitrate and oxidative DNA damage in oral lichen planus in relation to human oral carcinogenesis. *Cancer Sci.* 2005;96(9):553-9.
30. Jaganathan SK, Mandal M. Antiproliferative effects of honey and of its polyphenols: a review. *J Biomed Biotechnol.* 2009;830616. doi: 10.1155/2009/830616.
31. Rao BN. Bioactive phytochemicals in Indian foods and their potential in health promotion and disease prevention. *Asia Pac J Clin Nutr.* 2003;12(1):9-22.
32. Kidd PM. Bioavailability and activity of phytosome complexes from botanical polyphenols: the silymarin, curcumin, green tea, and grape seed extracts. *Altern Med Rev.* 2009;14(3):226-46.
33. Witkin JM, Li X. Curcumin, an active constituent of the ancient medicinal herb *Curcuma longa* L.: some uses and the establishment and biological basis of medical efficacy. *CNS Neurol Disord Drug Targets.* 2013;12(4):487-97.