

# Evaluation of the Association of Sinus Mucosal Thickening with Dental and Periodontal Status Using Cone Beam Computed Tomographic Imaging

## Original Article

Shoaleh Shahidi<sup>1</sup>, Barbod Zamiri<sup>2</sup>, Roghayeh Panahi<sup>3</sup>, Farin Kiany<sup>4</sup>

<sup>1</sup> Professor, Department Biomaterial Research Center, Oral and Maxillofacial Radiology, School of Dentistry, Shiraz University of Medical Sciences, Shiraz, Iran.

<sup>2</sup> Associate Professor, Department of Oral and Maxillofacial Surgery, School of Dentistry, Shiraz University of Medical Sciences, Shiraz, Iran.

<sup>3</sup> Postgraduate Student, Department of Oral and Maxillofacial Radiology, School of Dentistry, Shiraz University of Medical Sciences, Shiraz, Iran.

<sup>4</sup> Associate Professor, Oral and Dental Disease Research Center, School of Dentistry, Shiraz University of Medical Sciences, Shiraz, Iran.

Received: Aug 20, 2016

Accepted: Sep 16, 2016

### Corresponding Author:

**Roghayeh Panahi**

#### Address:

Department of Oral and Maxillofacial Radiology, School of Dentistry, Shiraz University of Medical Sciences, Faculty of Dentistry, Ghasr e Dasht Street, Shiraz, Iran.

**Email:** [bibirsabz1@yahoo.com](mailto:bibirsabz1@yahoo.com)

**Telephone:** + 989120572510

## Abstract

**Introduction:** Cone Beam Computed Tomography (CBCT) is a relatively new three-dimensional imaging technology, which has been widely used in dental and maxillofacial imaging.

**Materials and methods:** CBCT scans of 506 maxillary sinuses of 253 individuals (39.9% male and 60.1% female) were evaluated retrospectively for assessing the relationship between sinus mucosal thickening (MT) and dental and periodontal status. Thickening >1 mm was considered pathological and was categorized by degree (2 = 1–3 mm; 3 = 3–6 mm; 4 = 6–10 mm; 5 = more than 10 mm). The statistical analysis was performed to determine the association between MT of the sinus and the dental and periodontal status.

**Results:** MT was observed in 102 patients (40.3%; mean=7.01 ± 6.07mm), of which 13.7% were second degree, 25.5% were third degree, 25.5% were fourth degree, and 35.3% were fifth degree. Periodontal disease was seen in 168 patients (66.3%), of whom 110 (65.5%) had mild disease, 44 (26.2%) had moderate disease, and 14 (8.3%) had severe disease. Ninety-seven patients (52.2%) who had MT were 2.84 times more likely to have periodontal disease, and there was a statistically significant relationship between periodontal disease and sinus MT (P=0.001). Multivariate analysis revealed an odds ratio of 14.39 for MT in the patients with periodontal disease. Bivariate and multivariate statistical analyses were used for the assessment of dental and periodontal status.

**Conclusion:** A retrospective inspection of CBCT images revealed that the prevalence of maxillary sinus MT was positively associated with periodontal disease, gender, and age. In addition, periodontal disease seems to be the most important parameter influencing mucosal thickness.

### Key words:

•Maxillary Sinus •Cone-Beam Computed Tomography •Periodontal Diseases.

## Introduction

The maxillary sinuses are air cavities connected to the nasal cavity by an ostium. A thin respiratory mucous membrane of about 1 mm thickness covers the sinuses. A healthy mucous membrane of normal thickness is not generally captured by radiography. However, infectious or allergic processes can make the membrane 10–15 times thicker, and it may be seen in radiography.<sup>(1)</sup>

Dental pathologies (periapical lesions, tumors, and cysts) are related to maxillary sinus pathologies. Radiography is often used to diagnose diseases of the maxillary sinus. It is necessary to evaluate the sinus for anatomic variabilities of bony structures and sinus pathologies before posterior maxillary surgery.<sup>(2, 3)</sup> This evaluation should focus on the verification of bone quantity and quality, the periodontal status of the adjacent dentition, the presence of sinus problems, and history of tooth pain.<sup>(4)</sup> Panoramic radiograph, Water's view, computed tomography (CT) scan, magnetic resonance imaging (MRI), and cone-beam computed tomography (CBCT) scanning can depict maxillary sinuses. The gold standard for maxillary sinus examination is CT; nevertheless, high costs and radiation exposure are limitations of CT imaging for dental purposes.<sup>(5, 6)</sup>

CBCT does not have the limitations of regular CT and is faster and safer, making it a good alternative in dental imaging. CBCT imaging has the unique ability to produce clear images of different types of tissue (soft tissue, bone); this makes it the chief imaging method used for maxillary sinus assessment. CBCT makes diagnosis easier by providing three-dimensional information, including morphology of the anatomic structures. Images of CBCT are in different sections (axial, sagittal, and coronal), which reduces the superimposition of anatomic structures and helps to improve the clinician's concept of the whole anatomical structure of the tissue.<sup>(7, 8)</sup>

Many studies around the world have evaluated the relationship between the maxillary teeth and the maxillary sinus using CBCT.<sup>(9, 10)</sup> For example, Brüllmann et al.<sup>(11)</sup> evaluated the correlation of CBCT findings in the maxillary sinus with dental diagnoses in 204 patients. They concluded that there was a significant association between periodontitis and radiological signs

of sinusitis, and basal mucosal wall thickening was more common in patients with decayed and dead teeth compared to patients with healthy teeth. In a large retrospective study, 831 patients were evaluated.<sup>(9, 10)</sup> The results showed that of the 469 sinuses with membrane thickening, 210 were adjacent to unhealthy teeth, 233 were adjacent to healthy teeth, and 26 were in edentulous maxillae. Therefore, they concluded that the prevalence of sinus membrane thickening was almost equal in association with unhealthy and healthy teeth, and the removal of unhealthy teeth decreased but did not completely resolve sinus membrane thickening.<sup>(12)</sup>

Due to the advantages of CBCT over traditional CT and the importance of associations of sinus mucosal thickening (MT) with dental and periodontal status, especially in posterior maxilla surgeries,<sup>(12)</sup> this study was designed to determine the association between mucosal thickening of the maxillary sinus and dental and periodontal status using CBCT imaging.

## Materials and Methods

The study was retrospectively performed on consecutive CBCT images of patients who were referred to our private maxillofacial radiology clinic by dentists to undergo CBCT imaging due to issues including developmental disorders, preimplant site evaluation, paranasal sinus diseases, and trauma, from March 2011 through April 2015. The study protocol was approved by the institutional review board (IRB) of Shiraz University of Medical Sciences and the approval of the Ethics Committee was received before the study commenced (registration number 8874). Inclusion criteria consisted of all consecutive CBCT scans of the bilateral maxillary sinus where gender, age, and indication for scanning had been recorded and the quality of the images were good. No patients were excluded from this consecutive series; CBCT scans of patients with developmental problems or trauma were excluded.

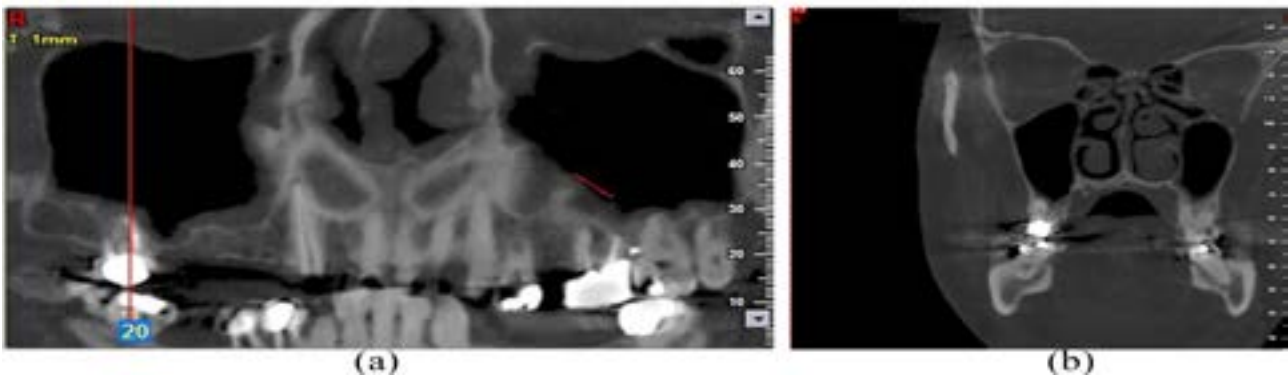
A total of 253 CBCT scans were reviewed by an oral and maxillofacial radiologist and a senior resident of oral and maxillofacial radiology who had considerable experience in CBCT interpretation regarding sinus MT and dental and periodontal status. Finally, findings of the CBCT

scans and individual factors including gender, age, and indication for scanning were recorded in a data gathering form. In order to obtain the values for the present evaluation, dental and periodontal status were defined as having periapical lesions, dental filling, root canal filling, periodontal diseases, and extracted posterior teeth. Periapical lesions were evaluated based on imaging from the coronal, tangential, and sagittal views and were defined as radiolucencies associated with the apex of the teeth (Figure 1). Periodontal disease was assessed based on imaging from the coronal, tangential, and sagittal views and was defined as alveolar bone loss around the teeth. When the alveolar crest was 2 mm under the cemento-enamel junction (CEJ), it was considered normal. For computing the amount of periodontal bone loss, the distance between the point 2 mm under the CEJ and the crest of the alveolar bone was measured at the mesial and distal sides of each tooth. In addition,

severity of periodontal disease was characterized by the amount of bone loss assessed (mild = <25% bone loss, moderate = 25–50% bone loss, severe = >50% bone loss).<sup>(13)</sup>

The presence or absence of MT in the floor of the maxillary sinus was evaluated in cross sectional, tangential, and panoramic views. In each case, the MT was measured in 6 points exactly located over the medial and distal sides of the second premolar and the first and second molar teeth from the sinus floor to the highest border of the mucosa. For each point, MT was considered to be a thickness of more than 1 mm].

Data were analyzed using SPSS ver.17 (SPSS Inc., Chicago, IL, USA). Data were first analyzed descriptively (frequencies, means, and standard deviations), and associations between variables were evaluated using the Pearson chi-square test. Binary logistic regression analysis was used to determine odds ratios (ORs). A p-value of less than 0.05 was considered significant.



**Figure 1.** Mucosal thickening in the left maxillary sinus floor associated with the periapical lesion of the first molar tooth; reconstructed panoramic view (a), coronal section (b).

## Result

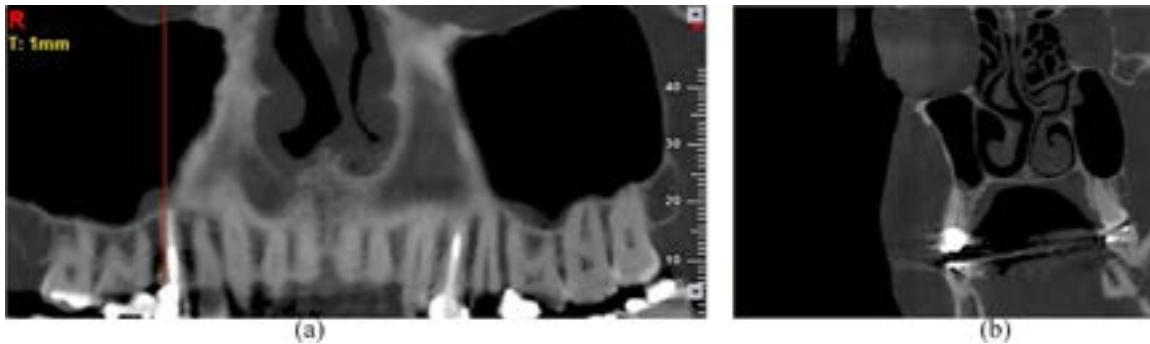
This study included the CBCT images of 506 maxillary sinuses of 253 individuals (39.9% male and 60.1% female) with the mean age of  $44.2 \pm 15.3$  (range 18–75) years. MT was found in 102 patients (40.3%), and 60 nt of MT was considered in each patient. In addition, the mean mucosal thickness was  $7.01 \pm 6.07$  (range 1–31.9) mm. The amount of MT was also classified into five groups based on a previous research performed by Phothikhun et al<sup>(14)</sup>: 1 = MT less than 1 mm; 2 = 1–3 mm; 3 = 3–6 mm; 4 = 6–10 mm; and 5 = more than 10 mm. Frequency of patients based on laterality and MT classification are shown in Table 1. The mean age of the patients with MT was significantly higher than those without MT

( $46.6 \pm 15.9$  years vs.  $42.5 \pm 14.8$  years,  $P=0.03$ ), and 58.3% of patients older than 60 years had sinus MT. According to the Pearson chi-square test results, there was a statistically significant relationship between gender and sinus MT. Sinus MT had a higher prevalence in males than in females (52.2% vs, 32.2%,  $P=0.001$ ). Furthermore, the mean sinus MT was significantly higher in males than females ( $4.1 \pm 2.3$  vs.  $1.9 \pm 1.1$ ,  $P=0.001$ ). The dental and periodontal status in relation to sinus MT was assessed by means of Pearson chi-square test (Table 2).

Periodontal disease was observed in 168 patients (66.3%), of whom 110 (65.5%) had mild disease, 44 (26.2%) had moderate disease, and 14 (8.3%) had severe periodontal disease. Ninety-seven patients (52.2%) with periodontal disease had MT,

and there was a significant association between periodontal disease and sinus MT ( $P = 0.001$ ). However, there was no significant correlation between the severity of periodontal disease and there was a significant association between periodontal disease and sinus MT ( $P = 0.001$ ). However, there was no significant correlation

between the severity of periodontal disease and sinus MT ( $P = 0.1$ ). Sinus MT was more frequently observed in relation to the site of tooth extraction ( $P = 0.005$ ). Periapical lesions and root fillings were significantly observed in the patients with sinus MT (Figure 2)



**Figure 2.** Mucosal thickening in the right maxillary sinus floor adjacent to the endodontically treated second premolar tooth; reconstructed panoramic view (a), coronal section (b).

( $P = 0.008$ ,  $P = 0.004$ , respectively); however, no significant association was observed between dental fillings and the frequency of MT ( $P = 0.1$ ). Binary logistic regression analysis showed that sinus mucosal thickness  $>1$ mm was 14.39 times more likely to be associated with periodontal disease ( $OR = 14.39$ ,  $P < 0.001$ ) and was nearly 3 times more common in males and patients aged over 60 years ( $OR = 2.84$ ,  $P = 0.001$ ,  $OR = 3.03$ ,  $P = 0.004$ , respectively). However, there was no association with other dental and periodontal statuses. Results of the regression analysis are presented in Table 3.

**Table 1.** Prevalence of sinus mucosal thickening (MT) of the study patients

MT status	Patients with MT (n=102)
<b>MT side</b>	
Left	14 (13.9%)
Right	16 (15.6%)
Bilateral	72 (70.5%)
<b>MT classification</b>	
1-3 mm	14 (13.7%)
3-6 mm	26 (25.5%)
6-10 mm	26 (25.5%)
More than 10 mm	36 (35.3%)

**Table 2.** Associations between study variables and sinus mucosal thickening

Variable	Mucosal thickening		P value
	Absent ( $<1$ mm)	Present ( $>1$ mm)	
Gender	Male	48 (47.5%)	0.032
	Female	103 (67.8%)	
Age	18-30 y	44 (69.8%)	0.1
	31-45 y	38 (54.3%)	
	46-60 y	49 (68.1%)	
	$>60$ y	20 (41.7%)	
Dental filling	Absent	72 (65.5%)	0.004
	Present	79 (55.2%)	
Root filling	Absent	127 (61.9%)	0.008
	Present	24 (42.9%)	
Periapical lesion	Absent	146 (61.9%)	0.005
	Present	5 (29.4%)	
Extracted posterior teeth	Absent	124 (64.46%)	0.001
	Present	27 (44.3%)	
Periodontal diseases	Absent	62 (92.5%)	0.001
	Present	89 (47.8%)	

**Table 3.** Multivariate analysis to determine factors associated with sinus mucosal thickening >1 mm

Variable	OR	95% CI	P value
<b>Sex</b>			
Male	2.84	1.54-5.26	0.001
<b>Age</b>			
>60 y	3.03	1.41-6.52	0.004
<b>Root filling</b>			
Present	1.58	0.77-3.24	0.2
<b>Periapical lesion</b>			
Present	1.69	0.51-5.61	0.38
<b>Extracted posterior teeth</b>			
Present	1.55	0.77-3.13	0.21
<b>Periodontal diseases</b>			
Present	14.39	5.13-39.32	<0.001

## Discussion

Anatomic structures in the mouth are seen in high resolution and more details are visible with CBCT scanning. Some studies have reported higher accuracy of CBCT scanning in comparison with CT scanning and conventional radiography in hard tissue and endodontics.<sup>(15, 16)</sup> In the present study, we attempted to clarify the possible relationship between MT of the maxillary sinus and dental and periodontal status using CBCT imaging.

In our study, 40.3% of patients were found with maxillary sinus MT. This is similar to the numbers reported by Phothikhun et al.,<sup>(14)</sup> who found MT in 42% of patients, and another study that reported a prevalence of 39.4%.<sup>(17)</sup> Both studies used CBCT imaging and defined the MT as >1 mm. In comparison, MT in 60% and 83.2% of patients were reported from two study based on computed tomography scanning.<sup>(18, 19)</sup> Moreover, an MT prevalence of 50% was reported from a study based on MRI.<sup>(20)</sup> This variation could originate from the differences in race or age as well as the different diagnostic techniques used. The normal thickness of the maxillary sinus mucosa is about 1 mm and a mucosal thickness of >1 mm was considered as evidence of MT<sup>(14)</sup>. CBCT studies have reported a prevalence between 37% and 62% using MT thresholds of >1mm<sup>(21)</sup>, >2mm<sup>(22)</sup>, and >3mm.<sup>(23)</sup> The demarcation of normal mucosal thickness is varied throughout the literature, so the prevalence of the MT can change in accordance with the definition. Soikkonen and

Ainamo found a prevalence of 70% for sinus MT.<sup>(1)</sup> They did not consider a baseline for maxillary sinus MT; their theory was the existence of diffuse radio-opacity along the maxillary sinus walls. In another study, Vallo et al.<sup>(24)</sup> reported the existence of MT when it was a 3–6 mm thick-radiopaque band along the wall of the sinus and found MT in 37% of patients.

In addition, Janner et al.<sup>(22)</sup> and Goller-Bulut et al.<sup>(25)</sup> respectively reported a prevalence of 37% and 33.8% for MT when it was defined as more than 2 mm. Therefore, these differences in the definition of MT may contribute to variations in reports of MT prevalence.

After dental decay, periodontal disease is the second most common dental disease in the world. The prevalence of this disease is about 30%–50% of the population in the United States, although the severe forms account for approximately 10%.<sup>(26)</sup> In the present study, periodontal disease was found in 66.3% of patients. This is higher than other international figures; however most of those studies (65.5%) looked only at mild periodontal disease, and only 8.3% of patients in our study presented with severe periodontal disease. Undoubtedly, our finding is difficult to interpret and could result from the small number of patients; hence, we need multi-center studies in a greater population to know the exact prevalence of periodontal disease in our society. According to the results of our study, periodontal disease is significantly associated with MT (P=0.001). Moreover, multivariate analysis revealed an OR of 14.39 for MT in patients with periodontal disease. Consistent with our results, Phothikhun et al.<sup>(14)</sup> reported that periodontal disease was significantly associated with MT, especially in severe periodontal disease (OR=3.02, P<0.001). Odds ratios between 2.5 and 31.8 for MT in relation to various degrees of periodontal disease were reported in previous studies<sup>(11, 14, 24, 27)</sup>, whereas this relationship was not significant in other studies.<sup>(22, 28)</sup> Perhaps one of the reasons for this inconsistency is differences in the definitions of MT and periodontal disease and their severity.

There was a significant correlation between MT and age (P=0.03), and the mean age of the patients with MT was about four years higher than patients without MT. Furthermore, multivariate analysis demonstrated an OR of 3.03 for MT in

patients older than 60 years. This is similar to that reported by Yu Lu et al.,<sup>(9)</sup> who showed that patients older than 60 years of age were the most likely to present with MT.

In our study, a higher prevalence of MT was observed among males ( $P=0.001$ ), and the mean MT in males was significantly higher than in females ( $4.1 \pm 2.3$  Vs  $1.9 \pm 1.1$ ,  $P=0.001$ ). Furthermore, MT was nearly three times more common in males ( $OR = 2.83$ ). This was concordant with the results from other studies on the prevalence of MT.<sup>(17, 22, 25, 28)</sup>

Although bivariate analyses in our study demonstrated a significant association between MT and some dental and periodontal statuses, including root filling, periapical lesion, and extracted posterior teeth, these effects were not seen in the multivariate analysis. Previous studies have reported different effects of these factors. However, according to previous studies, it is worthwhile to note that periodontal disease, age, and gender seem to be the most important parameters influencing mucosal thickness.

There were a number of limiting factors diminishing the impact of the results, of which the patient population being restricted to a single institution is the most important. Thus, our results may not be representative of patients with this condition in Iran. In addition, only radiographic mucosal changes were evaluated, and there was a lack of clinical examination and accurate

history about the dental and periodontal status and sinus problems in the patients. It seems that further multi-center prospective studies correlating clinical and radiographic findings are required to confirm these results.

## Conclusion

Our findings revealed that patients with periodontal disease and aged more than 60 years were respectively 14.39 and 3.03 times more likely to be associated with MT. In addition, mucosal thickness in males was 2.84 times higher than in females.

## Conflict of Interest

The authors declare no conflict of interests.

## Source of Funding

This study was an approved research project in Shiraz University of Medical Sciences and financed and supported by Research Vice-chancellor of that university (grant No. 8874).

## Conclusion

The authors thank the Vice Chancellery of Shiraz University of Medical Sciences for supporting this research. The authors would also thank Dr. Abdolaziz Haghnegahdar for his suggestions regarding the improvement of this manuscript. This article was extracted from the thesis written by Dr. Roghayeh Panahi for the degree of oral and maxillofacial radiology specialty.

## References

1. Soikkonen K, Ainamo A. Radiographic maxillary sinus findings in the elderly. *Oral surgery, oral medicine, oral pathology, oral radiology, and endodontics*. 1995;80(4):487-91.
2. Rege IC, Sousa TO, Leles CR, Mendonca EF. Occurrence of maxillary sinus abnormalities detected by cone beam CT in asymptomatic patients. *BMC oral health*. 2012;12:30.
3. Rysz M, Bakon L. Maxillary sinus anatomy variation and nasal cavity width: structural computed tomography imaging. *Folia morphologica*. 2009; 68(4):260-4.
4. Timmenga NM, Raghoobar GM, Boering G, van Weissenbruch R. Maxillary sinus function after sinus lifts for the insertion of dental implants. *J Oral Maxillofac Surg*. 1997;55(9):936-9;discussion 940.
5. Anzai Y, Yueh B. Imaging evaluation of sinusitis: diagnostic performance and impact on health outcome. *Neuroimaging Clin N Am*. 2003;13(2):251-63, xi.
6. Mafee MF, Tran BH, Chapa AR. Imaging of rhinosinusitis and its complications: plain film, CT, and MRI. *Clin Rev Allergy Immunol*. 2006;30(3):165-86.
7. Cotton TP, Geisler TM, Holden DT, Schwartz SA, Schindler WG. Endodontic applications of cone-beam volumetric tomography. *J Endod*. 2007;33(9):1121-32. Epub 2007 Jul 19.
8. Scarfe WC, Levin MD, Gane D, Farman AG. Use of cone beam computed tomography in endodontics. *Int J Dent*. 2010 Mar 31. doi: 10.1155/2009/634567
9. Lu Y, Liu Z, Zhang L, Zhou X, Zheng Q, Duan X, et al. Associations between maxillary sinus mucosal thickening and apical periodontitis using cone-beam computed tomography scanning: a retrospective study. *J Endod*. 2012;38(8):1069-74. doi: 10.1016/j.joen.2012.04.027. Epub 2012 Jun 20.
10. Kilic C, Kamburoglu K, Yuksel SP, Ozen T. An Assessment of the Relationship between the Maxillary Sinus Floor and the Maxillary Posterior Teeth Root Tips Using Dental Cone-beam Computerized Tomography. *Eur J Dent*. 2010;

4(4):462-7.

- 11.Brullmann DD, Schmidtmann I, Hornstein S, Schulze RK. Correlation of cone beam computed tomography (CBCT) findings in the maxillary sinus with dental diagnoses: a retrospective cross-sectional study. *Clin Oral Investig*. 2012;16(4):1023-9. doi: 10.1007/s00784-011-0620-1. Epub 2011 Oct 4.
- 12.Block MS, Dastoury K. Prevalence of sinus membrane thickening and association with unhealthy teeth: a retrospective review of 831 consecutive patients with 1,662 cone-beam scans. *J Oral Maxillofac Surg*. 2014;72(12):2454-60. doi: 10.1016/j.joms.2014.06.442. Epub 2014 Jun 27.
- 13.Scarfe WC, Farman AG, Sukovic P. Clinical applications of cone-beam computed tomography in dental practice. *J Can Dent Assoc*. 2006 Feb;72(1):75-80.
- 14.Phothikhun S, Suphanantachat S, Chuenchompoonut V, Nisapakultorn K. Cone-beam computed tomographic evidence of the association between periodontal bone loss and mucosal thickening of the maxillary sinus. *J Periodontol*. 2012;83(5):557-64. doi: 10.1902/jop.2011.110376. Epub 2011 Sep 12.
- 15.Liang X, Jacobs R, Hassan B, Li L, Pauwels R, Corpas L, et al. A comparative evaluation of Cone Beam Computed Tomography (CBCT) and Multi-Slice CT (MSCT) Part I. On subjective image quality. *Eur J Radiol*. 2010;75(2):265-9. doi: 10.1016/j.ejrad.2009.03.042. Epub 2009 May 1.
- 16.Estrela C, Bueno MR, Leles CR, Azevedo B, Azevedo JR. Accuracy of cone beam computed tomography and panoramic and periapical radiography for detection of apical periodontitis. *J Endod*. 2008;34(3):273-9. doi: 10.1016/j.joen.2007.11.023. Epub 2008 Jan 31
- 17.Sheikhi M, Pozve NJ, Khorrami L. Using cone beam computed tomography to detect the relationship between the periodontal bone loss and mucosal thickening of the maxillary sinus. *Dent Res J (Isfahan)*. 2014;11(4):495-501.
- 18.Hahnel S, Ertl-Wagner B, Tasman AJ, Forsting M, Jansen O. Relative value of MR imaging as compared with CT in the diagnosis of inflammatory paranasal sinus disease. *Radiology*. 1999;210(1):171-6.
- 19.Bolger WE, Butzin CA, Parsons DS. Paranasal sinus bony anatomic variations and mucosal abnormalities: CT analysis for endoscopic sinus surgery. *Laryngoscope*. 1991;101(1 Pt 1):56-64.
- 20.Kristo A, Alho OP, Luotonen J, Koivunen P, Tervonen O, Uhari M. Cross-sectional survey of paranasal sinus magnetic resonance imaging findings in schoolchildren. *Acta Paediatr*. 2003;92(1):34-6.
- 21.Pazera P, Bornstein MM, Pazera A, Sendi P, Katsaros C. Incidental maxillary sinus findings in orthodontic patients: a radiographic analysis using cone-beam computed tomography (CBCT). *Orthod Craniofac Res*. 2011;14(1):17-24. doi: 10.1111/j.1601-6343.2010.01502.x. Epub 2010 Nov 22.
- 22.Janner SF, Caversaccio MD, Dubach P, Sendi P, Buser D, Bornstein MM. Characteristics and dimensions of the Schneiderian membrane: a radiographic analysis using cone beam computed tomography in patients referred for dental implant surgery in the posterior maxilla. *Clin Oral Implants Res*. 2011;22(12):1446-53. doi: 10.1111/j.1600-0501.2010.02140.x. Epub 2011 Mar 23.
- 23.Lana JP, Carneiro PM, Machado Vde C, de Souza PE, Manzi FR, Horta MC. Anatomic variations and lesions of the maxillary sinus detected in cone beam computed tomography for dental implants. *Clin Oral Implants Res*. 2012;23(12):1398-403. doi: 10.1111/j.1600-0501.2011.02321.x. Epub 2011 Oct 3.
- 24.Vallo J, Suominen-Taipale L, Huumonen S, Soikkonen K, Norblad A. Prevalence of mucosal abnormalities of the maxillary sinus and their relationship to dental disease in panoramic radiography: results from the Health 2000 Health Examination Survey. *Oral Surg Oral Med Oral Pathol Oral Radiol Endod*. 2010;109(3):e80-7. doi: 10.1016/j.tripleo.2009.10.031.
- 25.Goller-Bulut D, Sekerci AE, Kose E, Sisman Y. Cone beam computed tomographic analysis of maxillary premolars and molars to detect the relationship between periapical and marginal bone loss and mucosal thickness of maxillary sinus. *Med Oral Patol Oral Cir Bucal*. 2015;20(5):e572-9.
- 26.Shao MY, Huang P, Cheng R, Hu T. Interleukin-6 polymorphisms modify the risk of periodontitis: a systematic review and meta-analysis. *J J Zhejiang Univ Sci B*. 2009;10(12):920-7. doi: 10.1631/jzus.B0920279.
- 27.Abrahams JJ, Glassberg RM. Dental disease: a frequently unrecognized cause of maxillary sinus abnormalities? *AJR Am J Roentgenol*. 1996;166(5):1219-23.
- 28.Shanbhag S, Karnik P, Shirke P, Shanbhag V. Association between periapical lesions and maxillary sinus mucosal thickening: a retrospective cone-beam computed tomographic study. *J Endod*. 2013;39(7):853-7. doi: 10.1016/j.joen.2013.04.010. Epub 2013 May 16.