

A Comparative Study of CT Scan and MRI in The Assessment of Squamous Cell Carcinoma of The Oral Cavity and Its Cervical Lymph Node Metastasis

Original Article

Maryam Koopaie¹, Abbas Karimi²

¹ Residential student, Department of Oral Medicine and Diagnostic Sciences, Shahed Dental School, Tehran, Iran

² Associate Professor, Oral and Maxillofacial Surgery Department, Faculty of Dentistry, Tehran University of Medical Science, Tehran, Iran

Received: Apr 6, 2014
Accepted: Jun 17, 2014

Corresponding Author:

Maryam Koopaie

Address: Department of Oral Medicine, Shahed Dental School, Enghelab Avenue, Vesal Street, Italy Street, Number 39. Tehran, Iran.

Telephone: +98-913-3216154

Fax: +98-21-88967618

E-mail: maria_koopaie@yahoo.com

Abstract

Introduction: Squamous Cell Carcinoma (SCC) is the most common head and neck malignancy. To decrease the side effects of treatment and mortality from disease relapse, careful staging for the proper treatment plan is necessary. The main purpose of this prospective study is to compare the diagnostic value of Computed Tomography (CT) and Magnetic Resonance Imaging (MRI) in oral SCC and its lymph node metastasis in order to represent the proper treatment plan.

Materials and Methods: 30 patients (19 men and 11 women) with oral SCC underwent CT and MRI before surgery. Imaging modalities of each study were evaluated individually for tumor size, bone invasion, muscle infiltration. These evaluations were done by two radiologists and an oral-maxillofacial surgeon and verified with histopathology findings as gold standard. The results of the radiological assessment were correlated with the intraoperative and histopathological findings in all patients.

Results: CT and MRI have equal potential for detecting the tumor size, perineural invasion and nodal metastasis. The sensitivity and specificity were 50%, 90% for CT in the detection of bone invasion and 90%, 85% for MRI. The sensitivity and specificity were 66.66%, 90.47% for CT in detection of muscle infiltration and 55.55%, 90.47% for MRI.

Conclusion: The comparison of these modalities showed no statistically significant difference between CT and MRI. Regarding bone infiltration the sensitivity of CT scan was higher than of MRI, but regarding muscle invasion the specificity of MRI was higher than of CT scan.

Key words: • Carcinoma • Squamous Cell • Lymph Nodes • Neoplasm Metastasis • Magnetic Resonance Imaging

Introduction

Carcinomas of the oral cavity account for 3-5% of all malignancies worldwide and show an increasing incidence.^[1] Squamous Cell Carcinomas (SCC) is the most frequent of all head and neck malignancies. In Iran, SCC is the 13th most frequent malignancy in men and 17th in women.^[2] The mean age of patients with SCC is 57. Detailed staging is necessary for treatment planning to optimize patient management and to reduce postoperative morbidity, and tumor recurrence mortality. The therapeutic approach and prognosis of patients with SCC are substantially influenced by local tumor extension, tumor size and lymph node infiltration.⁽³⁻⁴⁾

The clinical examination of primary tumor size, its local muscle and mucosal spread, bone invasion as well as cervical lymph nodes involvement are insufficient because it often underestimates the extent of tumor specially in case of more advanced disease stages owing to the tendency of these lesions to spread submucosally.⁽⁵⁾ Additionally, a metastasis involvement of lymph nodes that measuring less than 10mm is well known and being straightforwardly misinterpreted as a regular cervical lymph node status. Therefore, cross sectional imaging methods such as CT and MRI are mandatory for exact therapeutic planning.⁽⁶⁾

Concerning the high cost of these imaging modalities, defining correct staging and evaluation of lymph node metastasis, and appropriate treatment to reduce recurrence and mortality are necessary. The aim of this study was to assess and compare the precision of CT and MRI in staging of primary SCC of the oral cavity.

Materials and Methods

In the prospective study, 30 patients (19 males, 11 females), aged 25 to 77 years (mean 57 ± 10.3) who referred to the craniofacial surgery department of either

Shariati hospital or the faculty of dentistry of Tehran University of Medical Sciences during two years (2010-2012) underwent surgery for a primary SCC of the oral cavity.

Before administration of CT and MRI for each patient, the research and its goals for each patient were explained. All patients signed the consent form for cooperating in the project. In this prospective study, the authors obtained both CT and MRI for each patient, which by current publishing standards require ethics approval.

These patients were examined with CT and MRI before surgery. Each patient underwent a preoperative MRI using a 3.0 Tesla superconductive MRI scanner (General Electric Vectra, IGF Medical, Milwaukee, Wisconsin, USA) focusing on the three-dimensional time-of-flight (3D-TOF) sequence. CT Scan Imaging was performed by GE HiSPEED NX/I Pro CT device. These images were taken in one radiological center and by one operator. In this way, we could omit the bias that originates from different machines and operators.

All CT and MR images were evaluated by two experienced radiologists and an oral and maxillofacial surgeon on the basis of two standard questionnaires in a blind fashion. Two questionnaires were used to collect data from CT scan and MRI results by one of the radiologists. Another radiologist evaluated some images in a blind manner to confirm the reliability of the first radiologist's reports. Interpretation of each radiologist was compared with the results of the gold standard (histopathology and surgical procedure) for each patient. Data from clinical and histopathological examination of the questionnaires were entered by the surgeon. The results of the CT scan were compared separately with MRI, clinical and histopathological finding by Paired t-test (the quantitative data). The same procedure was performed on MRI. McNemar test was

used for qualitative data analysis. The accuracy of CT scan and MRI was obtained separately by comparing the mean of McNemar and Paired t-test data with histopathology.

In each questionnaire the following items were determined: patient's name, sex, age, occupation, tobacco consumption, alcohol consumption, site of primary tumor, size of tumor, depth of the tumor, TNM classification, muscle invasion, neural invasion, lymph node involvement, size of lymph node, shape of lymph node, site of lymph node, the number of lymph nodes, presence of fatty core, presence of central necrosis, nodal calcification, margins of lymph nodes, and extra capsular spread.⁽⁷⁾

The results of the radiological assessment were compared with the histopathological and intraoperative findings. Sensitivity, specificity, accuracy, positive predictive value (PPV) and negative predictive value (NPV) were calculated for the depiction of the primary tumor, the local tumor infiltration and cervical lymph node involvement.

Due to the fact that the confidence intervals of specificity, sensitivity and accuracy of both imaging modalities were overlapping, further statistical tests, for example t-test for paired samples were used. For analyzing the data, SPSS V16.0 software was employed. First, the number and percentage of each of factors were determined separately for clinic, histopathology, MRI and CT scan. Then we compared CT scan results with MRI results, then clinic and finally histopathology by paired t-test and also we used this method for MRI. For analyzing the qualitative data we used McNemar test.

Results

The minimum age of the patients was 25 years; maximum age 77 years and the mean age was 57 years. Males constituted 63.3% of the patients and the rest were females. The frequency of tumors in the cheek was 13.3% and 10% in the floor of mouth,

retromolar pad 13.3%, the hard palate 6.7%, the mandibular gingiva 16.7%, the maxillary gingiva 10%, tongue 30%. Tobacco and its products were not used by 40% of the patients. The alcohol consumption in patients was 23.3%.

Regarding P value=0.56, there is no difference between CT scan and MRI in detecting for tumor size. CT scan and MRI have equal accuracy in detecting the tumor size and look like the results of histopathology but in detecting the tumor size, clinic is different from histopathology. In CT scan results, the mean size of lymph nodes is 16.79 mm and in MRI scan, it is 16.64 mm. The difference between them is not statistically significant (Figure 1).

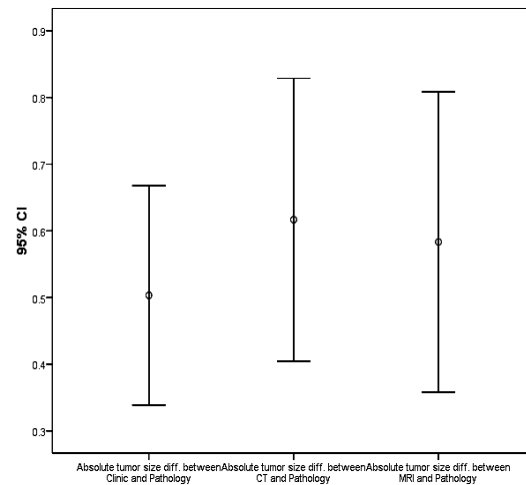


Figure 1: Comparison the tumor size by MRI, CT scan and clinic with pathology by Paired t-test

The number of lymph nodes detected by CT and MRI was equal (n=14). In detection of lymph node metastasis and shape of lymph nodes, no statistically difference could be calculated. (p value=1). Furthermore, in the detection of extra capsular spread and central necrosis of lymph nodes no statistically significant difference was found. The tumor size comparison with three methods was shown in Figure 2. The horizontal axis is the patient number sorted

according to the pathology tumor size and the vertical axis represents the tumor size in millimeter (mm).

Regarding bone invasion, the specificity of MRI was equal to CT scan (85%), but the sensitivity of MRI was higher than that of CT scan (90.0% versus 50.0%) P-Value=0.

0125. Regarding muscle infiltration the sensitivity of CT scan was higher than that of MRI (66.66% versus 55.55%). (Table1) Then Negative predictive Value (NPV) and Positive predictive Value (PPV) are noted in table 2.

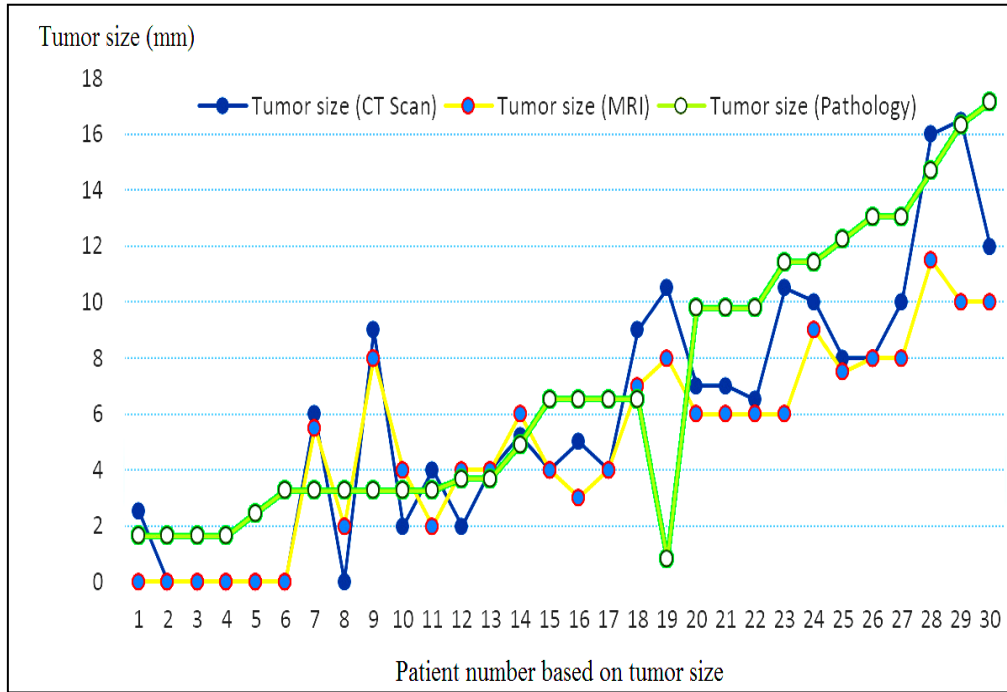


Figure 2. Comparison the tumor size by MRI Scan, in bone invasion muscle infiltration. CT scan and pathology in 30 patients

Table 1. Specificity and Sensitivity of MRI and CT scan in bone invasion muscle infiltration.

	Muscle Infiltration		Bone Invasion	
	Sensitivity	Specificity	Sensitivity	Specificity
CT scan	66.66%	90.47%	50.00%	85.00%
MRI	55.55%	90.47%	90.00%	85.00%

Table 2. Positive predictive Value (PPV) and Negative predictive Value (NPV) of MRI and CT scan

	Muscle Infiltration		Bone Invasion	
	Positive predictive Value	Negative predictive Value	Positive predictive Value	Negative predictive Value
CT scan	75.00%	86.36%	62.50%	77.20%
MRI	71.43%	82.61%	75.00%	94.40%

Discussion

Head and neck carcinomas constitute approximately 5% of all malignancies worldwide, and the incidence of tumors of the head and neck is increasing. The great majority of these tumors are SCC, which account for about 95% of all head and neck tumors.⁽⁸⁾ There is an increased frequency of carcinoma in smokers and patients with a history of excessive alcohol use. Mukherji et al. reported similar values for sensitivity (96%), specificity (87%), positive predictive value (89%) and negative predictive value (95%) for the detection of bone invasion in CT scan.⁽⁹⁾ Researchers have also noted the association of SCC of the oral mucosa and the chewing of betel quid.⁽¹⁰⁾

MRI has advantage of no use of X-ray but is more expensive than CT scan and is not suitable for patients that have claustrophobia. So, for patients that do not have these problems, it would be better to prescribe MRI. In this survey, we had limited patients. Because in cases of SCC clinicians prescribe CT or MRI not both of them, so we were not able to include many patients in the study. Therefore, one suggestion would be to use more cases in the following surveys.

The critical determinant of the utility of an imaging modality for oral cavity SCC is its ability to detect the presence or absence of metastasis.

This information has the potential to alter the treatment plan and patient morbidity.⁽¹¹⁾ At present, neck dissection with histological

examination is the most reliable staging procedure that provides important prognostic information. However, it involves the resection of a large amount of normal tissue from the neck. Hence, the identification of the best imaging modality is critical for staging of SCC.⁽¹²⁾

CT and MR remain the methods of choice for evaluation of the primary tumor in patients with head and neck cancer because of their better anatomic resolution.⁽¹³⁾ However, it is often difficult to differentiate metastatic from non-metastatic reactive nodes from CT and MR imaging, because the diagnosis of metastatic nodes is mainly based on measurement of nodal size. There have been many different size criteria for metastatic nodes with CT and MR imaging.⁽¹⁴⁾ Some authors consider any node greater than 10 mm as abnormal.⁽¹⁵⁾ Whereas other investigators give different values according to the location of lymph nodes.⁽¹⁶⁻¹⁷⁾ A lymph node was considered metastatic type when it is greater than 10 mm in maximum diameter.

Other criteria used in the interpretation of CT and MR for staging lymph nodes include the presence of central necrosis, indistinct nodal margins, and more than one lymph node specially conglomerated.⁽¹⁸⁻¹⁹⁾ However, it is often difficult to distinguish reactive lymph node from metastatic disease using these criteria: for example, the percentage of central nodal necrosis is much reduced with smaller nodes.^(15, 20)

No significant improvement in diagnostic accuracy was achieved with an addition of

information on central necrosis to the information on size of lymph nodes by Curtin et al. [15] In this study, MRI potential for diagnosis of central necrosis is equal to CT.

CT and MR imaging are routine imaging modalities for pre-operative tumor staging of oral SCC. However, in the literature the value, significance and domain of these two imaging modalities in primary staging have controversially been discussed and there

only exist very few studies comparing these two modalities. Focusing on the delineation of the primary tumor, tissue infiltration and cervical lymph node involvement, CT scan and MRI have equal potency in detecting the tumor size, lymph node metastasis and the shape of lymph nodes. The final conclusion is that CT scan and MRI have equal potential in the staging of SCC in T-stage and N-stage.

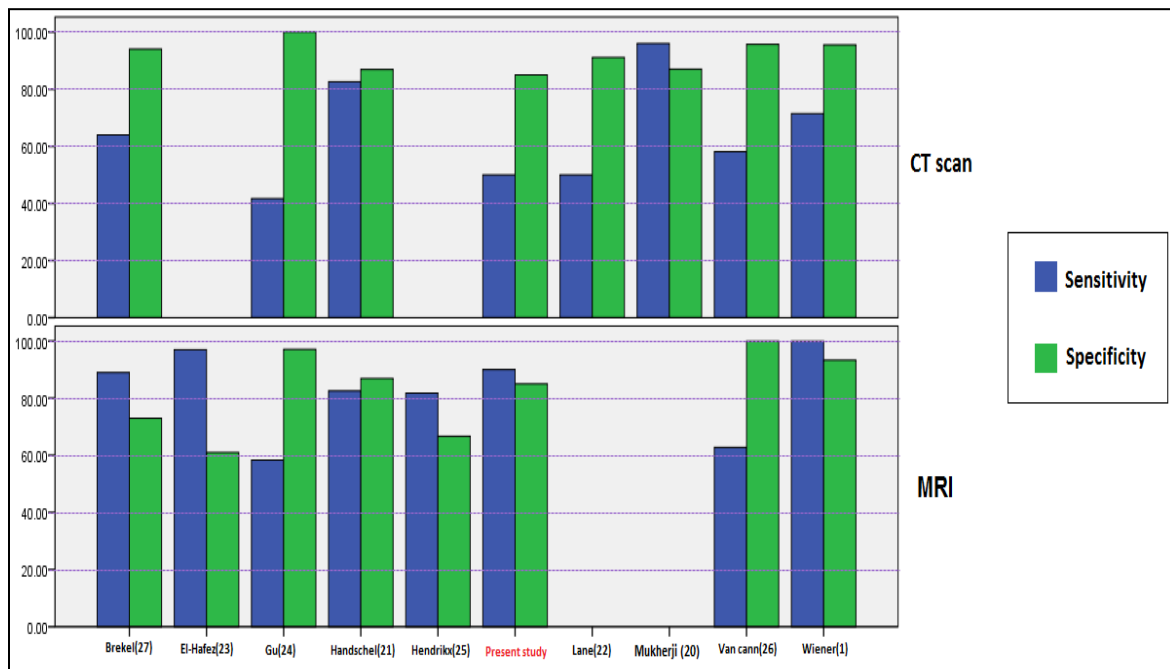


Figure 2. Comparison of bone involvement detection by CT scan and MRI in different studies

Handschel et al. indicated that the sensitivity and specificity of CT scan in detecting bone involvement of oral squamous cell carcinomas were 82.6%, 86.9% and Positive predictive value and Negative predictive value were 82.6%, 86.9% respectively.⁽²¹⁾ There were an acceptable agreement between the result of research of Handschel et al.⁽²¹⁾ and the present study. In our study and study of Handschel et al.⁽²¹⁾ The sensi-

tivity was higher than specificity and the Positive predictive value was higher than the negative predictive value too. But sensitivity, specificity, positive predictive value and negative predictive value were less than in the Handschel et al.⁽²¹⁾ It is possibly due to lack of sufficient data about patient selection, the time transurred of imaging tests and histopathological verification. Lane et al.

reported the sensitivity of CT for bone involvement in RMT cancers was 50%, with a negative predictive value of 61.1%. The positive predictive value was 91.1%.⁽²²⁾ These findings were similar to the result of the present study except the positive predictive value. This could be due to that lane et al. just studied mandibular invasion of SCC in

retromolar trigone. In Wiener et al's study sensitivity, specificity, Positive predictive value and Negative predictive value of bone involvement of CT scan were 71.4%, 95.5%, 71.2%, 95.5% respectively.⁽¹⁾ The comparison of bone involvement detection by CT scan and MRI in different studies to the present study was shown in figure 3.

Table 3. Review authors' results according to imaging test.

		muscle infiltration		bone invasion		muscle infiltration		bone invasion	
		Sensitivity	Specificity	Sensitivity	Specificity	PPV*	NPV**	PPV*	NPV**
Present study	CT scan	66.66%	90.47%	50.00%	85.00%	75.00%	86.36%	62.50%	77.20%
	MRI	55.55%	90.47%	90.00%	85.00%	71.43%	82.61%	75.00%	94.40%
Mukherji et al. [9]	CT scan	-	-	96%	87%	-	-	89%	95%
	MRI	-	-	-	-	-	-	-	-
Handschel et al.[21]	CT scan	-	-	82.6%	86.9%	-	-	82.6%	86.9%
	MRI	-	-	-	-	-	-	-	-
Lane et al.[22]	CT scan	-	-	50%	-	-	-	91.1%	61.1%
	MRI	-	-	-	-	-	-	-	-
Wiener et al.[1]	CT scan	72.7%	61%	71.4%	95.5%	-	-	71.2%	95.5%
	MRI	81.8%	63.4%	100%	93.3%	-	-	69.9%	100%
El-Hafez et al.[23]	CT scan	-	-	-	-	-	-	-	-
	MRI	-	-	97%	61%	-	-	55%	98%
Gu et al.[24]	CT scan	-	-	41.7%	100%	-	-	-	-
	MRI	58.3%	97.1%	-	-	-	-	-	-
Hendrikx et al.[25]	CT scan	-	-	-	-	-	-	-	-
	MRI	81.8%	66.7%	-	-	-	-	-	-
Van cann et al. [26]	CT scan	-	-	58.1%	95.7%	-	-	-	-
	MRI	-	-	62.8%	-	-	-	-	-
Brekel et al.[27]	CT scan	-	-	58.1%	95.7%	-	-	-	-
	MRI	-	-	62.8%	-	-	-	-	-

* Positive predictive Value

**Negative predictive Value

Conclusion

CT scan and MRI are nearly similar in the detection of tumor size and similar to the pathology results. But the clinical result is different from pathology and CT scan results prominently. However, positive results obtained with this modality cannot always be considered true positive. In this study, MRI was superior to CT in evaluating bone in-

volvement. MRI showed a higher sensitivity, but equal specificity compared with CT.

The CT was a trend towards a better detection rather than MRI in detection of muscle infiltration. Beside MRI in the detection of bone invasion is a more sensitive tool and would be preferred to CT.

References

1. Wiener, E., et al., Comparison of 16-slice MSCT and MRI in the assessment of squamous cell carcinoma of the oral cavity. *European journal of radiology*, 2006. 58(1): p. 113-118.
2. Sargeran, K., Oral Cancer in Tehran, Iran: An approach for understanding disease burden, in Department of Oral Public Health, Institute of Dentistry, Faculty of Medicine. 2008, University of Helsinki: Helsinki. p. 75.
3. Sham, J.S. and D. Choy, Prognostic factors of nasopharyngeal carcinoma: a review of 759 patients. *The British journal of radiology*, 1990. 63(745): p. 51-58.
4. Snow, G., et al., Prognostic factors of neck node metastasis. *Clinical Otolaryngology & Allied Sciences*, 1982. 7(3): p. 185-192.
5. Mukherji, S.K., J. Castelijns, and M. Castillo. Squamous cell carcinoma of the oropharynx and oral cavity: how imaging makes a difference. in *Seminars in Ultrasound, CT and MRI*. United States.1998: Elsevier.
6. Lenz, M., et al., Oropharynx, oral cavity, floor of the mouth: CT and MRI. *European journal of radiology*, 2000. 33(3): p. 203-215.
7. Joo, Y., et al., Extracapsular spread and FDG PET/CT correlations in oral squamous cell carcinoma. *International journal of oral and maxillofacial surgery*, 2013. 42(2): p. 158-163.
8. Rajesh, A., et al., Can magnetic resonance imaging replace single photon computed tomography and computed tomography in detecting bony invasion in patients with oral squamous cell carcinoma? *British Journal of Oral and Maxillofacial Surgery*, 2008. 46(1): p. 11-14.
9. Mukherji, S.K., et al., CT detection of mandibular invasion by squamous cell carcinoma of the oral cavity. *American journal of roentgenology*, 2001. 177(1): p. 237-243.
10. Chen, P.C.-H., et al., Risk of oral nonmalignant lesions associated with human papillomavirus infection, betel quid chewing, and cigarette smoking in Taiwan: an integrated molecular and epidemiologic study. *Archives of pathology & laboratory medicine*, 2006. 130(1): p. 57-61.
11. Ng, S.-H., et al., 18F-FDG PET and CT/MRI in oral cavity squamous cell carcinoma: a prospective study of 124 patients with histologic correlation. *Journal of Nuclear Medicine*, 2005. 46(7): p. 1136-1143.
12. Coche, E., T. Duprez, and M. Lonneux, Imaging the lymph nodes: CT, MRI, and PET, in *Clinical Target Volumes in Conformal and Intensity Modulated Radiation Therapy*. 2004, United States. Springer. p. 37-67.
13. Krabbe, C., et al., Performance of ¹⁸F-FDG PET/contrast-enhanced CT in the staging of squamous cell carcinoma of the oral cavity and oropharynx. *International journal of oral and maxillofacial surgery*, 2011. 40(11): p. 1263-1270.
14. Steinkamp, H.J., et al., Enlarged cervical lymph nodes at helical CT. *Radiology*, 1994. 191(3): p. 795-798.
15. Curtin, H.D., et al., Comparison of CT and MR imaging in staging of neck metastases. *Radiology*, 1998. 207(1): p. 123-130.
16. Som, P.M., Detection of metastasis in cervical lymph nodes: CT and MR criteria and differential diagnosis. *AJR. American journal of roentgenology*, 1992. 158(5): p. 961-969.
17. van der Lee, J.H., et al., Forced use of the upper extremity in chronic stroke patients results from a single-blind randomized clinical trial. *Stroke*, 1999. 30(11): p. 2369-2375.
18. Snow, G., et al., Management of cervical lymph nodes in patients with head and neck cancer. *European archives of oto-rhino-laryngology*, 1992. 249(4): p. 187-194.
19. Don, D.M., et al., Evaluation of cervical lymph node metastases in squamous cell carcinoma of the head and neck. *The Laryngoscope*, 1995. 105(7): p. 669-674.
20. King, A.D., et al., Necrosis in Metastatic Neck Nodes: Diagnostic Accuracy of CT, MR Imaging, and US 1. *Radiology*, 2004. 230(3): p. 720-726.
21. Handschel, J., et al., CT-scan is a valuable tool to detect mandibular involvement in oral cancer patients. *Oral oncology*, 2012. 48(4): p. 361-366.
22. Lane, A.P., et al., Use of computed tomography in the assessment of mandibular invasion in carcinoma of the retromolar trigone. *Otolaryngology--Head and Neck Surgery*, 2000. 122(5): p. 673-677.

23. Abd El-Hafez, Y.G., et al., Comparison of PET/CT and MRI for the detection of bone marrow invasion in patients with squamous cell carcinoma of the oral cavity. *Oral oncology*, 2011. 47(4): p. 288-295.
24. Gu, D.H., et al., CT, MR, 18F-FDG PET/CT, and their combined use for the assessment of mandibular invasion by squamous cell carcinomas of the oral cavity. *Acta Radiologica*, 2010. 51(10): p. 1111-1119.
25. Hendrikx, A., et al., Cone-beam CT in the assessment of mandibular invasion by oral squamous cell carcinoma: results of the preliminary study. *International journal of oral and maxillofacial surgery*, 2010. 39(5): p. 436-439.
26. Van Cann, E., et al., Assessment of mandibular invasion of squamous cell carcinoma by various modes of imaging: constructing a diagnostic algorithm. *International journal of oral and maxillofacial surgery*, 2008. 37(6): p. 535-541.
27. Van den Brekel, M., et al., Assessment of tumour invasion into the mandible: the value of different imaging techniques. *European radiology*, 1998. 8(9): p. 1552-1557.