

# Dentin Dysplasia Type I with Hypomature Amelogenesis Imperfecta in an 18-year-old Girl

## Case Report

Ehsan Azma<sup>1</sup>, Seyed Javad Kia<sup>2</sup>,  
Somayeh Nemati<sup>3</sup>

<sup>1,2</sup>Assistant Professor, Department of Oral Medicine,  
Guilan University of Medical Sciences, Dental  
School, Rasht, Iran

<sup>3</sup>Assistant Professor, Department of Maxillofacial  
Radiology, Guilan University of Medical Sciences,  
Dental Faculty, Rasht, Iran

Received: Jun16, 2013

Accepted: Nov11, 2013

### **Corresponding Author:**

**Seyed Javad Kia, DDS, MS**

**Address:** Department of Oral Medicine, Guilan  
University of Medical Sciences, Dental School, Imam  
Street, Opposite Pardis Hotel, Rasht, Iran

**Telephone:** +98-131-3263622

**Fax:** +98-131-3263623

**E-mail:** [Djavadkia@yahoo.com](mailto:Djavadkia@yahoo.com)

## **Abstract**

**Introduction:** Dentin dysplasia is a rare autosomal dominant inheriting disturbance of dentin formation characterized by normal enamel formation, but atypical dentin with abnormal pulpal morphology. There are two major patterns: type I and type II. Amelogenesis imperfecta is an autosomal dominant. X-link inherent disease that is classified by clinical manifestation into hypoplastic, hypomature, hypocalcified.

The simultaneous occurrence of dentin dysplasia and amelogenesis imperfecta is quite rare. The purpose of this case report is to present a case of dentin dysplasia type I which is also associated with hypoplastic amelogenesis imperfecta in an 18 year old girl, without any syndromic signs.

**Key words:**•Dentin dysplasia •Amelogenesis imperfecta •Dental anomalies

## Introduction

Dentin dysplasia is presented as a rare autosomal dominant inherent disorder of dentin formation but with normal enamel formation. It is categorized into type I or radicular dysplasia and type II or coronal dysplasia involving both primary and permanent dentition and exhibiting an approximate prevalence of 1:100,000.

Clinically, the teeth show a normal morphologic character. Although, the enamel and coronal dentin are normal clinically and well formed, the radicular dentin loses all organization and subsequently is shortened dramatically.<sup>(1,2)</sup> The first sign of dentin dysplasia type I may be the premature exfoliation of teeth, either spontaneously or with minor trauma, but delay in dental eruption has also been reported.<sup>(2)</sup> Partial or complete obliteration of pulp chambers, defective root formation, and tendency for periapical radiolucency without obvious cause are radiographic signs of this disorder in both deciduous and permanent teeth. Primary teeth show total pulpal obliteration, whereas permanent teeth show pre-eruptive pulpal obliteration, resulting in crescent-shaped pulpal remnants parallel to the cemento-enamel junctions in radiographic view.<sup>(3,4)</sup> Amelogenesis imperfecta encompasses a complicated group of conditions that demonstrate developmental alterations in the structure of the enamel in the absence of a systemic disorder. At least 14 different hereditary subtypes of amelogenesis imperfecta exist with numerous patterns of inheritance and a wide variety of clinical manifestations. There are three subdivisions of amelogenesis imperfecta: 1-hypoplastic, 2-hypomature and 3-hypocalcified type.

Both the deciduous and permanent dentitions are diffusely involved. In patients with hypoplastic amelogenesis imperfecta, the basic alteration concentrates on inadequate deposition of enamel matrix. Insufficient available enamel matrix is mineralized

appropriately and radiographically contrasts well with the underlying dentin.<sup>(4)</sup>

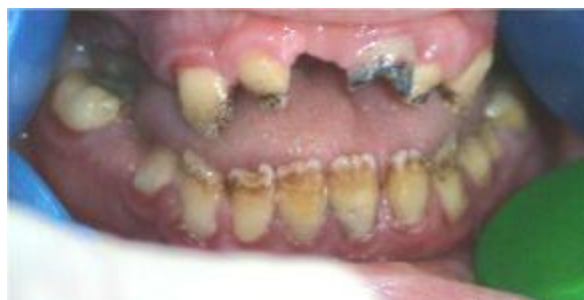The amelogenesis imperfecta may be a part of a syndrome, for example in Trichodonto-osseous syndrome, the amelogenesis imperfecta accompany with dysplastic nails, Taurodontism, curly hair, osseous dysplastic defects or Amelonycho-hypohidrotic syndrome, Morquio syndrome, Kohlschutter syndrome, Epidermolysis bullosa hereditaria, AI, Nephrocalcinosis syndrome, and gingival calcification.<sup>(5,6,7,8)</sup> But the reported dentine dysplasia accompany with dentine dysplasia in the literature.<sup>(9)</sup> The purpose of this case report is to present a case of dentin dysplasia type I which accompanies with hypomature amelogenesis imperfect in an 18 years old girl.

## Case Report

This report describes the clinical and pathological findings of dentin dysplasia type I concomitant with amelogenesis imperfect in an 18 years old girl living in north of Iran (Rasht, Guilan). She referred to the department of oral medicine, Guilan University of medical sciences, dental school. Her chief complaints were dental caries and mobility of teeth. In the past medical history, having had a positive history of grandma epilepsy from infancy, she has taken medication (60mg Phenobarbital tablet per day) to control it. There was no prominent manifestation in the head and neck of the patient.

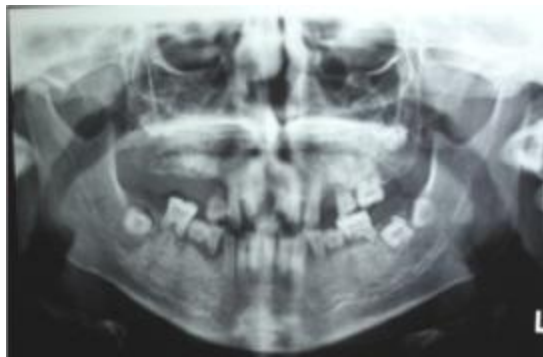
In dental history, extraction of deciduous and permanent teeth was not found. In oral examination, the oral hygiene was poor and marginal gingivitis was seen. In dental examination, the color of teeth was yellow-brown and hypodontia was detected. The teeth number 15, 16, 17, 24 were lost due to significant mobility.

Overall, the available teeth were loose without the periodontal pocket. The enamel was hypoplastic (Figure 1).



**Figure1.** Clinical view Dentin Dysplasia Type I with Hypomature Amelogenesis Imperfecta in an 18-year-old Girl

In panoramic view, the bone structure and trabeculation were normal. The teeth numbers; 18, 28, 38, 37, 47 were impacted without adequate root development. The teeth number 27 and 48 were missed. The entire teeth had short roots and pulp obliteration. The enamels of entire teeth were thin and on some surfaces of posterior teeth were lost. The overall findings were combination or concurrent dentin dysplasia type I and hypoplastic type of amelogenesis imperfecta. The alveolar bone loss exists in some areas (Figure 2).



**Figur2.** Panoramic view Dentin Dysplasia Type I with hypomature amelogenesis imperfecta in an 18-year-old Girl.

## Discussion

One of the causes of tooth exfoliation is the congenital disease DD1 (dentin dysplasia type I). In this disorder, in spite of the normal crown of teeth, the roots are completely

abnormal and have short lengths, due to this malformation, teeth are loose without periodontal pockets around them.

Radiographic examination is crucial for the identification of DD1. In this anomaly, roots have been found to be short, blunt, tapering, or absent in both dentitions. In radiographs, the primary teeth show total pulp obliteration; whereas, the permanent teeth show the obliteration of pulp chambers, periapical radiolucent lesions are areas that may represent granuloma, cyst, or abscess associate with teeth that appears to be vital. Taurodontism, and short blunted roots with pre-eruptive pulpal obliteration result in crescent-shaped pulpal remnants parallel to the cement-enamel junctions.<sup>(3,10,11,12)</sup>

The pathogenesis of DD1 is still unknown in the dental literature. Logan et al. proposed that dentinal papilla is responsible for the abnormalities in root development. They suggested that multiple degenerative foci within the papilla become calcified, leading to reduced growth and final obliteration of the pulp chamber.<sup>(13)</sup> Wesley et al. proposed that the condition is caused by an abnormal interaction of odontoblasts with ameloblasts leading to abnormal differentiation and /or function of these odontoblasts.<sup>(14,15)</sup>

Some studies have localized dentin dysplasia to the interval of chromosome 4q21 containing the dentinogenesis imperfect locus.<sup>(12,15)</sup> It was proposed that dentin dysplasia and dentinogenesis imperfecta represent allelic mutations of a common gene. According to the study by kim et al., based on the radiographic views of their patients, the calcified pulp chambers, rootless teeth, periapical radiolucent and the nature of the periapical lesion are characteristic findings for the diagnosis of DD type 1. DD1 is usually an autosomal dominant condition<sup>(13)</sup>, but in the case reported by Toomarian et al., there was

no familial history of the disease. So, he was considered to be the first generation sufferer. Teeth with radiographic or histologic features of DD1 occur in a number of disorders such as Calcinosis, Ehlers-Danlos syndrome, and Brachio-skeleto-genital syndrome.<sup>(16)</sup> In the case studied by Toomarian et al., the only permanent dentition was affected and periapical radiolucencies were seen and interpreted as periapical granuloma and cysts.<sup>(13)</sup> Scola and Watts proposed a sub-classification of DD1 as total DD1, characterized by the presence of teeth with significantly narrowed or obliterated pulp spaces and permanent teeth with short roots.<sup>(17)</sup> O'Carroll et al. presented another sub classification based on the radiographic findings referring to the severity of pulp chamber obliteration, root length and periapical radiolucencies.<sup>(10)</sup>

Some associations have also been reported between dentin dysplasia and osseous changes in addition to sclerotic bone formation. According to Barron et al., there was a relationship between dentin dysplasia and dentinogenesis imperfecta<sup>(9)</sup>, Nirmala et al. also reported an association between dentin dysplasia type 1 and pyogenic granuloma in a 12 year old girl without positive family history.<sup>(18)</sup> Furthermore, there are associations between amelogenesis imperfecta and some syndromes; for example, Kohlschutter syndrome in which encephalopathy and seizure are accompanied by amelogenesis imperfecta as an autosomal dominant disorder. However, in our study, an association between DD1 and amelogenesis imperfecta was found. In spite of these similarities, no family history and intra relative marriage existed.<sup>(7)</sup> In other syndromes such as Trichodentoosseous syndrome, there is an association of amelogenesis imperfecta and taurodontism and fine hair that is not the same in our case. In some reported cases in contrary to ours, the association of amelogenesis imperfecta

and gingival hyperplasia and nephrocalcinosis were found.<sup>(5,6,7)</sup>

The etiology of abnormal tooth eruption and coronal resorption in amelogenesis imperfect hypoplastic type remains unclear, but appears to be the result of abnormal function of the enamel epithelium and ameloblasts. Failure of eruption in patients with this AI type may be the result of an abnormality in the molecular control of the eruption process that is known to be at least partially driven by the odontogenic epithelium.<sup>(19)</sup>

The researches indicates that all other forms of dentin dysplasia type I and dentine dysplasia, except dentin dysplasia type I, appear to result from mutations in the gene encoding dentine sialophosphoprotein (DSPP), suggesting that these conditions are allelic.<sup>(9)</sup> But in our case, the combination of dentine dysplasia type 1 and amelogenesis imperfect hypoplastic type that is a very rare phenomenon, was observed. There is no specific treatment for this rare genetic disorder affecting the dentin development of the teeth. Only, procedures to prevent the premature loss of hypermobile teeth and to stimulate the normal development of the occlusion can be undertaken. The early diagnosis and continuous follow-up of the cases of DD1 by a pediatric dentist is of paramount importance; inasmuch as the affected teeth show a very unfavorable prognosis due to the short roots.<sup>(12,20)</sup>

## Conclusion

Dentin dysplasia type I is one of the causes of mobility and premature exfoliation of the primary and permanent teeth in young people. Early diagnosis of the condition is of considerable importance for initiation of effective preventive treatment.

In this regard, the oral and maxillofacial medicine specialists and the pediatric dentists have the key role in early diagnosis of this disorder and guiding patients in the

selection of measures to prolong the retention of affected teeth. The association between dentine dysplasia and some

syndromes and congenital abnormality were reported.

## References

1. Neville BW, Damm DD, Allen CM, Bouquet JE. Oral and Maxillofacial Pathology 3rd edition saunders, 2009:108-10 .
2. Kalk WW, Batenburq RH, Vissink A. Dentin dysplasia type I: Oral Surg Oral Med Oral Pathol Oral Radiol Endod 1998;86:175-8.
3. Ozer L, Karasu H, Aras K, Tokman B, Ersoy E. Dentin dysplasia type I: report of atypical cases in permanent and mixed dentitions. Oral Surg Oral Med Oral Pathol Oral Radiol Endod 2004;98:85-90.
4. Crawford P, Aldred M, Bloch-Zupan A. Amelogenesis imperfecta. Orphanet J Rare Dis 2007;4:17.
5. Gandhi B, Gill N, Patel B. TrichoDento Osseous Syndrome, a case report. NJIRM 2012; 3(3):186-189.
6. Martelli-Júnior H, Neto PE, De Aquino SN et al. Amelogenesis Imperfecta and Nephrocalcinosis Syndrome: A Case Report and Review of the Literature. Nephron Physiol 2011;118:62-65.
7. Schossig A, Wolf NA, Kapferer A et al. Epileptic encephalopathy and amelogenesis imperfecta: Kohlschütter-Tönz syndrome. Eur J Med Genet 2012 May;55(5):319-22.
8. Sunitha C, Nirmala R. Amelogenesis imperfecta with gingival calcification: a rare presentation. Braz J Oral Sci 2005;4 (15):932-935.
9. Barron MJ, McDonnell SD, Mackie I, Dixon MJ. Hereditary dentine disorders: dentinogenesis imperfecta and dentine dysplasia. Orphanet J Rare Dis 2008;20:31-41.
10. O'Carroll MK, Duncan WK, Perkins TM. Dentin dysplasia: Review of the literature and a proposed subclassification based on radiographic findings. Oral Surg Oral Med Oral Pathol Oral Radiol 1991;72:119-25.
11. Seow WK, Shusterman S. Spectrum of dentin dysplasia in a family: case report and literature review. Pediatr Dent 1994;16:437-42
12. Rocha CT, Nelson-Filho P, Silva LA, Assed S, Queiroz AM. Variation of dentin dysplasia type I: report of atypical findings in the permanent dentition. Braz Dental J 2011;22:74-78.
13. Toomarian L, Mashhadi Abbas F, Mirkarimi M, Mehrdad L. Dentin dysplasia type I: a case report and review of the literature. J Med Case Rep 2010;7:1-6.
14. Wesley RK, Wysocki GP, Mintz SM, Jackson J. Dentin dysplasia type I. Oral Surg Oral Med Oral Pathol 1976, 41:516-24.
15. McKnight DA, Simmer JP, Hart PS, Hart TC, Fisher LW. Overlapping DSPP Mutations Cause Dentin Dysplasia and Dentinogenesis Imperfecta. J Den Res 2008;87:1108-11.
16. Perl T, Farman AG. Radicular (Type I) dentin dysplasia. Oral Surg Oral Med Oral Pathol 1977, 43:746-53.
17. Scola SM, Watts PG. Dentine dysplasia type I. A subclassification Br J Orthod 1987;14:175-9.
18. Nirmala SV, Sivakumar N, Usha K. Dentin dysplasia type I with pyogenic granuloma in a 12-year-old girl. J Indian Soc Pedod Prev Dent 2009;27:131-4.

## Dentin dysplasia type I with hypomature amelogenesis imperfecta

19. Lindemeyer RG, Gibson CW, Wright TJ. Amelogenesis Imperfecta Due to a Mutation of the Enamelin Gene: Clinical Case With Genotype-phenotype Correlations. *Pediatr Dent* 2010; 32(1): 56–60.
20. Brenneise CV, Dwornik RM, Brenneise EE. Clinical, radiographic, and histological manifestations of dentin dysplasia, type I: Report of case. *J Am Dent Assoc* 1989;119:721-3.