

Foreign Body in Nasal Cavity: Panoramic and Cone-Beam Computed Tomography (CBCT) Findings

Case Report

Zahra Dalili¹, Safa Motevasseli², Pouya Nejadshamsi³

¹ Professor, Oro-maxillofacial developmental diseases research center, Department of Maxillofacial Radiology, Guilan University of Medical Sciences, Dental School, Rasht, Iran

² Assistant Professor, Department of Maxillofacial surgery, Guilan University of Medical Sciences, Dental School, Rasht, Iran

³ Assistant Professor, Department of Endodontics, Guilan University of Medical Sciences, Dental School, Rasht, Iran

Received: Sep 19, 2012

Accepted: Dec 20, 2012

Corresponding Author:

Safa Motevaselee, DDS

Address: Oro-maxillofacial developmental diseases research center, Department of Maxillofacial Surgery Guilan University of Medical Sciences, Dental School, Rasht, Iran.

Telephone: +98-131- 3263628

Fax: +98-131- 3263623

E-mail: Smotevaselee@Gmail.com

Abstract

Introduction: Panoramic view as a routine dental radiograph has an important role in diagnosis of other facial abnormalities accompanied with dento- alveolar structures. In this case presentation, we discuss this subject and also the efficacy of cone-beam computed tomography in localization of foreign body in complex anatomy of nasal cavity.

Key words: •Cone-beam Computed Tomography
•Foreign Bodies •Nasal Cavity

Case Report

An 8 year-old girl referred to the department of maxillofacial radiology of Guilan University of medical sciences. The problem was the existence of ring like opaque shadow on the right (Rt) side of her panoramic view.

According to her mother's statement, the panoramic view was taken for routine dental examination. We were assured of removing the hair clips at the time of hair removal.

Regarding the medical history there was no complain about bad oral odor, chronic nasal congestion, epistaxis, fever and feeling foul fetor.

In the panoramic view, we found the string of round small rings superimposed on Rt maxillary sinus with linear opaque ghost shadow on the left (Lt) side of maxilla (Figure1). This finding confirmed the position of this opaque structure in the zone of ghost. The important point was the absence of double real image. Overall, the probable position of this object was in the level of portion of the palate but in the nearly midline such as posterior portion of nasal cavity. Cone beam computed tomography (CBCT) was suggested for better localization. The Lateral view of face to prevent more patient exposure was not provided.

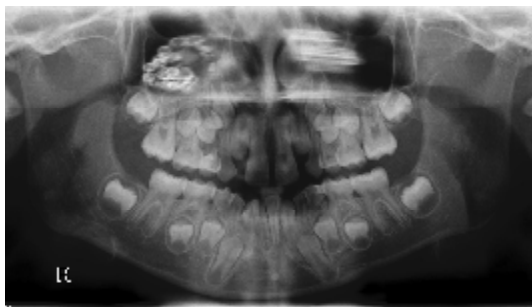


Figure 1. Ring-like opacity on Rt side of maxillary sinus and the parallel linear ghost shadow on Lt side

CBCT findings revealed multiple round metal densities on the floor of Rt nasal cavity below the inferior turbinate but in the posterior portion. It seems that a thin soft tissue or mucosal coat was overlaid on it. Deviation of septum and adenoid enlargement were other noticeable findings in multiplanar

(MPR) and three-dimensional (3D) images of cone beam computed tomography (CBCT) (Figures 2 and 3). In the evaluation of different axial cuts, the size of Rt maxillary sinus was smaller than Lt side.

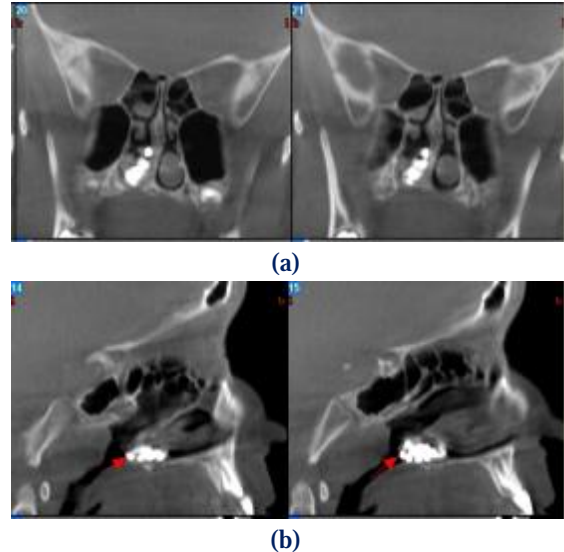


Figure 2. Coronal (a), Sagittal (b) views present the collection or chain of multiple opaque densities in posterior portion of nasal cavity and under the inferior turbinate. The nasal septum is deviated toward the left side.

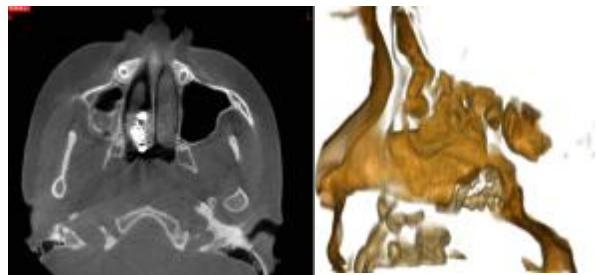


Figure 3. Axial (a) and 3D (b) images of the foreign body in nasal cavity

The intranasal foreign body was removed following endoscopic surgery. The metal chain was pulled out nasal cavity (Figure 4).



Figure 4. The metal chain as a foreign body

Discussion

Nasal foreign bodies are discovered on the floor of nasal cavity and below the inferior turbinate or anterior to middle turbinate which are the most common locations.⁽¹⁾

Most intranasal objects can result in congestion, swelling of the nasal mucosa, ulceration, mucosal erosion, epistaxis and foul fetor, but some of them may remain many years without any signs or symptoms of mucosal changes.^(2,3) In our case, no history of significant abnormal findings was reported.

The foreign body in nasal cavity could be the carrier of infectious disease.⁽⁴⁾ It also could be the nidus for development of rhinolithiasis. Orbital abscess as a result of acute rhinosinusitis and secondary to the impaction of nasal foreign body was reported,⁽⁵⁾ but in our presentation, we did not find the radiological signs of rhinosinusitis. The only important finding was reduction in the size of Rt maxillary sinus in comparison with Lt side.

The foreign bodies are either animate or inanimate. Inanimate foreign bodies include exogenous or endogenous materials. Endogenous form could be originated from bone spicules and cartilage fragments of paranasal sinuses and palates following the trauma or intranasal manipulations. The most common exogenous materials are beads, nuts, pins, chalk and so on. Animate foreign bodies are larvae of flies, nematode or intestinal worms.

Sometimes, a coat of granulation tissue covers the foreign body and attaches it to an adjacent mucosal lining. The presence of some of foreign bodies in nasal cavity must be considered seriously such as buttons and batteries due to the destruction of heavy metals on the nasal septum^(6,7) and liquefaction necrosis of the local tissue. Unilateral mucopurulent nasal discharge with fuel odor is the most common symptom in patients with a nasal foreign body.⁽²⁾ Sometimes, the foreign body resembles concha bullosa in the middle meatus.⁽⁸⁾

The most significant point is the location of foreign body to be compatible with the location of objects producing double real image in panoramic view, which was not observed in these findings. The panoramic

view in this presentation shows that the image of posterior portion of nasal cavity distributes on the image of maxillary sinus.

The unilateral vestibulitis and nasal discharge particularly in children should be regarded as the unilateral nasal foreign object.⁽⁹⁾ Endoscopic examination of nasal cavity can be affected to diagnose the foreign body but sometimes granulation tissue tend to hide it.⁽²⁾

Different approaches for removal of nasal body include: take a deep breath through the mouth and then forcibly exhale through the nose, local mouth-to-mouth ventilation, using Foley catheter and external rhinoplasty.⁽¹⁰⁾

There are broad ranges of success rates of different techniques for removal of nasal foreign body. The selection of the method depends on the level of Patients' cooperation, size, shape, composition and location of the foreign objects, as well as the experience of the surgeon.

Mechanical removal by instruments is not indicated for small nasal and oval-shaped foreign bodies that are located out of the range of nasal instrumentation and also the uncooperative patients. In this way, non-mechanical approaches such as positive air pressure and kissing technique and sometimes mechanical removal under anesthesia are recommended.

The mechanical removal of anterior located foreign bodies could be done by using forceps such as alligator or byonet that grasp and pull them out. Hooked probes could be passed beyond hard smooth objects then was rotated and pushed out slowly and gently. The operators must apply these methods accurately to prevent significant trauma and massive local bleeding.⁽¹⁰⁾

Suction catheter could be applied for smooth and non-graspable nasal foreign bodies. In this method, the tip of catheter suctions the foreign body toward outside.

Balloon catheter is also available. Pre-lubricated catheter is passed above the foreign body then balloon tip is subsequently inflated with flow of air and water. Then, the catheter is dislodged from the nose.⁽³⁾

In some complicated cases such as posterior located and inaccessible foreign

bodies, external rhinoplasty and/or endoscopic approach are preferred.⁽¹¹⁾

to prevent from prospect complications particularly in children.

Conclusion

Nasal foreign objects could be an incidental finding in routine dental radiographs that must be considered seriously

Acknowledgement

I would like to thank Mahtab Janzadeh for her help in gathering the images.

References

1. De Weese DD, Saunders AH. Acute and chronic disease of the nose. 1st ed. St. Louis: C.V. Mosby; 1982. emedicine.medscape.com/article/763767-overview.
2. Heim SW, Maughan KL: Foreign bodies in the ear, nose, and throat. *Am Fam Physician* 2007; 76(8): 1185-9.
3. Kalan A, Tariq M. Foreign bodies in the nasal cavities: a comprehensive review of the aetiology, diagnostic points, and therapeutic measures. *Postgrad Med J* 2007; 76: 484-9.
4. Burton AH, Balmain AR. Foreign bodies and nasal carriers of diphtheria. *Lancet* 1929; 217:977-118.
5. Webb BD, Pereira KD, Fakhri S. Nasal foreign body as the cause of a subperiosteal orbital abscess in a child. *Ear Nose Throat* 2010; 89(2): E11-3.
6. McRae D, Premachandra DJ. Button batteries in the ear, nose and cervical oesophagus foreign body. *J Otolaryngol* 1989; 18(6): 317-19.
7. Zanetta A, Cuestas G, Rodríguez H, Quiroga V: Septal perforation in children due to button battery lodged in the nose: Case series]. *Arch Argent Pediatr*; 2012; 110(5): 430-4.
8. Uğur MB, Evren C, Corakçi S, Taş E, Cinar F. Kulak Burun Bogaz Ihtis Derg. Foreign body which resembles concha bulloza in the middle meatus: a case report. *Kulak Burun Ihtis Derg* 2009; 19(6): 307-10.
9. Schutte HW, Timmer FC, van den Hoogen FJ. Chronic unilateral rhinorrhea in childhood. *Ned Tijdschr Geneesk* 2012; 156(18): A3220.
10. Pavan MP, Rajeev Anand. Nasal foreign bodies: A review of management strategies and a clinical scenario presentation. *Craniofacial Trauma & reconstruction* 2011; 4(1): 53-7.
11. Ryu CH, Jang YJ, Kim Js, Song HM. Removal of a metallic foreign body embedded in the external nose via open rhinoplasty approach. *Int J Oral Maxillofac Surg* 2008; 37: 1148-52.