

# Papillon-Lefèvre Syndrome

## Case Report

Maryam Basirat<sup>1</sup>, Atessa Pakfetrat<sup>2</sup>, Adineh Javadian Langaroodi<sup>3</sup>

<sup>1</sup> Assistant professor, Oro-maxillofacial developmental diseases research center, Department of oral medicine, Guilan University of Medical Sciences, Dental school, Rasht, Iran

<sup>2</sup> Associate professor, Dental Research Center, Mashhad University of Medical Sciences, Dental School, Mashhad, Iran

<sup>3</sup> Assistant professor, Department of Oral and Maxillofacial Radiology, Mashhad University of Medical Sciences, Dental School, Mashhad, Iran

**Received:** Oct 3, 2012

**Accepted:** Nov 17, 2012

### **Corresponding Author:**

**Maryam Basirat, DDS**

**Address:** Oro-maxillofacial developmental diseases research center, Department of oral medicine, Guilan University of Medical Sciences, Dental School, Rasht, Iran

**Telephone:** +98-131-3263621-22

**Fax:** +98-131- 3263623

**E-mail:** [mbasirat2010@gmail.com](mailto:mbasirat2010@gmail.com)

## **Abstract**

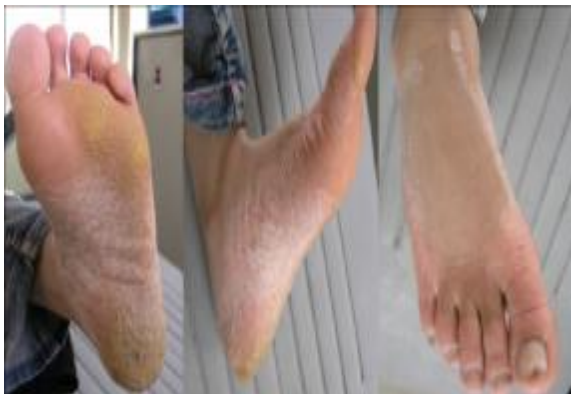**Introduction:** Papillon-Lefèvre syndrome (PLS) characterized by palmoplantar hyperkeratosis is a rare autosomal recessive genetic disorder with rapidly progressive periodontitis and premature loss of both deciduous and permanent teeth. In this study, we report the clinical and radiographic features of Papillon-Lefèvre syndrome in an 11-year-old girl and we also discuss the history and various theories about the etiology and treatment planning for this syndrome.

**Key words:** •Keratoderma, Palmoplantar  
•Papillon- Lefèvre Disease •Periodontitis

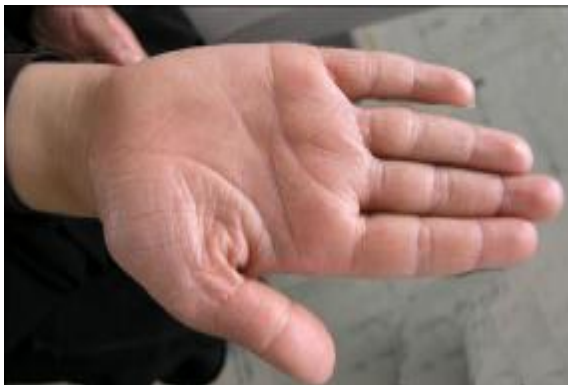**Case Report**

An 11 years-old-girl referred to Oral Medicine Department of Mashhad Faculty of Dentistry, complaining of loose teeth and discomfort in chewing. The patient had lost the primary teeth when she was five years old. Her mother informed us about the existence of the hyperkeratotic lesions in soles since her child was 2 years old. Tooth mobility and hyperkeratosis had also seen in her sister. The mother's pregnancy and delivery were uneventful.

Hyperkeratosis of the palms and soles was revealed by extra oral examination (Figure. 1a, b). The nails also were hypoplastic. The perioral skin of the patient was dry (Figure. 2). The Overall mental and physical growth was normal and the hair and sebaceous gland had grown normally.



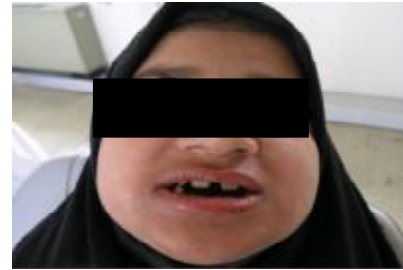(a)



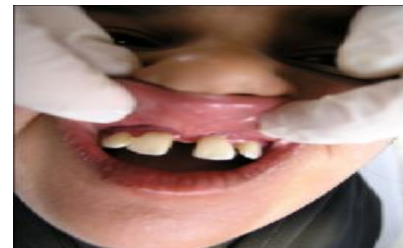(b)

**Figure 1. a) Plantar hyperkeratosis which included sharply demarcated, punctate, striate or diffuse lesions. The nails were also hypoplastic, b) palmar hyperkeratosis**

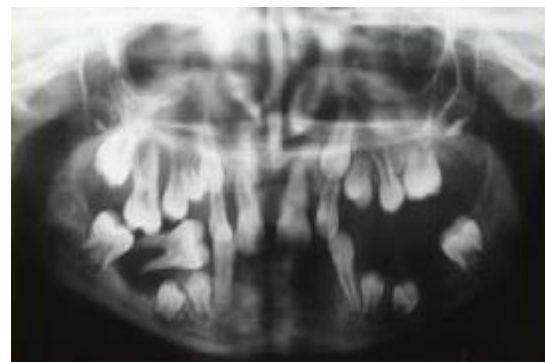
According to intraoral examination, the gingiva was edematous and hyperemic (Figure 3). Periodontitis was revealed in four quadrants. Radiographic examination showed moderate to severe alveolar bone loss. "Hang in air" appearance was evident for some teeth (Figure 4).



**Figure 2. Dryness of perioral skin**



**Figure 3. Appearance of gingival erythema, edema and severe periodontal disease**



**Figure 4. Periodontitis and floating appearance of teeth**

Hematological investigation such as cell blood count(CBC),serum calcium, phosphate, alkaline phosphatase (ALP), hematocrit, mean corpuscular volume (MCV) and mean corpuscular hemoglobin (MCH) were all within the normal range. Diagnosis of Papillon- Lefèvre syndrome was based on the familial history and presence of periodontitis and palmoplantar hyperkeratosis. Treatment by administration of broad spectrum of antibiotics (combination of

amoxicillin and metronidazole 250mg of each, three times daily for 10 days) started. Extraction of teeth with poor prognosis and oral rehabilitation by partial denture were planned to restore esthetic and masticatory function. Unfortunately the patient didn't follow up.

## Discussion

Haneke suggested three criteria for classifying a case as PLS: palmoplantar hyperkeratosis, loss of permanent and primary teeth, and autosomal recessive inheritance.<sup>(1)</sup>

Our case matched the first two criteria but we could not confirm the third criteria due to lack of family cooperation. Tooth mobility and hyperkeratosis had also been present in her sister.

In this syndrome, skin lesions are presented from the age of 6 months to 3 years, approximately at the time of primary tooth eruption. Soles of the feet are also frequently affected more severely than the other regions. In our case, the skin lesions had begun to appear at the age of 2 years old.

Although the exact pathogenesis of this syndrome remains relatively obscure. Immunologic, microbiologic, and genetic bases have been proposed.<sup>(2-6)</sup> A decreased chemotactic and phagocytic function of neutrophils, myeloperoxidase deficiency, and low integrin expression has also been suggested as the possible pathogenesis.<sup>(7-9)</sup> Capnophilic and facultatively anaerobic species mainly *Capnocytophaga* spp and *Streptococcus* spp, have also been demonstrated by microbiological studies.<sup>(10)</sup> Some previous case reports revealed that human herpes viruses (HSV) in concert with actinobacillus actinomycetemcomitans (AA) play an important role in the development of PLS periodontitis.<sup>(11)</sup>

Periodontitis and systemic diseases that accompanied with periodontitis should be differentiated with PLS. The conditions such as acro-dynia, Haim-Munk syndrome, Ehlers-Danlos syndrome, hypophosphatasia, leukemia, various neutropenia, histiocytosis X, acatalasia, and Chediak-Higashi syndrome are characterized with premature loss of primary and permanent dentition.<sup>(12-14)</sup> Results of hematological tests help to differentiate this

conditions from hypophosphatasia, leukemia, and various neutropenia. Also, since the dermatological condition of patients with Haim-Munk syndrome is more severe with a later onset, our initial diagnosis was PLS. Hypopigmentation in skin and hair, recurrent bacterial infections of the skin and respiratory tract, neuropathy, ataxias, and gingival-periodontal disease<sup>(12-14)</sup> are manifestation of chediak-higashi syndrome. Cold and clammy skin on hand, ear, nose, and feet<sup>(13)</sup> should be noticed in patients with acro-dynia.

Some patients of PLS show infections like otitis media and pyogenic infections of the skin due to some dysfunction of lymphocytes and leukocytes<sup>(15-19)</sup> but this patient did not present those infections.

Periodontitis in primary and permanent dentition accompanied with edema and erythema of gingiva which are recovered after extraction of teeth are the pathognomic dental findings of PLS.<sup>(17, 20, 21)</sup>

Papillon-Lefèvre syndrome can also adversely affect psychological and social growth and esthetics of children. Hence, for providing complete psychosocial rehabilitation in PLS, children's early dental evaluation and parental counseling is essential as a part of preventive dental treatment; therefore a multidimensional approach may improve the prognosis and the life quality of these children.<sup>(2, 22-25)</sup>

Extraction of primary teeth before eruption of permanent teeth<sup>(5, 22, 23)</sup>, combination of periodontal treatment and appropriate use of antibiotic<sup>(5,21,22)</sup>, administration of systemic retinoids under physician's supervision<sup>(2,5)</sup>, and prosthetic rehabilitation are the suggested treatments for PLS. This approach is age-specific and includes initially replacement of partial or complete denture and later implant supported Dentures.<sup>(24,27)</sup>

The concomitant supportive periodontal therapy and antibiotic coverage could not stop the loss of periodontal attachment and destruction of the alveolar bone. The outcome of long-term follow-up of some cases showed that management of PLS-associated periodontitis is further complicated when the patient is first seen in the mixed dentition stage or later.<sup>(22)</sup>

To avoid possible complications in a case with PLS, dental osseointegrated implants (even with shorter lengths) safely used for atrophic mandibles instead of invasive preprosthetic applications such as bone augmentation, nerve lateralization, or alveolar distraction.<sup>(26)</sup> In another patient with PLS, twelve titanium implants were installed in the

mandible and maxilla. All implants were clinically stable and no pain or infection was reported at 3 years follow-up.<sup>(27)</sup> Table 1 summarizes the clinical findings and treatment planing of reported cases of PLS. In our patient, hopeless teeth were extracted and antibiotic was administered. Construction of extracted teeth by partial denture was advised.

**Table 1. Summary of studies and case reporting of Papillon-Lefèvre in PubMed journals**

Authors	Year	Age (year)	Follow up (year)	Sex	Country	Final Treatment
Senel et al (27)	2012	18	+ (3)	M	Turkey	implant
Ahmadian et al(24)	2011	21	+ (4)	F	Iran	implant
Rothod et al(28)	2010	16, 18	Not Known	M	India	Partial denture
Etoz et al (26)	2010	34	+1	Not known	Turkey	Implant
Nagaveni et al(2)	2008	11,9	Not known	F, M	India	denture
canger, et al(29)	2008	8	Not known	M	Turkey	denture
Toygar et al(25)	2007	6	+ (13)	F	Turkey	Implant
De Freitas et al(22)	2007	9 years and 11months	+ (14)	F	Brazil	Complete denture
Wiebe et al(23)	2005	3.5	+ (12)	M	Canada	Periodontal therapy
Nickles et al(37)	2005	Not known	+ (5)	M, M	Germany	Periodontal therapy
nitta et al (31)	2005	5	Not known	M	Japan	Not known
patel, et al(17)	2004	Preschool age	Not known	Not known	UK	Not known
Pilger et al (32)	2003	46	Not known	F	Austria	Not known
Pacheco et al(33)	2002	11	16 month	F	Portugal	Periodontal therapy
Angel et al(34)	2002	Not known	Not known	Not known	USA	Not known
Eickholz et al(35)	2001	7	26month	M	Germany	Periodontal therapy
Wara-aswapatiet al (4)	2001	3 years and 4 months	Not known	M	Thailand	Not known
Robertson(10)	2001	Not known	Not known	Not known	UK	Not known
De Vree et al(36)	2000	6, 8	+ (15)	Not known	Belgium	Periodontal therapy

F(female), M(male), periodontal therapy(include extraction of hopeless teeth, scaling, root planning, prescription of antibiotics)

## Conclusion

Papillon-Lefèvre syndrome should be considered in the probable causes for early exfoliation of teeth in children. One of the manifestations of PLS is periodontitis and the dentists have a significant role in early diagnosis of this condition. The extraction of all the deciduous teeth before their natural exfoliation can prevent recurrent attachment

loss in the permanent teeth thus bone quantity and quality, which is necessary for successful placement of dental implant, is preserved.

## Acknowledgement

I would like to express my gratitude to the departments of oral medicine and periodontics of Mashhad dental school for this invaluable cooperation to run this study.

## References

1. Haneke E. The Papillon Lefevre syndrome: Keratosis palmoplantaris with periodontopathy: Report of a case and review of the cases in the literature. *Hum Genet* 1979; 51: 1-35.
2. Nagaveni NB, Suma R, Shashikiran ND, Subba Reddy VV. Papillon-Lefevre syndrome: Report of two cases in the same family. *J Indian Soc Pedod Prev Dent* 2008; 26(2):78-81.
3. Sagllie FR, Marfany A, Camargo P. Intraingival occurrence of *Actinobacillus actinomycetemcomitans* and *Bacterioides gingivalis* in active destructive periodontal lesions. *J Periodontol* 1988; 59: 259-65.
4. Wara-aswapati N, Lertisirivorakul J, Nagasawa T, Kawashima Y, Ishikawa I. Papillon-Lefevre syndrome: Serum immunoglobulin G (Ig G) subclass antibody response to periodontopathic bacteria: A case report. *J Periodontol* 2001; 72: 1747-54.

5. Tinanoff N, Temprow P, Maderazo EG. Dental treatment of Papillon-Lefevre syndrome: 15 year follow-up. *J Clin Periodontol* 1995; 22: 609-12.
6. Stabholz A, Taichman S, Soskolne WA. Occurrence of *actinobacillus actinomycetemcomitans* and anti-leukotoxin antibodies in some members of an extended family affected by Papillon-Lefevre syndrome. *J Periodontol* 1995; 66: 653-7.
7. Firatli E, Gurel N, Efeoglu A, Badur S. Clinical and immunological findings in 2 siblings with Papillon-Lefevre syndrome. *J Periodontol* 1996; 67:1210-5.
8. Van Dyke TE, Taubman MA, Ebersole JL, Haffajee AD, Socransky SS, Smith DJ, Genco RJ. The Papillon-Lefevre syndrome: neutrophil dysfunction with severe periodontal disease. *Clin Immunol Immunopathol* 1984; 31(3): 419-29.
9. Hart TC, Shapira L. Papillon-Lefevre syndrome. *Periodontol* 2000 1994; 6: 88-100.
10. Robertson KL, Drucker DB, James J, Blinkhorn AS, Hamlet S, Bird PS. A microbiological study of Papillon-Lefevre syndrome in two patients. *J Clin Pathol* 2001; 54(5): 371-6.
11. Velazco CH, Coelho C, Salazar F, Contreras A, Slots J, Pacheco JJ. Microbiological features of Papillon-Lefevre syndrome periodontitis. *J Clin Periodontol* 1999; 26(9):622-7.
12. Newman MG, Takei HH, Klokkevold PR, Carranza FA. Carranza's clinical periodontology. 11th ed. Philadelphia: WB Saunders Elsevier Co; 2012.pp. 278
13. Neville BW, Damm DD, Allen CM, Bouquot JE. Oral & Maxillofacial Pathology. 3rd ed. Philadelphia: WB Saunders Co; 2009.PP.319, 590 -3, 845-6.
14. Dean JA, Avery DR, MC Donald RE. MC Donald and Avery's Dentistry for the child and adolescent. 9th ed. Maryland Heights: Mosby Elsevier; 2011.pp. 94,145-6,386.
15. Bergman R, Friedman-Birnbaum R. Papillon- Lefevre syndrome a study of the long term clinical course of recurrent pyogenic infections and the effects of etretinate treatment. *Br J Dermatol* 1998; 119: 731-6.
16. Hattab FN, Rawashdeh MA, Yassin OM, Al-Momani AS, Al-Ubosi MM. PapillonLefevre syndrome: A review of literature and report of 4 cases. *J Periodontol* 1995; 66: 413-20.
17. Patel S, Davidson LE. Papillon-Lefevre syndrome: a report of two cases. *Int J Paediatr Dent*. 2004; 14(4):288-94.
18. Fardal Q, Drangsholt E, Olsen I. Palmar plantar keratosis and unusual periodontal findings. Observations from a family of 4 members. *J Clin Periodontol* 1998; 25: 181-84.
19. Mahajan VK, Thakur NS, Sharma NL. Papillon-LeFevre syndrome. *Indian Pediatr* 2003; 40: 1197-200.
20. Gorlin RJ, Sedano H, Anderson VE. The syndrome of palmar - plantar hyperkeratosis and premature periodontal destruction of the teeth: A clinical and genetic analysis of the Papillon-Lefevre syndrome. *J Pediatr* 1964; 65 (6): 895-908.
21. Lundgren T, Renvert S. Periodontal treatment of patients with Papillon-Lefevre syndrome: a 3-year follow-up. *J Clin Periodontol* 2004; 31(11): 933-8.
22. De Freitas AC, Assed S, da Silva LA, Silva RA. Aggressive periodontitis associated with Papillon-Lefevre syndrome: report of a 14-year follow-up. *Spec Care Dentist* 2007; 27(3): 95-100.
23. Wiebe CB, Häkkinen L, Putnins EE, Walsh P, Larjava HS. Successful periodontal maintenance of a case with Papillon-Lefevre syndrome: 12-year follow-up and review of the literature. *J Periodontol* 2001; 72(6): 824.
24. Ahmadian L, Monzavi A, Arbabi R, Hashemi HM. Full-mouth rehabilitation of an edentulous patient with Papillon-Lefevre syndrome using dental implants: a clinical report. *J Prosthodont* 2011; 20(8): 643-8.
25. Toygar HU, Kircelli C, Firat E, Guzeldemir E. Combined therapy in a patient with Papillon-Lefevre syndrome: a 13-year follow-up. *Periodontol* 2007; 78(9): 1819-24.
26. Etöz OA, Ulu M, Kesim B. Treatment of patient with Papillon-Lefevre syndrome with short dental implants: a case report. *Implant Dent* 2010; 19(5): 394-9.
27. Senel FC, Altintas NY, Bagis B, Cankaya M, Pampu AA, Satrioglu I, Senel AC. A 3-year follow-up of the rehabilitation of papillon-lefevre syndrome by dental implants. *J Oral Maxillofac Surg* 2012; 70(1): 163-7.

28. Rathod VJ, Joshi NV. Papillon-Lefevre syndrome: A report of two cases. *J Indian Soc Periodontol* 2010; 14(4): 275-8.
29. Canger EM, Celenk P, Devrim I, Yenisey M, Gunhan O. Intraoral findings of Papillon-Lefevre syndrome. *J Dent Child (Chic)* 2008; 75(1): 99-103.
30. Gorlin RJ, Cohen MM, Hennekens RC. *Syndromes of head and neck*. 4th ed. New York: Oxford University Press; 2001. PP.1101-3.
31. Nitta H, Wara-Aswapati N, Lertsirivorakul J, Nakamura T, Yamamoto M, Izumi Y, et al. A novel mutation of the cathepsin C gene in a Thai family with Papillon-Lefevre syndrome. *J Periodontol* 2005; 76(3): 492-6.
32. Pilger U, Hennies HC, Truschneegg A, Aberer E. Late-onset Papillon-Lefevre syndrome without alteration of the cathepsin C gene. *J Am Acad Dermatol* 2003; 49(5): S240-3.
33. Pacheco JJ, Coelho C, Salazar F, Contreras A, Slots J, Velazco CH. Treatment of Papillon-Lefevre syndrome periodontitis. *J Clin Periodontol* 2002; 29(4): 370-4.
34. Angel TA, Hsu S, Kornbleuth SI, Kornbleuth J, Kramer EM. Papillon-Lefevre syndrome: a case report of four affected siblings. *J Am Acad Dermatol* 2002; 46(2): S8-10.
35. Eickholz P, Kugel B, Pohl S, Näher H, Staehle HJ. Combined mechanical and antibiotic periodontal therapy in a case of Papillon-Lefevre syndrome. *J Periodontol* 2001; 72(4): 542-9.
36. De Vree H, Steenackers K, De Boever JA. Periodontal treatment of rapid progressive periodontitis in 2 siblings with Papillon-Lefevre syndrome: 15-year follow-up. *J Clin Periodontol* 2000; 27(5): 354-60.
37. Nickles K, Schacher B, Schuster G, Valesky E, Eickholz P. Evaluation of two siblings with Papillon-Lefevre syndrome 5 years after treatment of periodontitis in primary and mixed dentition. *J Periodontol*. 2011; 82(11):1536-47.

# Prevalence of Developmental and Acquired Dental Anomalies on Digital panoramic Radiography in Patients Attending the Dental Faculty of Rasht, Iran

## Original Article

Somayeh Nemati<sup>1</sup>, Zahra Dalili<sup>2</sup>, Nastaran Dolatabadi<sup>3</sup>,  
Alieh Sadat Javadzadeh<sup>4</sup> Seied Tahereh Mohtavipoor<sup>5</sup>

<sup>1,4,5</sup> Assistant Professor, Department of Maxillofacial Radiology, Guilan University of Medical sciences, Dental school, Rasht, Iran

<sup>2</sup> Professor, Department of Maxillofacial Radiology, Guilan University of Medical sciences, Dental school, Rasht, Iran

<sup>3</sup> Dentist, Department of Maxillofacial Radiology, Guilan University of Medical sciences, Dental school, Rasht, Iran

**Received:** Nov 28, 2012

**Accepted:** Dec 26, 2012

### **Corresponding Author:**

**Zahra Dalili, DDS**

**Address:** Oro-maxillofacial developmental diseases research center, Department of Maxillofacial Radiology, Guilan University of Medical sciences, Dental school

**Telephone:** +98-131-3263622

**Fax:** +98-131-3263623

**E-mail:** Dalili@ gums.ac.ir

## **Abstract**

**Introduction:** Many epidemiological studies have been conducted to determine the prevalence of the various types of the dental anomalies. The aim of the present study was determination of developmental and acquired dental anomalies in patients attending the faculty of dentistry in Rasht, Iran.

**Materials and Methods:** In this retrospective cross-sectional study, 1224 digital panoramic radiographs belong to 758 females and 466 males were assessed for evaluation of 10 developmental and acquired dental anomalies. This study was done in two steps; prospective and retrospective. Both clinical and radiographic evaluation of patients was conducted for diagnosis of missing teeth, talon cusp, amelogenesis imperfecta, dentinogenesis imperfecta and dentine dysplasia. The chi-square test, Fisher-Exact test, Independent t-test and Kappa were used for statistical analysis of data.

**Result:** 396 patients (32.4%) presented at least one developmental dental anomaly and 285 patients (23.3%) had at least one acquired dental anomaly. Overall, 38.1% of 581 patients with dental anomaly were males and 61.9% of them females. Supernumerary teeth in males was more than five times higher than females ( $p < 0.005$ ). Pulp stone in females was 7% higher than males ( $p < 0.005$ ). The most prevalent anomaly was impaction (16.6%), followed by dense invagination (10.9%), dilaceration (5.6%), microdontia (3.8%), supernumerary tooth (1.1%), taurodontism (0.5%) and transposition (0.1%).

**Conclusion:** The dental anomalies occur with different frequencies in various populations. Since, these anomalies may be the cause of various dental problems, it seems that the precise diagnosis of these anomalies is essential in the prevention of the next problems.

**Key words:** •Prevalence •Radiography, Panoramic •Tooth abnormalities

## Introduction

Dental anomalies are one type of the anomalies of the human structure that result from disturbances during tooth formation.<sup>(1)</sup>

Dental anomalies can be congenital, developmental or acquired and consisted of various changes in tooth number, size, shape, position in the jaws, eruption pattern and normal morphology.<sup>(1)</sup> Congenital abnormalities typically are those inherited genetically. The acquired anomalies come from teeth alterations during normal formation.<sup>(2)</sup> The developmental anomalies are those that occur during tooth development.<sup>(2)</sup> They could appear isolated or related to various other syndromes.<sup>(1,2)</sup> These anomalies may begin before or after birth, hence deciduous or permanent teeth may be affected.<sup>(3)</sup> Dental anomalies in comparison with more common oral disorders such as dental caries and periodontal diseases have low frequency but their management is usually complicated, because they can result in the malocclusion, esthetic problems and predisposition to the other oral diseases.<sup>(4)</sup>

Many epidemiological studies have been done in different populations of the world to survey the prevalence of dental anomalies but the results are conflicting.<sup>(4,5)</sup> Differences in their results can be related to racial and regional variations, variable sampling techniques and the different diagnostic criteria.<sup>(5)</sup> The early detection of dental anomalies is important, because they can result in many disturbances and early diagnosis can prevent from such complications.<sup>(6)</sup> For example, existence of dense invagination and absence of early diagnosis can be the cause of pulpo-periapical lesions without obvious detection of dental caries. However, conservative treatments would prevent such problems.<sup>(2,6)</sup> Also, their incidence and degree of expression can provide significant information for genetic studies and contribute to the understanding of differences within (intra) and between (inter) populations.<sup>(5)</sup>

This study was run due to lack of enough studies regarding the prevalence of both acquired and development dental anomalies in Guilan province in large samples. So, the purpose of the present study was to determine the prevalence and distribution of selected

developmental and acquired dental anomalies on digital panoramic radiography of the patients attending to the faculty of dentistry Rasht, Iran during 2010-2012.

## Materials and Methods

In this cross-sectional study, our study was run in two steps:

**Step 1:** Retrospective radiographic study which was the major part for evaluation of the prevalence of dental anomalies.

**Step 2:** Prospective study with considering both clinical and radiographic findings to assess the frequency of some other dental anomalies.

### Step 1:

In the retrospective cross-sectional study, a total of 1224 digital panoramic radiographies of patients who attended the department of radiology of the dental faculty of Guilan university of medical sciences, during 2010-2012 were included in this study. The age of subjects was 7-76 years (mean age  $12.67 \pm 30.55$ ). Overall, the panoramic views of 758 females and 466 males were evaluated.

The exclusion criteria of the subjects included the presence of cleft lip and palate; inadequate teeth (less than 28 teeth); improper quality of radiographs, having orthodontic brackets and dental fracture that influence the diagnosis of the dental anomalies. In each radiography, teeth which had crown, endodontic treatment, caries or restorations that influence the diagnosis of some anomalies such as pulp stone, dense invagination, and taurodontism were excluded.

In order to reduce the radiographic misinterpretation, teeth with incomplete root formation and the maxillary molars and premolars for evaluation of dilaceration and external root resorption, were not included in the study. But, these teeth were used for the evaluation of the anomalies that were related to the number of teeth (i.e. supernumerary teeth) in overall patient sampling.

The inclusion criteria included following items:

1. The archived standard digital computed panoramic radiographs (CR) that were taken by the same unit; EC proline



planmeca (Helsinki, Finland) with appropriate diagnostic quality.

2. The radiographies with determined complete demographic information (name, age, sex and date of radiography) were used.

3. The radiographs of patients more than 7 years old were selected.

4. All photostimulable phosphor plates (PSP) were processed by digitizer (Konica-Minolta, Tokyo, Japan).

The panoramic views were carefully analyzed by a maxillofacial radiologist using standard medical monitor with the ability for magnification and brightness adjustment of archived digital panoramic radiographs. The list of different anomalies that were investigated in this study is presented below.

• **Developmental anomalies related to:**

1. The number of tooth:
  - Impacted supernumerary tooth
  - Erupted supernumerary tooth
2. The size of tooth: microdontia
3. The shape of tooth:
  - Dense invagination
  - Taurodontism
  - Dilaceration
4. The eruption and position:
  - Impaction
  - Transposition

• **Acquired anomalies:**

- Internal root resorption
- External root resorption
- Pulp stone

The radiographic diagnostic criteria in the present study were made on the basis of the descriptions presented in accepted text in the field of maxillofacial radiology<sup>(2)</sup>. Also, in this study, the prevalence of impacted teeth and related pathologic conditions (dental caries in adjacent teeth, root resorption of adjacent teeth and pericoronal cystic & tumoral lesions) were evaluated.

**Step 2:**

In prospective survey, the frequency of some anomalies that required both clinical and radiographic evaluation was assessed.

These anomalies included missing teeth (anodontia, hypodontia and oligodontia); structural anomalies (dentinogenesis imperfecta, dentin dysplasia and amelogenesis imperfecta) and shape anomaly (talon cusp).

We originally obtained the approval of the ethical board of the institutional ethics committee of Guilan University of Medical Sciences Research Foundation in Rasht, Iran, before conducting this investigation (Ethics Approval Number 1367) to ensure our compliance with the recommendations of the Declaration of Helsinki and Tokyo for humans. Accordingly, our protocol complied with these guidelines. Moreover, we obtained written consent of the participating patients to use their panoramic images for this study.

The data were collected and statistically analyzed using Chi-square test, Fisher-exact test, Independent t-test and Kappa in SPSS version 16 soft ware. Confidence interval in the all analysis was %95.

Figures 1 and 2 reveal two dental anomalies that were detected in the present study.

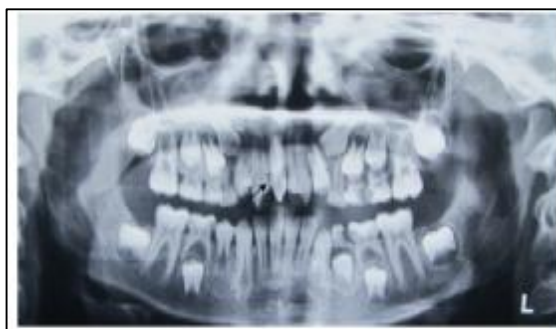

Figure 1. Erupted mesiodense in the anterior portion of the maxilla

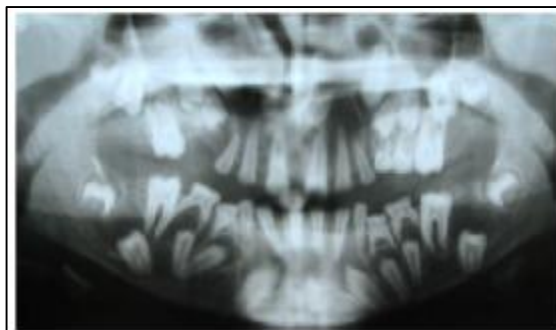


Figure 2. A case of hypoplastic type of amelogenesis imperfecta. Note to the square shape crown of teeth, spacing between teeth (picket fence appearance) and the enlargement of the follicular spaces in some portions.

## Results

### Step 1:

In this study, 32.4% (396) of 1224 subjects had at least one developmental anomaly and 23.3% (285) had at least one acquired dental anomaly. Overall, 581 cases (47.5) had one anomaly (acquired or developmental). Sex distribution of dental anomaly was 208 males (38.1%) and 373 females (61.9%). Individuals with both acquired and developmental anomalies constituted 8.2% of the population.

The distribution and prevalence of the dental anomalies are provided in table 1. The most frequent dental anomaly was pulp stone (22.1%). Table 2 shows the prevalence of dental anomalies based on gender. Supernumerary teeth in men was 5 times greater than females ( $P=0.005$ ).

The prevalence of positional anomalies (impaction, transposition) was 16.7%, followed by the shape anomalies (dense invagination, dilaceration and taurodontism) (15.9%); size anomalies (microdontia) (3.8%); number anomalies (supernumerary teeth) (1.1%) and the acquired anomalies (pulp stone, internal root resorption and external root resorption) (23.3%). Among the developmental anomalies, impaction was the most common one (16.6%). Table 3 shows the prevalence of dental anomalies based on the involved jaws.

Comparison of dental anomalies based on unilateral or bilateral occurrence of the jaws, showed that 77.9% of dense invagination occurred bilaterally, that was statistically significant ( $P=0.0001$ ). Approximately, 69.8% of dense invaginations was found in Lateral maxillary teeth that was more than other teeth ( $P=0.0001$ ). Root dilacerations had the highest frequency in mandibular third molar (62.7%). Dilaceration of the mesial root had the most prevalent rate (52.6%, 40 teeth), followed by dilaceration of the distal root (19.7%, 15 teeth) and dilaceration of the both mesial and distal roots (15.8%, 12 teeth).

Maxillary third molar was the most frequent site for the presence of supernumerary teeth (8 cases, 50%). Followed by the maxillary central incisor (mesiodense) which was 25% (4 case), upper lateral incisor (2

cases, 12.5%), upper canine (1 case, 6.2%) and the lower third molar (1 case, 6.2%).

Supplemental supernumerary teeth (supernumerary tooth with normal size and shape) constituted 81.2%. Accordingly, 75% were impacted, 18.8% were rudimentary (supernumerary tooth with abnormal shape and small size) and 25% were erupted.

Taurodontism was seen in 6 patients (10 teeth). The maxillary first molars had the most prevalent rate (50%).

Impaction was observed in 320 teeth. The most frequent tooth was the maxillary third molar (45.3%), followed by the mandibular third molar (40.3%). Among the 320 impacted teeth, 96.3% were without lesions. The most common lesions were pericoronal related to the impacted teeth (1.9%, 6 teeth). Pulp stone was seen in 271 patients, which was the most frequent dental anomaly. The maxillary first molar was the most prevalent tooth (45.6%, 262 teeth,  $P=0.0001$ ). Table 4 shows the distribution and prevalence of pulp stone according to the involved teeth. The mean age of subjects without pulp stone was  $28.59 \pm 12.88$  years and the group with pulp stone,  $36.12 \pm 11.43$  years. Independent t-test showed that the difference between ages was 8 years which was statistically significant. ( $P=0.0001$ )

According to Kappa test, concomitant occurrence of the supernumerary teeth and microdontia ( $P=0.001$ ), and also between supernumerary teeth and external root resorption ( $P=0.005$ ) was statistically significant. The external root resorption was observed in 9 patients (10 teeth). The mandibular first molar was the most frequent tooth (30%) with external root resorption ( $P=0.944$ ) and the mandibular first premolar was in the next order (20%). The internal root resorption was seen in 6 teeth. The most frequent tooth with internal root resorption was the maxillary lateral incisor (33.3%).

### Step 2:

In this step, 48, who were examined both clinically and radio graphically, had 106 missing teeth (3<sup>rd</sup> molars excluded). Oligodontia was found in 6 patients, and the

others had hypodontia. It was found that 60.4% of missing teeth was observed in the maxilla. The bilateral occurrence of missing was 74.5%. The missing anomaly was found in the maxillary lateral incisor (27.35%) greater than other teeth (Table 5).

Transposition was seen in 6 teeth of 4 patients. Two of them were between the maxillary lateral and canine and the other 4 cases were transposition of the maxillary canine and

the first premolar.

Talon cusp was detected in 4 teeth. 3 of them were related to the maxillary lateral incisor and one tooth was seen in the maxillary canine. Amelogenesis imperfecta was observed in 6 patients including brothers and sisters 2 each, and 2 other non-familial female cases. Dentine dysplasia was only found in an 18 years-old female.

**Table 1. The prevalence of development and acquired dental anomalies**

Dental anomaly	NO (%)	Supernumerary	Dilac1	Dense Invag2	Microdo3	Tauro4	Transpos5	Imp6	Int RR7	Ext RR8	Pulp stone
Yes	No (%)	13 (1.1)	62 (5.1)	133 (10.9)	47 (3.8)	6 (0.5)	1 (0.1)	203 (16.6)	6 (0.5)	9 (0.7)	271 (22.1)
No	No (%)	1211 (98.8)	1162 (94.9)	1091 (89.1)	1177 (96.2)	1218 (99.5)	1223 (99.9)	1027 (83.4)	1218 (99.5)	1215 (99.3)	953 (77.9)
Total	No (%)	1224 (100)	1224 (100)	1224 (100)	1224 (100)	1224 (100)	1224 (100)	1224 (100)	1224 (100)	1224 (100)	1224 (100)

1: Dilaceration; 2: Dens Invagination; 3: Microdentia; 4: Taurodontism; 5: Transposition; 6: Impaction; 7: Internal root resorption; 8: Internal root resorption

**Table 2. Distribution and prevalence of dental anomalies based on gender**

Gender	NO (%)	Super numerary	Dense invag	Dilac	Taurodo	Microdo	Imp	Transpos	Pulp stone	Ext RR	Int RR
Male	No (%)	10 (2.1)	50 (10.7)	27 (5.8)	3 (0.6)	1 (3.9)	78 (16.7)	0 (%)	83 (17.8)	6 (1.3)	3 (0.6)
Female	No (%)	3 (0.4)	83 (10.9)	35 (4.6)	3 (0.4)	29 (3.8)	125 (16.5)	1 (0.1)	188 (24.8)	3 (0.4)	3 (0.4)
Total	No (%)	13 (1.1)	133 (10.9)	62 (5.1)	6 (0.5)	47 (3.8)	203 (16.6)	1 (0.1)	271 (22.1)	9 (0.7)	6 (0.5)
P- value		0.005*	0.904	0.362	0.416	0.974	0.910	0.619	0.004*	0.079	0.416

\* P<0.05 is considered to be significant

**Table 3. Distribution and prevalence of dental anomalies based on involved jaws**

jaw	NO (%)	Supernumerary	Dense invag	Dilac	Taurodo	Microdo	Imp	Transpos	Pulp stone	Ext RR	Int RR
Max	No (%)	15 (93.8)	285 (100)	-	5 (0.5)	51 (92.7)	175 (54.7)	1 (100)	325 (56.5)	-	4 (66.7)
Man	No (%)	1 (6.2)	0 (%)	75 (100)	5 (0.5)	4 (7.3)	145 (45.3)	0 (%)	250 (43.5)	10 (100)	2 (33.3)
Total	No (%)	16 (100)	285 (100)	75 (100)	10 (100)	55 (100)	320 (100)	1 (100)	575 (100)	10 (100)	6 (100)
P value		0.0001 *	0.0001 *	-	1	0.0001*	0.094	-	0.0001*	-	0.688

\* Pvalue is statistically significant.

**Table 4. Location and prevalence of pulp stone**

Involved tooth	Pulp Stone	
	Tooth number	Percent (%)
Maxillary first molar	262	45.6
Maxillary second molar	162	28.2
Mandibular first molar	52	9
Mandibular second molar	46	8
Maxillary third molar	29	5
Mandibular third molar	17	3
Mandibular second premolar	4	0.7
Maxillary second premolar	3	0.5
Total	575	100

**Table 5. Location and frequency of missing teeth (excluding third molars)**

Involved tooth	Missing Tooth	
	Tooth number	Percent (%)
Maxillary lateral incisor	29	27.3
Mandibular second premolar	16	15.09
Maxillary second premolar	14	13.2
Maxillary first premolar	13	12.2
Mandibular laterd incisor	8	7.5
Mandibular central incisor	8	7.5
Mandibular first premolar	6	5.6
Mandibular canine	4	3.7
Maxillary second molar	4	3.7
Maxillary canine	4	3.7
Total	106	100

## Discussion

Several studies<sup>(4,6)</sup> have determined the prevalence of dental anomalies among Iranian population. There was a significant difference between the prevalence of dental anomalies observed in the present study and those reported in the previous studies<sup>(4,6)</sup>. These differences can be explained primarily by the influences of the different races, local environment and nutrition.<sup>(5)</sup>

In the present study, the positional anomalies occurred predominantly. In Gupta et al.<sup>(5)</sup>, the most frequent dental anomaly was the positional one. It should be noted that in their study<sup>(5)</sup>, impaction, rotation and ectopic eruption were considered as the positional anomalies. In the present study, the positional anomalies consisted of impaction and transposition. In Gupta et al. rotation was the most frequent anomaly among the positional anomalies but, in the present study, impaction

was the most common anomaly between the positional types.

The prevalence of the supernumerary teeth was 1.1%. This result is similar to the previous studies.<sup>(1,7,8)</sup> Nayak and co-worker<sup>(9)</sup> reported a total prevalence rate of 0.6% for supernumerary teeth in Indian population, which was lower than our study. This dissimilarity can be explained primarily by selection of the children as a study group and in this age range, the development of the some supernumerary teeth probably had not been started. The prevalence of supernumerary teeth was 0.5%<sup>(10)</sup>, 2.4%<sup>(4,5)</sup> and 14%<sup>(11)</sup>; in other words, varied in different studies. The comparison of the results of the present study with the ones on Iranian populations<sup>(4,6)</sup> shows that the prevalence rate in ours is lower. This difference can be attributed to the dissimilarity in study design, sample selection criteria, racial and nutritional differences, sampling techniques and inclusion criteria. In the present study, the prevalence of supernumerary teeth in men was 5.25 times more than women that was similar to the previous findings.<sup>(3, 6,12,13)</sup>

In the present study, a total prevalence rate of microdontia was 3.8% which confirmed the previous findings<sup>(1,5,14)</sup>. However, Guttal et al<sup>(3)</sup> in Indian population reported the prevalence rate of 0.16% for microdontia, which is much lower than ours. The prevalence rate ranges from 0.8% to 8.4%.<sup>(15)</sup>

Dense invagination was observed in 10.9% of the patients. This result is not in agreement with the previous studies<sup>(4, 6, 14)</sup>. The most frequent cases of dense invagination were bilateral (77.9%) and all of them were detected in maxilla and mainly in lateral incisor.

The prevalence of taurodontism in the present study was 0.5% confirming previous researches<sup>(4, 16)</sup> but higher in some other studies.<sup>(5, 6, 14, 17, 18)</sup>

In the present study, root dilaceration was observed in 5.1% of subjects. The previous studies<sup>(4,6,19,20)</sup> reported various results. Ezoddini et al<sup>(6)</sup> reported even higher rate. The lower rate of root dilacerations in our study in comparison to Ezoddini et al. can be related to the fact that, we evaluated only the mandibular teeth for detecting dilacerations and the

maxillary teeth for preventing misinterpretation in radiography, were excluded. The most frequent tooth with dilaceration was mandibular third molar. Dilacerations of the mandibular third molars had the highest prevalence rate in Malcic et al.<sup>(21)</sup> It should be noted that, delay eruption, endodontic problems or difficulties during extraction had been reported about dilacerated teeth. Hence, early diagnosis could prevent the future problems.<sup>(19)</sup>

In the current study, the most frequent impacted teeth from the highest to the lowest frequency were the maxillary third molar, mandibular third molar, maxillary canine, mandibular second premolar, mandibular canine, maxillary second premolar, maxillary first premolar and mandibular second molar, confirming the previous studies<sup>(2)</sup>.

Transposition was found to be 0.1% in our study which is similar to the previous studies<sup>(14,22,23)</sup>. Accordingly, the total prevalence rate of pulp stone was 22.1%, which was the most frequent dental anomaly. Ahanagari et al.<sup>(24)</sup> reported the prevalence rate of 5.7%. In the present study, pulp stone had significant predilection to females, which was in agreement of Ahanagari et al. research.

In our study, the mean difference of the age of the patients with pulp stone was 8 years greater than the patients without it. Therefore it can be concluded that the prevalence of this acquired dental anomaly in older patients is higher. As mentioned previously, in the present study, we prospectively evaluated some patients both clinically and radiographically.

Missing teeth was observed in 106 teeth excluding the third molars and 6 cases were accompanied with oligodontia, and the others with hypodontia. The maxillary lateral incisor was the most frequent missing tooth, followed by the mandibular second premolar, confirming the previous studies.<sup>(3,12,19)</sup> Also, it was found that 60.4% of missing teeth were in the maxilla and 74.5% were bilateral.

In the present study, talon cusp was observed in only 4 teeth. The previous study reported variable frequency of talon cusps (1% to 8%). The most frequent cases have been reported in maxilla as well as maxillary permanent lateral incisors in most cases<sup>(25)</sup>. Juan

et al. have emphasized that early diagnosis of talon cusp is highly important to prevent some problems such as occlusal interference, caries and periapical pathosis, and the periodontal problems.<sup>(26)</sup>

A rare finding depicted in the present study was a case of dentin dysplasia type I (radicular type). It was an 18 year old female complaining of tooth mobility and dental caries. There was not any history of the permanent teeth extraction. She noted that some of the teeth were lost spontaneously, because of the mobility. On panoramic view, missing some teeth and impaction of the others were revealed. Characteristic findings were short roots or rootless teeth in almost all teeth. Other interesting findings were detection of 6 cases of hypo plastic amelogenesis imperfecta.

Some of the limitations of the present study were unfeasibility of recalling the patients for clinical evaluation of the patients in step 1 of this study. Therefore, further prospective investigations regarding the dental anomalies using both the clinical and

radiological examinations (preferably full mouth radiographic series) with larger sample size, are necessary in Guilan population.

In addition, more investigations are recommended to evaluate the correlation of familial and genetical background as well as the relationship between cleft lip and palate; and different syndromes with these anomalies.

## Conclusion

In this present study, pulp stone had the most prevalence rate among the total anomalies. This anomaly occurred in the maxillary first molars as the most common location. Pulp stone in females was 7% more than in males. Among the developmental anomalies, impaction was the most frequent anomaly. Among permanent teeth, the maxillary third molars had the most prevalence rate.

## Acknowledgement

The authors would like to thank the department of Dentomaxillofacial Radiology, Oral medicine and Pediatrics for their contribution for gathering the data.

## References

1. Konjhodžić-Raščić H, Vuković A, Zukić S, et al. Dental Anomalies among Students of Faculty of Dentistry University of Sarajevo. *Acta Medica Academica* 2006; 35:23-29.
2. White SC, Pharaoh MJ. *Oral radiology: principles and interpretation*. 6th ed .St. Louis :Mosby; 2009. pp. 295-322.
3. Guttal KS, Naikmasur VG, Bhargava P, Bathi RJ. Frequency of Developmental Dental Anomalies in the Indian Population. *Eur J Dent* 2010; 4(3):263-269.
4. Ghabanchi J, Haghnegahdar AA, Khodadazadeh Sh, Haghnegahdar S. A Radiographic and Clinical Survey of Dental Anomalies in Patients Referring to Shiraz Dental School. *Shiraz Univ Dent J* 2010; 10: 26-31.
5. Gupta SK, Saxena P, Jain S, Jain D. Prevalence and distribution of selected development dental anomalies in an Indian population. *J oral sci* 2011; 53(2): 231-238.
6. Ezoddini Ardakani F, Sheikha M.H, Ahmadi H. Prevalence of dental developmental anomalies: a radiographic study. *Community Dent Health* 2007; 24(3):140-144.
7. Zhu JF, Marcushamer M, King DL, Henry RJ. Supernumerary and congenitally absent teeth: a literature review. *J Clin Pediatr Dent* 1996; 20:87-95.
8. Kazanci F, Celikoglu M, Miloglu O, et al. Frequency and distribution of developmental anomalies in the permanent teeth of a Turkish orthodontic patient population. *Journal of Dental Sciences* 2011; 6(2):82-89.
9. Nayak P, Nayak S. Prevalence and distribution of dental anomalies in 500 Indian school children. *BJMS*.2011; 10(1):41-44.
10. Salem G. Prevalence of selected dental anomalies in Saudi children from Gizan region. *Community Dent Oral Epidemiol* 1989; 17(3): 162-163.
11. Onyeaso CO, Onyeaso AO. Occlusal/dental anomalies found in a random sample of Nigerian school-children. *Oral Health Prev Dent* 2006; 4:181-186.
12. Salcido-garcía JF, Ledesma-montes C, Hernández-flores F, et al. Frequency of supernumerary teeth in Mexican population. *Med Oral Patol Oral Cir Bucal* 2004; 9:403-409.
13. Liu PK, Sew WK. A controlled study of the association of various dental anomalies with hypodontia of permanent teeth. *Pediatr Dent* 1995; 11(4): 291-296.

14. Ghaznawi HI, Daas H, Salako NO. A clinical and radiographic survey of selected dental anomalies and conditions in a Saudi Arabian population. *Saudi Dent J* 1999; 11:8-13.
15. Neville BW, Damm DD, Allen CM, Bouquot JE. *Oral and maxillofacial pathology*. 3rd ed. Philadelphia: W.B. Saunders; 2009. pp: 49-106.
16. Bürklein S, Breuer D, Schäfer E. Prevalence of Taurodont and Pyramidal Molars in a German Population. *J Endod* 2011; 37(2): 158-162.
17. Thongudomporn U, Freer TJ. Prevalence of dental anomalies in orthodontic patients. *Aust Dent J* 1998; 43: 395-398.
18. Darwazeh AM-G, Hamasha AA-H, Pillai K. Prevalence of taurodontism in Jordanian dental patients. *Dentomaxillofac Radiol* 1998 ; 27:163-165.
19. Afify A R, Zawawi K H. The Prevalence of Dental Anomalies in the Western Region of Saudi Arabia. *ISRN Dentistry* 2012; 1-5 (article ID: 837270).
20. Hamasha AA, Al-Khateeb T, Darwazeh A. Prevalence of dilacerations in Jordanian adult. *Int Endod J* 2002; 35: 910-912.
21. Malcic A, Jukic S, Brzovic V, et al. Prevalence of root dilaceration in adult dental patients in Croatia. *Oral Surg Oral Med Oral Pathol Oral Radiol Endod* 2006; 102: 104-109.
22. Celikoglu M, Miloglu O, Oztek O. Investigation of tooth transposition in a non-syndromic Turkish Anatolian population: characteristic features and associated dental anomalies. *Med Oral Patol Oral Cir Bucal* 2010; 15(5):716-720.
23. Yilmaz HH, Türkkahraman H, Sayn MO. Prevalence of tooth transpositions and associated dental anomalies in a Turkish population. *Dentomaxillofac Radiol* 2005; 34(1):32-35.
24. Ahangari Z, Taheri JB, Shaffar Soleimanpoor F. *Beheshti Univ Dent J* 2003; 20(4) :428-434.
25. Dash JK, Sahoo PK, Das SN. Talon cusp associated with other dental anomalies: a case report. *Int J Paediatr Dent* 2004; 14:295-300.
26. Juan JS, Jiménez-Rubio A. Talon cusp affecting permanent maxillary lateral incisors in 2 family members. *Oral Surg Oral Med Oral Pathol Oral Radiol Endod* 1999; 88: 90-92.