

Case Report: Immediate Replacement of Periodontally Compromised Teeth Using Natural Tooth Pontic



Hossein Assarzadeh¹, Malihe Karrabi^{1*}, Zahra Baghani¹, Saeed Sabzevari²

1. Assistant Professor, Department of Oral and Prosthodontics, School of Medicine, Sabzevar University of Medical Sciences, Sabzevar, Iran.

2. Assistant Professor, Department of Periodontology, Prosthodontics, Oral & Maxillofacial Surgery, School of Dentistry, North Khorasan University of Medical Sciences, Bojnord, Iran.



Citation: Assarzadeh H, Karrabi M, Baghani Z, Sabzevari S. Immediate Replacement of Periodontally Compromised Teeth Using Natural Tooth Pontic. Journal of Dentomaxillofacial Radiology, Pathology and Surgery. 2018; 6(4):135-140.



Funding: See Page 138

Copyright: The Author(s)

Article info:

Received: 28 Jul 2017

Accepted: 05 Nov 2017

Available Online: 01 Jan 2018

Keywords:

Natural tooth pontic, Fiber reinforced composite, Adhesive, Bonding, Restoration

ABSTRACT

This article reports a case who was treated with immediate replacement of periodontally compromised mandibular incisors using the extracted incisors as a natural tooth pontic. Following extraction and root resection of the mandibular incisors, radicular pulp was cleaned and filled with composite resin and then bonded to adjacent teeth with fiber reinforced composite resin. This is a simple, economical, and conservative chair-side technique for periodontally compromised teeth using the patient's own extracted teeth and can be used as an interim or a definitive treatment.

1. Introduction

Dentists occasionally encounter a difficult aesthetic situation to remove an anterior tooth because of trauma, advanced periodontal disease, root resorption, or failed endodontic therapy [1]. Following loss of the anterior tooth, it is important to provide an immediate replacement in order to avoid aesthetic, masticatory, and phonetic difficulties, as well as maintaining the edentulous space [2]. Depending on clinical and economic factors, a course of treatment is decided upon by

the patient and dentist. The start of treatment depends on many factors and thus may require short to long temporization times [3].

Conservation, natural preservation, minimal invasion, aesthetic, and cost of treatment are some of the important factors that are considered when replacing a missing tooth. Also there issues of prosthesis biocompatibility, and oral hygiene maintenance [4]. Conventionally, the solution to this clinical problem has been the provision of a single tooth, removable temporary acrylic prosthesis, or resin-bonded bridges; each has its specific advan-

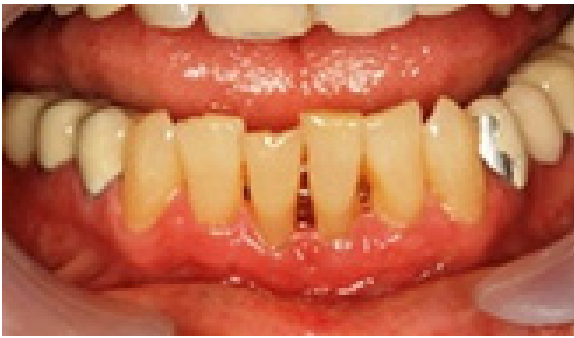* Corresponding Author:

Malihe Karrabi, PhD

Address: Department of Oral and Prosthodontics, School of Medicine, Sabzevar University of Medical Sciences, Sabzevar, Iran.

Tel: +98 (915) 1740641

E-mail: malih.karrabi@gmail.com



Journal of
Dentomaxillofacial
Radiology, Pathology and Surgery

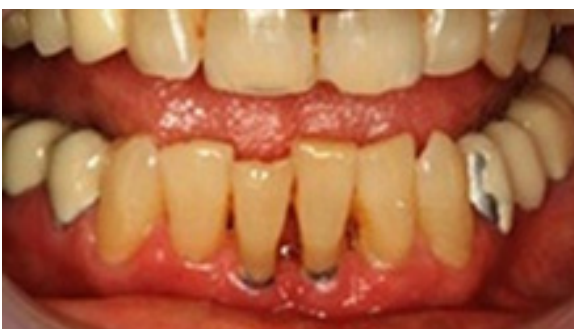Figure 1. Preoperative intraoral photograph of the periodontally compromised mandibular central incisors

tages and disadvantages in terms of usage, aesthetic, and compatibility [5-7].

Final restorations can be either removable prosthesis, tooth-supported prosthesis, or the increasingly popular implant-supported prosthesis [3]. Using the natural tooth as a pontic offers the benefits of the right size, shape and color. Moreover, the positive psychological value in using patient's natural tooth is an added benefit. When the crown of the tooth is in good condition, it can be temporarily and easily bonded to the adjacent teeth with light-cured restorative material [8, 9]. This paper describes clinical steps of natural tooth pontic as a restorative option for replacement of extracted periodontal compromised mandibular central incisor.

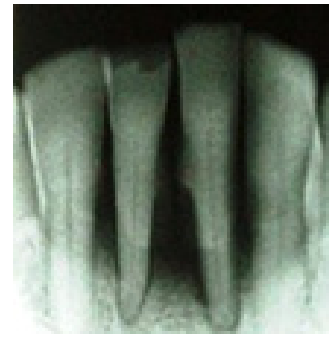2. Case Presentation

A 59-year-old man with complaint of gingival recession of mandibular central incisors was reported to dental school clinic. After clinical and radiographic examination, gingival recession and bone loss were revealed around mandibular central incisors (Figure 1 and 2). The crowns had the same color, shape, and translucency of the adjacent lateral incisors. The patient oral hygiene



Journal of
Dentomaxillofacial
Radiology, Pathology and Surgery

Figure 3. Intraoral photograph after tooth extraction



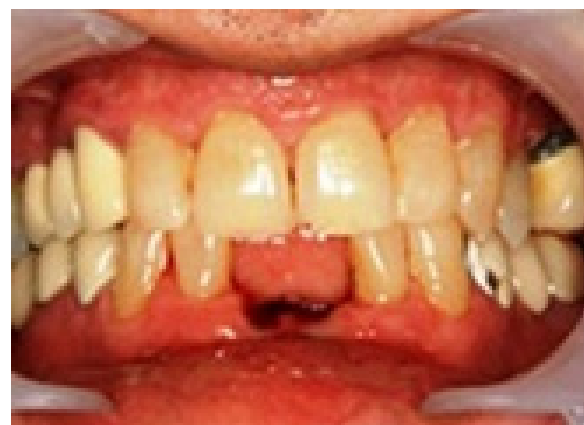Journal of
Dentomaxillofacial
Radiology, Pathology and Surgery

Figure 2. Radiographic view of periodontally compromised mandibular central incisors

was good but the prognosis of the tooth was poor, therefore it was decided to extract the teeth.

The patient was informed the final restoration that can be either removable prosthesis, tooth-supported prosthesis, or implant-supported prosthesis. Finally, because of economic problem and patient's concern about aesthetic, it was decided to use extracted teeth as a natural tooth pontics.

The teeth were extracted under infiltration anesthesia without much trauma to the alveolar bone (Figure 3). Following that, root resection was done just below the marked area at the level of entrance of the apical portion of the root to the gingiva (Figure 4). The radicular pulp tissue was removed and canal was filled with light cured flowable composite resin (Filtek Supreme flowable composite, 3M, ESPE, St. Paul, USA). A modified ridge lap design was given to the apical portion of pontics to facilitate both oral hygiene and appearance of emergence profile. Then, position of the natural pontics was tried. Afterwards, a groove were made on lingual portion of pontics.



Journal of
Dentomaxillofacial
Radiology, Pathology and Surgery

Figure 4. Root resection was done just below the marked area

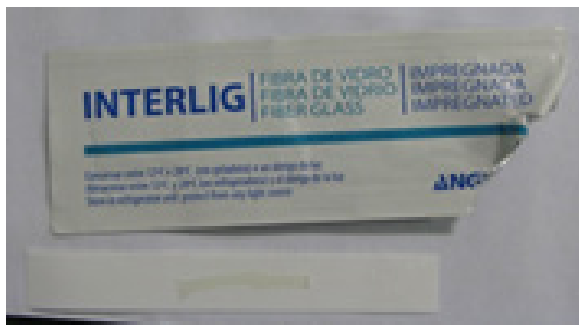


Figure 5. Impregnated fiber (Interlig, Angelus)

The extracted teeth and abutment teeth were cleaned with pumice, washed, and air dried. The proximal areas adjacent to the extraction site and approximately 3-4 mm of lingual surface were etched with 35% phosphoric acid for 20 seconds, then washed and air dried. The bonding agent (Adper Single Bond 2 Adhesive, 3M, ESPE, St. Paul, USA) was applied to the acid-conditioned surfaces and light cured. A dental floss was used to measure the necessary length of the fiber. Then, an appropriate length of the impregnated fiber (Interlig, Angelus, Londrina, PR, Brazil) was cut and checked for adaptation on lingual surface (Figure 5).

The pontics were positioned carefully in its correct site and stabilized with flowable composite that was placed in mesial and distal aspects of the labial surfaces of pontic and adjacent teeth and lingual surface of pontic and adjacent teeth. After that, the fiber was positioned on lingual surface on pontic and adjacent teeth, and light cured (Figure 6). Further layer of nanocomposite resin (Filtek Supreme, 3M, ESPE, USA) was placed over the fiber to ensure of its complete coverage by composite and then light cured for 40 seconds. Afterwards, finishing and polishing were done, and occlusal relationship was checked (Figure 7). Oral hygiene instructions were given to the patient and he was instructed to avoid exces-

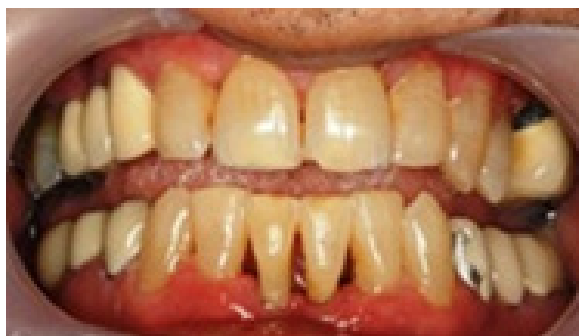


Figure 7. Frontal view of natural tooth pontic

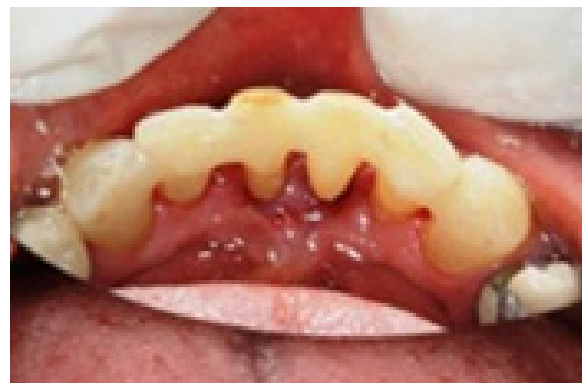

Figure 6. Pontics were fixed with flowable composite

sive chewing pressure or habits that could dislodge the natural tooth replacement. Follow up was done after 6 and 12 months [8].

3. Discussion

Immediate replacement of lost anterior teeth prevents psychological and social problem for the patient [4]. Various available treatment options include placement of natural crown or acrylic tooth in fixed prosthesis [2, 10] or removable prosthesis [11, 12], bridges [13], fiber-reinforced composite [14-16], and implants [17]. Dental implant is the first and the best option for such situations, but it is an expensive procedure and as a result less expensive treatment options should be considered [18].

Removable appliances or prostheses seem to be another suitable treatment option, but patient's compliance is generally a major problem, besides compromised aesthetic due to using canine clasps commonly used to provide stability and enhance retention. Moreover, partial removable dentures are frequently subject to fracture [4].

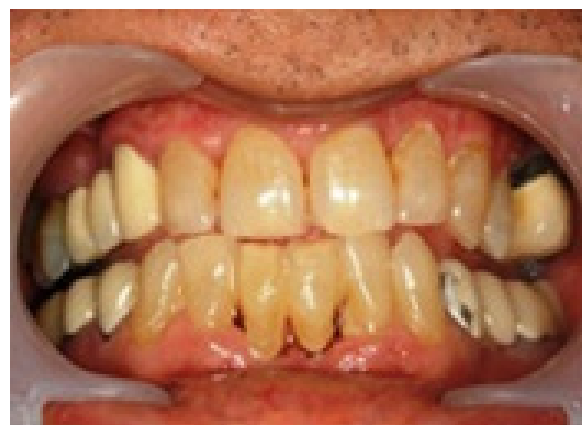

Figure 8. Follow up after 12 months

A conventional bridge requires preparation of healthy abutment teeth for crowns. Maryland bridges used for restoring a missing tooth require slot preparation in the abutment teeth to receive the retentive extensions of the wings of the pontic [13] and problems of debonding the cast metal framework from the luting cement or debonding of the luting cement from the enamel surface [14]. Fiber-Reinforced Composite (FRC) bridges are preferable to Maryland bridges in that very little or no tooth reduction is required. FRC bridges help in providing enhanced aesthetic concept [12], eliminates the need of performing complicated laboratory procedures and can be done as a chair-side replacement [14].

In this regard, using natural tooth as a pontic may offer several advantages over removable appliances, including better aesthetic, ease of use, and not accustomed to a removable prosthesis [19-21]. This approach would also permit utilization of a patient's natural crown as a pontic [22] for an immediate bridge, with little or no need to perform complicated laboratory procedures. Besides the use of resin composite to splint the pontic to neighboring sound teeth, it is also possible to use orthodontic wire or fiber splint [4].

This procedure is practical, economic, requires limited laboratory support and materials, and can be accomplished in a single appointment [23]. One major advantage of retaining the patient's natural crown is that, the patient can better tolerate the effect of tooth loss. Moreover, it provides the optimal pontic in terms of shape, color, size, and alignment [6]. This particular design allows for exact repositioning of the coronal part of the extracted tooth in its original intraoral three-dimensional position [23]. In this case, shape of natural tooth pontic was given as modified ridge lap pontic with a well-polished, smooth, and convex surface that results in pressure-free [24] or mild contact with the alveolar ridge over a very small area for a better preservation of the soft tissue health [25].

These pontics can be attached to the adjacent teeth with adhesive composite resins, wire, metal mesh, nylon mesh, and cast metal frameworks. The inherent problems with these materials like placing a tooth pontic fixed to the adjacent teeth were their inability to be chemically incorporated into the dental resin. Clinical failures of these bridges were prevalent because these materials could not support the repeated loading stresses placed on the bridge during normal and parafunction.

The problem associated with the placement of composite resin splints with submerged wires and mesh grids

was that in order to protect against breakage, more bulk and thickness of composite resin was necessary [26, 27]. This overbulking of the restoration led to an increase in food and plaque retention resulting in more difficulty to clean around the restoration and maintaining good oral health. The challenge to place a thin but strong, bonded composite resin-based bridge was met with the introduction of a high-strength, bondable, biocompatible, aesthetic, easily manipulated, fiber ribbons that could be embedded into a resin structure [28].

4. Conclusion

Natural tooth crown pontic is a simple and cost-effective treatment option for the tooth replacement, using its own natural coronal portion. It can be considered a long-term provisional treatment, while providing superior aesthetics and function. This chair-side technique does not require laboratory involvement, is noninvasive and reversible, so that all traditional treatment options for single tooth replacement remain open. However, this procedure is highly operator-dependent and demands appropriate case selection and precise technique.

Ethical Considerations

Compliance with ethical guidelines

This study was performed with informed consent in operative department of Dental School of Shahid Sadooghi University of Medical Sciences.

Funding

This research did not receive any specific grant from funding agencies in the public, commercial, or not-for-profit sectors.

Conflict of interest

The authors declared no conflict of interest.

References

- [1] Avinash S, Jagadish S. Natural tooth pontic- a case report. *Endodontology*. 2007; 1:17-18.
- [2] Ulusoy AT, Cehreli ZC. Provisional use of a natural tooth crown following failure of replantation: A case report. *Dental Traumatology*. 2008; 24(1):96-9. [DOI:10.1111/j.1600-9657.2006.00486.x]

- [3] Stumple LJ. The natural tooth pontic; simplified. *Journal of California Dental Association*. 2004; 32(3):257-60.
- [4] Parolia A, Shenoy KM, Thomas MS, Mohan M. Use of a natural tooth crown as a pontic following cervical root fracture: A case report. *Australian Endodontic Journal*. 2010; 36(1):35-8. [DOI:10.1111/j.1747-4477.2009.00174.x]
- [5] Daly CG, Wilkinson EJ. Use of patient's natural crown as the pontic in a composite resin-retained temporary bridge. *Australian Dental Journal*. 1983; 28(5):301-3. [DOI:10.1111/j.1834-7819.1983.tb02489.x]
- [6] Ashley M, Holden V. An immediate adhesive bridge using the natural tooth. *British Dental Journal*. 1998; 184(1):18-20. [DOI:10.1038/sj.bdj.4809530]
- [7] Safirstein JJ, Owens BM, Swords RL. The resin retained natural tooth pontic: A transitional esthetic solution. *Journal of Tennessee Dental Association*. 2001; 81(2):31-3. [PMID]
- [8] Rudraprasad CA, Nandeeshwa DB. Natural tooth pontic: A temporary immediate provisional for a difficult esthetic situation. *Journal of Indian Prosthodontic Society*. 2008; 8(2):122-5. [DOI:10.4103/0972-4052.43644]
- [9] Bhargava S, Namdev R, Dutta S, Tiwari R. Immediate fixed temporarization with a natural tooth crown pontic following failure of replantation. *Contemporary Clinical Dentistry*. 2011; 2(3):226-9. [DOI:10.4103/0976-237X.86468]
- [10] Kitasako Y, Ikeda M, Burrow MF, Tagami JA. A technique using resin composite with orthodontic wire to replace a missing tooth rapidly. *Dental Traumatology*. 2008; 24(1):127-30. [DOI:10.1111/j.1600-9657.2006.00505.x]
- [11] Tuzuner T, Kusgoz A, Nur BG. Temporary management of permanent central incisors loss caused by trauma in primary dentition with natural crowns: A case report. *Dental Traumatology*. 2009; 25(5):522-6. [DOI:10.1111/j.1600-9657.2009.00794.x]
- [12] Oliveira LB, Tamay TK, Oliveira MD, Rodrigues CR, Wanderley MT. Human enamel veneer restoration: An alternative technique to restore anterior primary teeth. *Journal of Clinical Pediatric Dentistry*. 2006; 30(4):277-9. [DOI:10.17796/jcpd.30.4.f07k700m45g29414]
- [13] Parker RM. An ultraconservative technique for restoring a missing central incisor. *Contemporary Esthetics*. 2007; 7:30-4.
- [14] Aydin Y, Kargul B. Glass-Fiber Reinforced composite in management of avulsed central incisor: A case report. *Journal of Dentistry for Children*. 2004; 71(1):66-8.
- [15] Chafaie A, Portier R. Anterior Fiber-reinforced Composite Resin Bridge: A case report. *Pediatric Dentistry*. 2004; 26(6):530-4. [PMID]
- [16] Chauhan M. Natural tooth pontic fixed partial denture using resin composite-reinforced glass fibers. *Quintessence International*. 2004; 35(7):549-53. [PMID]
- [17] Ticheler HM, Abraham JE. Management of a congenitally missing maxillary central incisor. A case study. *New York State Dental Journal*. 2007; 73(2):20-2.
- [18] Moezizadeh M. Natural tooth pontic in periodontally compromised tooth. *International Journal Dental Case Reports*. 2011; 1(3):20-4.
- [19] Nakamura M, Nogawa H. Eleven-year clinical performance of a mandibular natural tooth pontic bonded with modified tri-n-butylborane initiated adhesive resin. *Journal of Oral Science*. 2015; 57(4):385-8. [DOI:10.2334/josnusd.57.385]
- [20] Jr.Fahl N. Restoration of the maxillary arch utilizing a composite resin buildup and a fiber framework. *Practical Periodontics and Aesthetic Dentistry*. 1998; 10(3):363-7. [PMID]
- [21] Smidt A. Esthetic provisional replacement of a single anterior tooth during the implant healing phase: A clinical report. *Journal of Prosthetic Dentistry*. 2002; 87(6):598-602. [DOI:10.1067/mpr.2002.123231]
- [22] Belli S, Ozer F. A simple method for single anterior tooth replacement. *Journal of Adhesive Dentistry*. 2000; 2(1):67-70. [PMID]
- [23] Dimaczek B, Kern M. Long-term provisional rehabilitation of function and esthetics using an extracted tooth with the immediate bonding technique. *Quintessence International*. 2008; 39(4):283-8. [PMID]
- [24] Stein RS. Pontic-residual ridge relationship: A research report. *Journal of Prosthetic Dentistry*. 1966; 16(2):251-85. [DOI:10.1016/0022-3913(66)90080-1]
- [25] Edelhoff D, Spiekermann H, Yildirim M. A review oeshetic pontic design options. *Quintessence International*. 2002; 33(10):736-46. [PMID]
- [26] Strassler HE, Haeri A, Gultz JP. New-generation bonded reinforcing materials for anterior periodontal tooth stabilization and splinting. *Journal of Dental Clinic of North America*. 1999; 43(1):105-26.
- [27] Pollack RP. Non-crown and bridge stabilization of severely mobile, periodontally involved teeth. A 25-year perspective. *Journal of Dental Clinic of North America*. 1999; 43(1):77-103.
- [28] Strassler HE, Taler D, Sensi L. Single visit natural tooth pontic bridge with fiber reinforcement ribbon. *Oral Health Journal*. 2007; 24-36.

