

# In vitro Comparison of Conventional Film and Direct Digital Radiography in Proximal Caries Detection

## Original Article

Seiedeh Tahereh Mohtavipour<sup>1</sup>, Fatemeh Shahsavari<sup>2</sup>,  
Alieh Sadat Javadzadeh Haghighat<sup>1</sup>, Seiedeh Saeideh  
Mohtavipour<sup>3</sup>, Milad Malekshoar<sup>4</sup>

<sup>1</sup> Assistant Professor, Oro-maxillofacial developmental diseases research center, Department of Oral and Maxillofacial Radiology, Guilan University of Medical Sciences, Dental Faculty, Rasht, Iran

<sup>2</sup> Assistant Professor, Department of Oral & Maxillofacial Pathology, Dental Branch, Islamic Azad University, Tehran, Iran

<sup>3</sup> Postgraduate Student, Department of Pediatric Dentistry, Shahid Beheshti University of Medical Sciences, Dental Faculty, Tehran, Iran

<sup>4</sup> Dentist, Rasht, Department of Oral and Maxillofacial Radiology, Guilan University of Medical Sciences, Dental Faculty, Rasht, Iran

**Received:** Jan 9, 2012

**Accepted:** Jul 17, 2012

### **Corresponding Author:**

**Seiedeh Tahereh Mohtavipour, DDS**

**Address:** Oro-maxillofacial developmental diseases research center, Department of Oral and Maxillofacial Radiology, Guilan University of Medical Sciences, Dental Faculty, Rasht, Iran

**Telephone:** +98-131-3263621-22

**Fax:** +98-131- 7225583

**E-mail:** [s.t\\_mohtavipour@yahoo.com](mailto:s.t_mohtavipour@yahoo.com)

## **Abstract**

**Introduction:** Various systems for intraoral digital radiography have been available as an alternative to film-based radiography. In consideration of several advantages of digital radiography such as less patient absorbed dose, manipulation of image quality and elimination of processing, it has been extensively used in different fields of dentistry in recent years. The purpose of this study was comparison of conventional film and digital radiography in the proximal caries diagnosis.

**Materials and Methods:** In this in vitro study, 60 extracted premolar teeth were selected and mounted in acrylic blocks. The teeth were radiographed using F-speed film and a complementary metal oxide semiconductor digital sensor (CMOS). Two observers evaluated interproximal surfaces for detection of presence and extent of caries. True caries depth was determined by histological examination. The diagnostic accuracy of each radiographic system were assessed by means of receiver operating characteristic curve (ROC) analysis.

**Results:** There was no significant difference between two imaging modalities. The AZ values in cases without caries and dentinal caries were greater than caries restricted to enamel and Dentino Enamel Junction (DEJ). The differences among observers also were not statistically significant.

**Conclusion:** Both imaging modalities were comparable in the detection of proximal carious lesions.

**Key words:** •Dental caries •Dental, Radiography, Digital •Film

## Introduction

Intraoral radiography has made a significant contribution as a diagnostic aid in detection of carious lesions. Conventional dental film is the most widely used image receptor for intraoral radiography.<sup>(1)</sup> Radiographic film manufactures continually attempt to produce faster film without decreasing image quality in order to reduce radiation exposure.<sup>(2)</sup> The introduction of digital radiography provides various possibilities of manipulating the radiographic image and allowing the image to be easily obtained stored and transmitted.<sup>(3-5)</sup>

Since the introduction of the first direct digital system in 1987, a variety of this system has become available in dentistry.<sup>(2,6)</sup>

Caries diagnosis is a challenging task even with radiographs.<sup>(7)</sup> But in clinical caries care, radiographs are an essential addition to the visual inspection of the teeth.<sup>(2)</sup>

In recent years, numerous studies have evaluated different digital imaging systems with respect to caries detection. The majority of these studies found the diagnostic accuracy of conventional films and digital images to be comparable.<sup>(1,3,6,8-16)</sup> CMOS (complementary metal oxide semiconductor) digital sensors are silicon-based but the technology is less expensive than that used in the manufacturing of CCDs (charge-coupled device). So, several manufacturers are currently using this technology for intraoral imaging applications.<sup>(17)</sup> However, there were limited studies especially about CMOS digital sensors as the basis of caries depth.<sup>(1,8)</sup> Every new system should be investigated to guarantee that its performance at least equals the preceding available modalities.<sup>(13)</sup>

The aim of this study was to compare the diagnostic accuracy of the recently introduced F-speed film and a CMOS based sensor in the detection of proximal caries with respect to caries depth.

## Materials and Methods

In this study, 60 extracted human premolars were selected on the basis of varying caries depth. Premolar teeth extracted on orthodontic indications were used because we could find sound surfaces and small caries between

them. The teeth were evaluated clinically and radiographically for the presence of proximal caries. The roots of the teeth were embedded in plaster and arranged in groups of four. In each block, we used two selected premolars; one canine and one molar tooth for making proximal contact surface, but only premolars were considered in this study. A total of 120 proximal surfaces were available, including surface with no decay and with carious lesions of varying depth. An apparatus was fabricated to allow for a constant spatial relationship among the x-ray source, the teeth and the receptor (Figure 1). The angulation and position of central ray was fixed bringing the the sensor against a ring of film holder (RWT, regular, Ellwangen, Germany) by the end of the PID (the position indicating device). The distance from the sensor to film /sensor was 40cm. A 0.5cm thick glass plate was used for the simulation of x-ray absorbing and scattering properties of soft tissue cheek. The teeth were imaged with both conventional and digital technologies. The conventional radiographs were obtained using F-speed film (flow x-ray, FV-58, NY, USA) whereas the digital images using CMOS sensor (Schick, Long Island, NY, USA). Both recording devices were exposed to x-rays generated by a planmeca unit (Planmeca, Helsinki, Finland) operating at 70 kvp and 8 mA. The optimal exposure time for each radiographic method was established during a pilot study.



**Figure 1.** Prefabricated apparatus for positioning of image receptor and PID

Two oral and maxillofacial radiologists with at least 8 years of experience independently evaluated all the images. The film based radiographs were interpreted using a conventional view box, which was masked to remove all ambient light around the radiographs. Images from digital system were displayed on a 17 inch monitor (Ben Q, Taipei, Taiwan) with a resolution of 1024×768 and a grayscale of 0-255. (Figure 2) Digital images were displayed and evaluated employing CMOS software. Observers viewed the images and recorded their diagnosis using ordinal caries depth rating scales: 0=no caries, 1=caries restricted to enamel; 2=caries reaching to the dentino-enamel junction; 3=caries extending into the dentin.

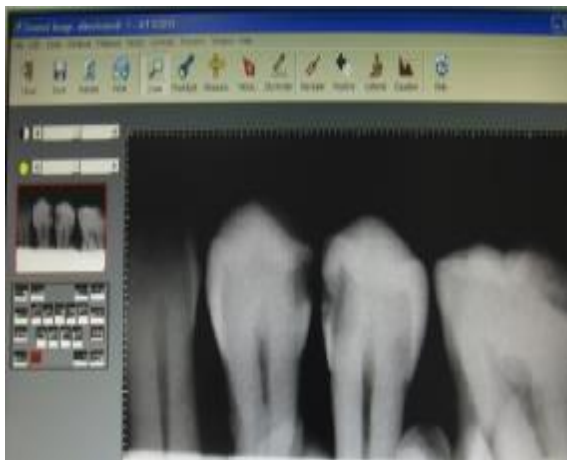


Figure 2. An example of a digital image evaluated in the study

After imaging, the teeth were sectioned with a low speed diamond saw (Mecatome T 2011, Persi, France) and examined less than 16× magnification stereomicroscope (Olympus SZ X12, Tokyo, Japan) by an oral and maxillao-facial pathologist familiar with the microscopic appearance of carious lesion. The teeth sections were evaluated for the absence or presence of proximal caries, as well as for the depth of the lesions.

### Data Analysis

Receiver operating characteristic (ROC) analysis was used to assess the diagnostic accuracy of the imaging modalities. The areas under the ROC curves (AZ) were analyzed by pairwise comparison. One-way analysis of

variance(ANOVA) was conducted to compare the diagnosis of observers. Wilcoxon single ranks test was used for intra observer agreement.

## Results

In the present in vitro study, histological examination of the teeth confirmed that 53 surfaces were caries free; 25 had caries lesions limited to the enamel; 12 had carious lesions restricted to the DEJ and 30 had carious lesions extending into the dentin.

An evaluation of intra observer agreement using Wilcoxon signed ranks test showed a high reliability and there was no statistically significant difference at the 95% confidence interval ( $P>0.05$ ).

According to ANOVA analysis, no statistically significant difference was found between observers ( $P>0.05$ ).

There was no statistically significant difference in the performance of two imaging modalities in the 95% confidence interval according to pairwise comparison of AZ values ( $P=0.9487$ ).

Areas under the ROC curve ( $A_z$ ) and standard errors for two imaging modalities without considering depth of lesion are shown in table1. Figure 3 illustrates the ROC curve for radiographic methods. Table 2 and 3 report  $A_z$  values for different depth of caries separately.

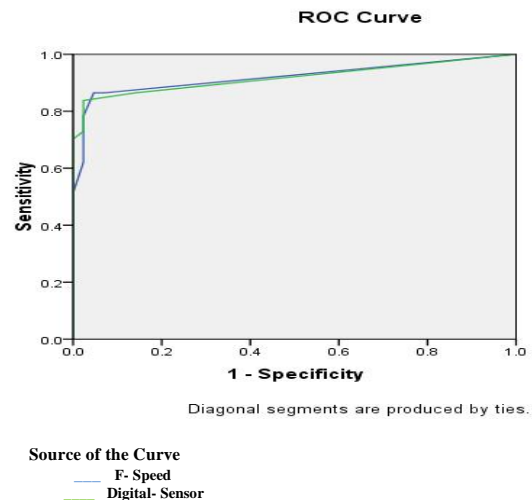


Figure3. Receiver operating characteristic analysis for the detectability of all carious lesions

**Table 1. Mean of the areas under the ROC curve (AZ)**

Receptor	Area	Confidence Interval Upper Bound
F-speed film	0.920	0.99
Digital sensor	0.918	0.99

**Table 2. Mean of the areas under the ROC curve in digital sensors**

Depth of caries	Area	Confidence Interval Upper Bound
No caries	0.863	0.95
Enamel	0.580	0.87
DEJ	0.494	0.90
Dentin	0.800	0.92

**Table 3. Mean of the areas under the ROC curve in conventional films**

Depth of caries	Area	Confidence Interval Upper Bound
No caries	0.898	0.98
Enamel	0.493	0.75
DEJ	0.468	0.85
Dentin	0.783	0.90

## Discussion

Digital systems are becoming more available to dental practice. However, these systems need to provide images which are at least comparable to those of conventional film radiographs in order to replace the images obtained with the radiographic films.<sup>(3)</sup> In the present investigation, analysis of the data revealed no significant difference between the two imaging modalities. These findings were in agreement with those of Castro et al.<sup>(1)</sup> and Nair et al.<sup>(8)</sup>

Castro et al.<sup>(1)</sup> compared Schick CMOS sensor and Ektaspeed plus film (Eastman Kodak Co, Rochester, NY, USA) and Nair et al.<sup>(8)</sup> used CMOS sensor, Ektaspeed plus and insight film (Eastman Kodak Co, Rochester, NY, USA).

Nair et al.<sup>(8)</sup> saved digital images as uncompressed TIFF files and displayed using an imaging viewing program (TACT, verity software system, NY, USA), but in our study and castro et al.<sup>(1)</sup>, digital images displayed and viewed using Schick CDR software program.

In Alkurt et al.<sup>(2)</sup> there was no significant difference between F-speed (flow- x ray) film and direct digital imaging system for proximal caries diagnosis. However, digital images in their study were obtained by RVG

(Radiovisiography, Marne La vallee, France) digital system.

Receiver operating characteristic (ROC) analysis is well-established as a method of comparing the diagnostic accuracies of imaging system and will continue to be a reliable method. The areas under the ROC curve ( $A_z$  value) provide useful information to measure the accuracy of a diagnostic system.<sup>(2, 3,6 ,9,10,13,16)</sup>

In our study, the greatest values of  $A_z$  correspond to caries free surfaces and dentinal caries in both imaging modalities.

Caries restricted to enamel and DEJ were identified with lesser accuracy regardless of the imaging modality used. These findings are consistent with other studies reporting poor detection of incipient proximal caries.<sup>(1,3,8)</sup> In these studies, initial caries in the proximal surfaces were histologically visible in the enamel but were not radiographically detected. This also occurred in the present study. It has been reported that 40% demineralization of hard tissue is required before lesions are identified in radiographs.<sup>(1)</sup> Thus, a small decrease in density related to caries restricted to enamel may be not identifiable with any of radiographic modalities. Owing to the large size of the proximal surfaces of posterior teeth and the subtle mineral loss

initially presented by lesions on these surfaces, proximal caries on posterior teeth are usually difficult to visualize on radiographs.

## Conclusion

In conclusion, this study indicated that the overall diagnostic accuracy of F-speed film and digital images were comparable in the detection of proximal caries. In addition, both

imaging systems performed poorly in the detection of caries restricted to enamel and DEJ.

## Acknowledgement

We would like to thank vice chancellorship of dental school of Guilan University of Medical Sciences for confirming this research (Registration Number: 1282).

## References

1. Castro VM, Katz JO, Hardman PK, et al. In vitro comparison of conventional film and direct digital imaging in the detection of approximal caries. *Dentomaxillofac Radiol* 2007; 36: 138-142.
2. Alkurt MT, Peker I, Bala O, Altunkaynak B. In vitro comparison of four different dental x-ray films and direct digital radiography for proximal caries detection. *Operative Dentistry* 2007; 32: 504-509.
3. Rockenbach MI, Veek EB, da Costa NP. Detection of proximal caries in conventional and digital radiography: an invitro study. *Stomatologija* 2008; 10: 115-120.
4. van der Stelt PF. Better Imaging: the advantages of digital radiography. *J Am Dent Assoc* 2008; 139 Suppl: 7S-13S.
5. Wenzel A. Bitewing and digital bitewing radiography for detection of caries lesions. *J Dent Res* 2004; 83: 72-5.
6. Ulusu T, Bodur H, Odabas ME. In vitro comparison of digital and conventional bitewing radiographs for the detection of approximal caries in primary teeth exposed and viewed by a new wireless handheld unit. *Dentomaxillofac Radiol*. 2010; 39: 91-94.
7. White SC, Yoon DC. Comparative performance of digital and conventional images for detecting proximal surface caries. *Dentomaxillofac Radiol* 1997; 26: 32-8.
8. Nair MK, Nair UP. An in-vitro evaluation of Kodak Insight and Ektaspeed Plus film with a CMOS detector for natural proximal caries: ROC analysis. *Caries Res* 2001; 35: 354-359.
9. Tyndall DA, Ludlow JB, Platin E. A comparison of Kodak Ektaspeed Plus film and the Siemens Sidexis digital imaging system for caries detection using receiver operating characteristic analysis. *Oral Surg Oral Med Oral Pathol Oral Radiol Endod* 1998; 85: 113-8.
10. Syriopoulos K, Sanderink GC, Valdres XL, van der Stelt PF. Radiographic detection of approximal Caries: a comparison of dental films and digital imaging systems. *Dentomaxillofac Radiol* 2000; 29: 312-8.
11. Nair MK, Ludlow JB, May KN, et al. Diagnostic accuracy of intraoral film and direct digital images for detection of simulated recurrent decay. *Operative Dentistry* 2001; 26: 223-230.
12. Abreu M Jr, Mol A, Ludlow JB. Performance of RVGui sensor and Kodak Ektaspeed Plus film for proximal caries detection. *Oral surg Oral Med Oral pathol Oral Radiol Endod* 2001; 91: 381-5.
13. Khan EA, Tyndall DA, Ludlow JB, Caplan D. Proximal caries detection: Sirona Sidexis versus Kodak Ektaspeed Plus. *General Dentistry* 2005; 28: 43-8.
14. Senel B, Kamburoglu K, Uçok O, et al. Diagnostic accuracy of different imaging modalities in detection of proximal caries. *Dentomaxillofac Radiol* 2010; 39: 501-11.
15. Hintze H, Wenzel A, Frydenberg M. Accuracy of caries detection with four storage phosphor systems and E-speed radiographs. *Dentomaxillofac Radiol* 2002; 31: 170-5.
16. Peker I, Alkurt MT, Bala O, Altunkaynak B. The Efficiency of operating microscope compared with unaided visual examination, conventional and digital intraoral radiography for proximal caries detection. *Int J Dent* 2009; 29: 1-6.
17. White Sc, Pharoah MJ. *Oral radiology: principle and interpretation*. 6th ed. Mosby Elsevier; 2009. pp. 80.