

Cemento-Ossifying Fibroma

A Radiographic Diagnostic Dilemma

Case Report

Zahra Dalili¹, Somayeh Nemati², Fatemeh Shahsavari³

¹ Associate Professor, Department of Maxillofacial Radiology, Guilan University of Medical Sciences Dental School, Rasht, Iran

² Assistant Professor, Department of Maxillofacial Radiology, Guilan University of Medical Sciences Dental School, Rasht, Iran

³ Assistant Professor, Department of Oral & Maxillofacial Pathology, Dental Branch, Islamic Azad University, Tehran, Iran

Received: Jan 8, 2012
Accepted: Apr 18, 2012

Corresponding Author:
Somayeh Nemati, DDS

Address: Department of Maxillofacial Radiology
Faculty of Dentistry
Guilan University of Medical Sciences, Dental School,
Imam Street, Opposite Pardis Hotel
Rasht, Iran.

Telephone: +98-131-3263622

Fax: +98-131-3263623

E-mail: nematis60@gmail.com

Abstract

Cemento-ossifying fibroma (COF) is a rare benign fibro-osseous tumor. The radiographic and clinical features of this lesion are unpredictable and variable. In this report, the patient was a 12-year old girl with a painless swelling which demonstrated an opaque lesion with radiolucent zone to involve left posterior portion of the mandible on panoramic radiography. The radiographic manifestation of this lesion was similar to complex odontoma, but histological findings were compatible with COF. Here under, Cone-beam computed tomography (CBCT) findings of this lesion and also its radiographic diagnostic dilemma are discussed.

Key words: •Cone-beam computed tomography •Fibroma, ossifying •Mandible •Radiography, dental

Case Report

A 12-year-old girl referred to us complaining of a painless swelling in the left side of the mandible.

In clinical examinations, there was no tenderness and also no tooth mobility of the left mandibular first molar. No significant abnormal findings in her medical and dental history were detected. According to her mother's presentation, patient's chief complaint was of one-year duration.

A panoramic radiography revealed a well circumscribed opacity with radiolucent zone and expansion of the mandibular inferior cortex. Impacted mandibular second molar was also seen adjacent to the lesion (Figure 1). CBCT scan was prescribed by a maxillofacial surgeon for better evaluation of the lesion and detecting mandibular canal position.

Thus, tomographic Scans were taken by CBCT machine Newtom VG equipment (QR SRL Company, Verona, Italy) in full zoom mode. The field of view (FOV) of the tomographic scan was 9 inch. After acquisition of the volumetric data, reconstructed coronal images with 2mm thickness and 2 mm interval between slices were provided by NNT software. Mandibular canal is colorized on reconstructed panoramic view (1mm thickness and interval) by "show mark" tool (Figure 2).

3D and MPR (Multi Planner Reformations) images in three planes were permitted to view different aspects of lesion (Figure 3 a, b, and c). On the CBCT scan, a large expansive mass in the left posterior portion of the mandible was detected. This pericoronal lesion associated with the left mandibular second molar was extended from left retro-molar area to upper portion of the ramus. The lesion had homogeneous opaque internal structure. The mandibular canal which was pushed to inferior border of mandible was properly visualized in coronal images. Root resorption of adjacent tooth, left mandibular first molar, and cortical perforation were not detected. Medial and inferior displacement of the unerupted third and second molars was seen, respectively.

The estimated size of lesion in CBCT was 25 mm × 22 mm. Antero-posterior dimension was 29mm, buccolingually was 22mm, and supero-inferiorly was 25mm. Radiographically, the lesion had many features of complex odontoma such as pericoronal position relative to the left mandibular second molar, corticated well defined boundary with very clear radiolucent zone inner to the corticated margin, the internal radiopaque structure and prevention of tooth eruption. The age of the patient was another positive point for the diagnosis of odontoma. Biopsy was performed, and despite the fact that there were many similarities of the lesion to the complex odontoma based on radiography, histopathology didn't confirm odontogenic odontoma and the lesion was diagnosed as COF.

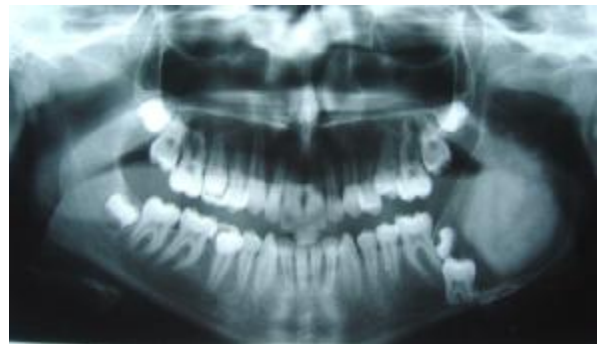

Figure 1. Panoramic view reveals pericoronal homogeneous opacity with radiolucent zone in Lt mandibular ramus

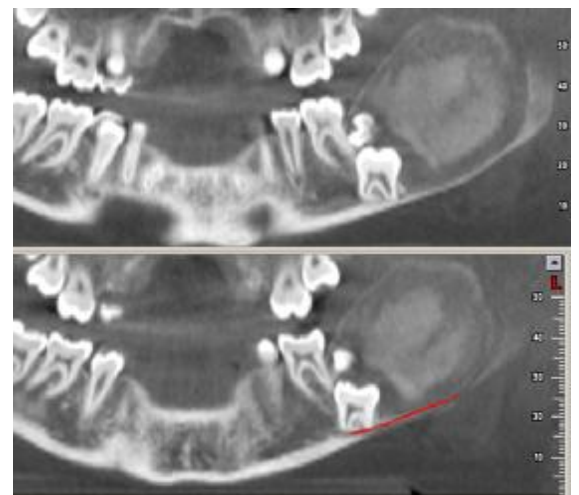
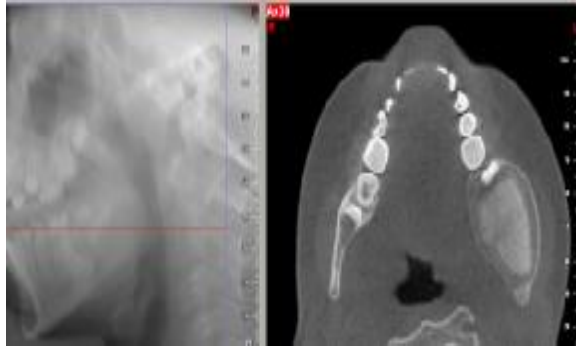
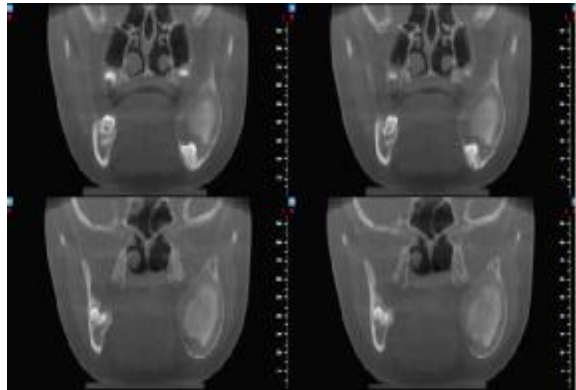


Figure 2. Reconstructed panoramic views and colorization of the mandibular canal

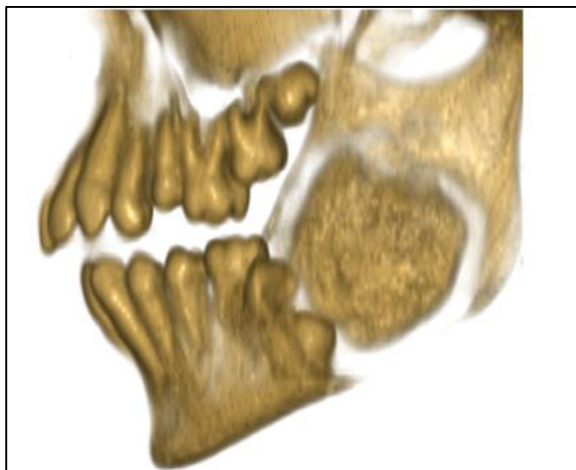
In histopathology, the tumor consists of fibrocellular tissue along with numerous foci of mineralized material which was composed of admixture of predominantly basophilic spherules of cementum and trabeculae of osteoid and bone (Figure 4).



(a)



(b)



(c)

Figure 3. Axial (a), coronal (b) and 3D (c) views present expansive mass with internal opacity and radiolucent zone. Mandibular canal is displaced toward inferior border of mandible.

Microscopically this tumor was reported as benign fibro-osseous proliferation. Since the tumor was well-demarcated grossly and was separated surgically easily from the surrounding bone, and the microscopic feature of the tumor showed admixture of bony trabeculae and cementum, the tumor is called as cemento-ossifying fibroma. Conflicting findings were challenging and very interesting. The lesion underwent surgical removal and about 6 and 12 months later, we followed up the patient on panoramic radiography and the healing process was successful (Figure 5).

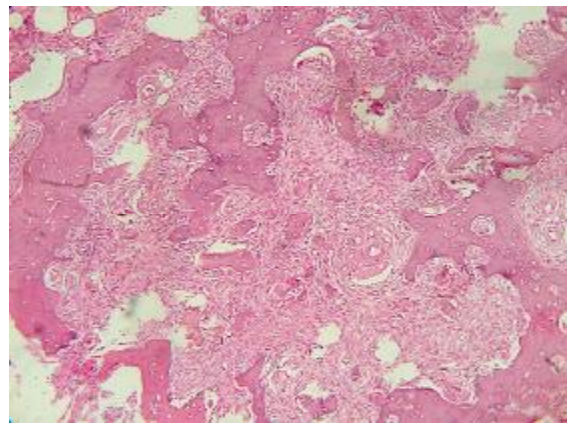


Figure 4. The microscopic feature of the tumor shows admixture of bony trabeculae and cementum.

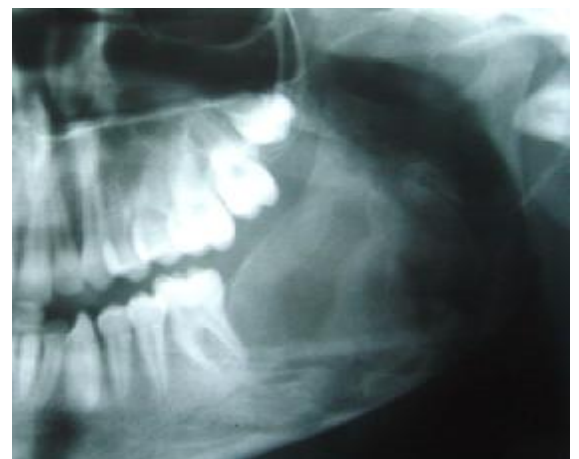

Figure 5. The follow-up panoramic view of the patient, six months after surgery

Discussion

Cemento-ossifying fibroma is a rare neoplasm which is the part of fibro-osseous lesions of the jaws.⁽¹⁻³⁾ It is generally accepted to be a demarcated, occasionally encapsulated lesion of the fibrous tissue which contains variable amounts of mineralized material, resembling abnormal bone or cementum.^(2, 4)

It seems that the cemento-ossifying fibroma occurred most often in the third and fourth decades, with women more often affected than men.^(1, 2, 5-9) The vast majority of lesions are found in posterior region of the mandible and usually located in the roots of the teeth or in the periapical region.^(1, 10) Most of them are solitary and rarely occur in a multiple form.⁽¹¹⁾

Although COF has mainly been found in the jaws, it has also been reported in the frontal, ethmoid, sphenoid, temporal bones, in the orbit and the anterior cranial fossa.^(2, 12)

The COF affecting the jaws exhibits a variable behavior ranging from slow growth to occasionally aggressive local destruction and some cases recur after surgery.^(5-7, 12)

The clinical features of COF can vary from indolent to aggressive behavior. The disease is usually asymptomatic at the time of discovery. On occasion, facial deformity develops.⁽¹³⁾

The internal structure of a COF lesion is a mixed radiolucent-radiopaque density with a pattern that depends on the amount and form of the internal calcified material. In some instances the internal structure may appear almost totally radiolucent with just a hint of calcified material.⁽¹³⁾ The pericoronal and opaque variety of this lesion is rare.^(13, 14) Of all odontogenic tumors in the jaws, COF has the most variation in pattern.^(2, 15, 16)

The growth of the lesion may result in displacement of teeth or inferior alveolar canal. A significant point is that the outer cortical plate, although displaced and thinned, remains intact. The lamina dura of the involved teeth is usually missing, and the resorption of teeth may occur.^(13, 17) Root resorption and tooth displacement are common findings in these lesions.⁽¹⁾

In the presented case, a radiopaque, well-defined pericoronal type of COF with radi-

olucent zone associated with left mandibular second molar was seen on panoramic and CBCT. The position of this lesion in the posterior portion of mandible and occurrence in a female patient were compatible to many other studies.^(1, 10, 13) A radiographic criterion such as the pericoronal position and the internal structure of this lesion was well-matched to complex odontoma. Concomitant occurrence of complex odontoma with calcifying odontogenic cyst was reported previously.⁽¹⁸⁾ Im-animoghaddam et al reported 6 cases of COF with different clinical and radiographic features.⁽¹⁾ In their report, only one case had dense radiopaque manifestation that occurred in a 54 years old woman in extraction site of maxillary left first molar. Liu et al reported 20 cases of COF with variable features. Only in one case, early diagnosis was complex odontoma.⁽¹⁶⁾

In our case, the lesion was clinically asymptomatic, in other words, this finding was in agreement with oral radiology reference text.⁽¹³⁾ Root resorption in this lesion is common,⁽¹³⁾ but in our case was not found. Expansion of buccolingual cortex with thinning of intact cortex and no perforation of the cortex in this case report is similar to the other studies.^(13, 16) Most COFs grow slowly, and once completely excised; don't recur. At the other hand, a minority, particularly in children, exhibit rapid growth and a tendency to recur.⁽¹²⁾ The recurrence rate of COF after curettage was found to be 28%.^(15, 19) Thus, a close follow up of this patient is necessary. In our case, the lesion was detected in a 12 year old girl. This age for COF is lower than the reported age ranges that are usually vulnerable in the third and fourth decades.^(1, 2, 5-9) The mean reported age in Liu et al study⁽¹⁶⁾ was 27.8 year. In our case, the lesion occurred in lower age. Consequently, we followed up the lesion due to the possibility of recurrence. There was no evidence of recurrence during 12 months after surgical excision.

CBCT has been used extensively to evaluate the interior of bone tumors and other lesions.⁽¹⁵⁾ Thanks to many advantages of this new modality, we used this technique for better evaluation of the internal structure, extension and expansion of lesion, relation to

the mandibular canal, and the boundary of lesion. This technique helped the surgeon for better surgical procedure.

Conclusion

COF has variable radiographic findings thus it can be considered in differential diag-

nosis of wide spectrum of central bone lesions.

Acknowledgement

We are grateful to Dr Gholam Hossein Adham for his help in report of surgical findings and follow up the patient.

References

1. Imanimoghaddam M, Hosseini Zarch SH, Nemati S, Javadian Langaroody A. Cemento-ossifying fibroma: study of radiographic features of six cases. *Iran J Radiol* 2009; 6: 215-20.
2. Hwang E-H, Kim H-W, Kim K-D, Lee S-R. Multiple cement-ossifying fibroma: report of an 18 – year follow-up. *Dentomaxillofac Radiol* 2001; 30: 230-4.
3. Yih WY, Pederso GT, Bartely MH. Multiple familial ossifying fibromas: relationship to other osseous lesions of the jaws. *Oral Surg Oral Med Oral Pathol* 1989; 68: 754-8.
4. Krammer IRH, Pindborg JJ, Shear M. The WHO histological typing of odontogenic tumors. *Cancer* 1992; 70: 2944-88.
5. EI Mofty SK. Cemento-ossifying fibroma and benign cementoblastoma. *Semin Diagn Pathol* 1999; 16: 302-7.
6. MacDonald-Jankowski DS. Cemento-ossifying fibroma in the jaws of Hong-Kong Chinese. *Dentomaxillofac Radiol* 1998; 27: 298-304.
7. Sanchis JM, Penarrocha M, Balaguer JM, Camacho F. Cemento-ossifying mandibular fibroma: a presentation of two cases and review of the literature. *Med Oral* 2004; 9: 69-73.
8. Meenakshi R, Jayachanran S. Cemento-ossifying fibroma. *Indian J Dent Res* 2004; 15: 35-9.
9. Hombal AG, Hegde KK, Narvekar VN. Cemento-ossifying fibroma of mandible. *Australas Radiol* 2007; 51: 176-9.
10. Som PM, Curtin HD. *Head and neck imaging*. 4th ed. USA: Mosby; 2003. pp. 968.
11. Cavalcanti MGP, Ruprecht A, Vannier MW. Evaluation of an ossifying fibroma using three-dimensional computed tomography. *Dentomaxillofac Radiol* 2001; 30: 342-345.
12. MacDonald-Jankowski DS. Ossifying fibroma: a systematic review. *Dentomaxillofac Radiol* 2009; 38:495-513.
13. White SC, Pharoah Mj. *Oral Radiology* .6th ed. china: Mosby; 2009.pp. 440-1.
14. Wood NK, Goaz PW. *Differential diagnosis of oral and maxillofacial lesions*. 5th ed. USA: Mosby; 1997. pp. 279.
15. Araki M, Matsumoto K, Matsumoto N, et al. Unusual radiographic appearance of ossifying fibroma in the left mandibular angle. *Dentomaxillofac Radiol* 2010; 39: 314-19.
16. Liu Y, You M, Wang H, et al. Ossifying fibromas of the jaw bone: 20 cases. *Dentomaxillofac Radiol* 2010; 39:57-63.
17. Takeda Y, Fukioka Y. Multiple cement-ossifying fibroma. *Int J Oral Maxillofac Surg* 1987; 16: 368-71.
18. Nagao T, Nakajima T, Fukushima M, Ishiki T. Calcifying odontogenic cyst with complex odontoma. *Journal of Oral and Maxillofac Surg* 1982; 40: 810-813.
19. Eversl LR, Merrell PW, Strub MA. Radiographic characteristics of central ossifying fibroma. *Oral Surg Oral Med Oral Pathol* 1985; 59: 522-527.