

# The Evaluation of Diagnostic Values of Related Markers in Keratocystic Odontogenic Tumor's Angiogenesis

Shirin Modabbernia<sup>1</sup>, Seyedeh Sara Bagheri<sup>1</sup>, Nazanin Bashardoust<sup>1</sup>

## ARTICLE INFO

**Article type:**  
Original Article

**Article history:**  
Received: Jan 1, 2017  
Accepted: Mar 3, 2017  
Available online:

<sup>1</sup>Assistant Professor, Department of Oral and Maxillofacial Pathology, School of Dentistry, Guilan University of Medical Sciences, Rasht, Iran.

**Corresponding Author:**  
Shirin Modabbernia  
**Address:**  
Department of Oral and Maxillofacial Pathology, School of Dentistry, Guilan University of Medical Sciences, Rasht, Iran.  
**E-mail:** shirinmodabbernia@yahoo.com  
**Telephone:** +98 1333363622  
**Fax:** +98 13 3336 3621

## Abstract

### Introduction:

Odontogenic tumors include a variety of lesions that are classified from hamartomas to benign and malignant neoplasms. Angiogenesis process helps neoplastic tissue to gain an adequate supply of oxygen and also to remove the waste products. Mean Vessel Density (MVD) evaluation is a common method for assessing angiogenesis by using different markers. To the best of our knowledge, there is no specific marker for angiogenesis evaluation, so the aim of this study is to determine the proper angiogenic marker.

### Materials and methods:

In this cross sectional study, the MVD was assessed 45 cases totally; 15 cases in each group. Data were analyzed by using independent t-test and one-way ANOVA ( $P < 0.05$ ).

### Results:

There are statistically significant differences between CD34 and CD105 ( $P = 0.028$ ), CD34 and VEGF ( $P = 0.001$ ) and, CD105 and VEGF ( $P = 0.001$ ). CD34 has the lowest sensitivity, and VEGF has the highest sensitivity among others.

### Conclusion:

The results suggest that VEGF could be a better marker for assessing angiogenic tissue.

### Key words:

•Angiogenic Proteins •Immunohistochemistry •Odontogenic Tumors

### Copyright:

Modabbernia Sh, Bagheri S.s., Bashardoust N. The Evaluation of Diagnostic Values of Related Markers in Keratocystic Odontogenic Tumor's Angiogenesis, 3DJ 2017;6(1):31-35

## Introduction

Odontogenic cysts are the most common destructive oral and maxillofacial lesions in the head and neck region.<sup>(1)</sup> Among these lesions, odontogenic keratocyst (OKC) has a unique

histopathological features, high recurrence rate and aggressive biological behavior and because of this, it has been of great interest. In addition to a specific biological behavior,

the various proliferation markers expression in the cyst wall and mutation in p53 and PTCH gene, several studies have reported that KCOT behavior is more like that of a benign neoplasm than a cyst.<sup>(2-4)</sup>

The connective tissue stroma has a critical role in protection of epithelial tissue and minor changes in the epithelium, which are followed by corresponding alterations in the stroma such as angiogenesis.<sup>(5-6)</sup> Because of no blood supply in the epithelium, angiogenesis is a critical process to avoid epithelial cell apoptosis.<sup>(7)</sup>

Angiogenesis is a multi-stage process in which new blood vessels are formed from pre-existing vessels.<sup>(7-8)</sup> There is a large spectrum of physiological and pathological processes in which angiogenesis intervenes, including tissue hypertrophy, wound healing, inflammation and neoplasms.<sup>(7,9)</sup>

An arbitrary marker for angiogenesis should detect the new vessels for the quality as well as the quantity. Tumor angiogenesis is regulated by several molecules such as vascular endothelial growth factor (VEGF), CD31, CD34, Von Willebrand factor, and CD105, also called as endoglin. Legan stated that pan-endothelial markers (CD31, CD34, Factor VIII) and CD105 are differentially expressed in angiogenic and normal vessel endothelial cells.

Angiogenesis is proposed as one of the most important mechanisms which could induce the tumor aggressiveness.<sup>(9-10)</sup>

There is not enough data to prove the effect of angiogenesis on odontogenic ketaocyst's aggressive behavior so the aim of this study was to assess the angiogenesis by different markers in odontogenic keratocyst.

## Materials and Methods

Forty five tissue sections from paraffin block samples selected from OKC lesions underwent immunohistochemical assessment using VEGF antibody, CD34 antibody and CD105 antibody manufactured by Dako Company (Denmark), using streptavidin-biotin-peroxidase technique.<sup>(11)</sup> Each group containing 15 cases of OKC. During the staining procedure, adenoid tissue was used as positive controls for VEGF, CD34 and CD105. The stained slides were appraised

under a light microscope (Olympus BX41, Japan) by two oral pathologists at 100×400 magnification. In order to define the sensitivity and specificity of these three markers MVD, the expression of these three antibody was assessed by counting even the number of individual stained cells, including epithelial cells, fibroblasts and endothelial cells or the in aggregation, in three microscopic fields with the highest amount of vascularization known as hot spot.

Positive staining for VEGF, CD105 and CD34 was determined as brown-colored cells which were definitely separated from the adjacent micro-vessels.<sup>(12)</sup> Blood vessels with muscular walls were excluded and the mean number of blood vessels in the three selected was considered as mean vascular density (MVD). Because of the power of each of the named markers in detecting only endothelial cells, the less the stained cells are, the most sensitive and specific markers we have. Independent samples t-test, Fischer exact test and one-way ANOVA were used to compare the sensitivity and specificity between the markers. The data were analyzed by SPSS version 21, with setting p value at 0.05.

## Results

After the statistical analysis, the normality of data was proved according to Shapiro-Wilk test. (Table 1)

Table 1. Shapiro wilk test

Group	Z	d	P value
CD34	0.544	15	0.918
CD105	0.469	15	0.980
VEGF	0.530	15	0.941

The table below, assessed by ANOVA test, shows that the most sensitive and specific marker among these three markers, for angiogenic evaluation is VEGF with the minimum score of MVD and the least one is CD34 with the maximum score.(Table 2)

Sensitivity and specificity between VEGF, CD34 and CD105 were evaluated in a binary fashion with the use of Post hoc test. (Table 3). The statistically significant difference is obvious.

Figure 1 shows the immunohistochemical staining in three groups in which the positive staining is clear.

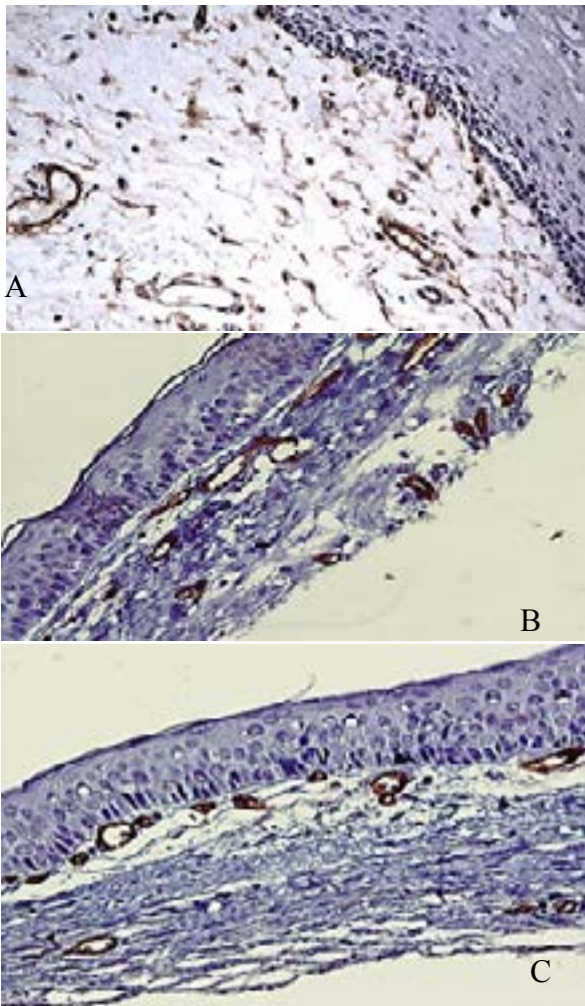
**Table 2.** Determining the most sensitive and specific marker by ANOVA test

Group	N	Mean	S.d	Confidence Interval 95%		F	P-value
				lower Bound	Upper Bound		
CD34	15	17.31	16.6	12.17	29.10	12.729	0.0001
CD105	15	96.9	64.2	15.11	22.8		
VEGF	15	29.5	94.2	29.4	55.7		

S.d: Standard deviation

**Table 3.** Evaluation of sensitivity and specificity of angiogenic markers by Post hoc

Group	J group	Mean Difference	Std.Error	Confidence Interval 95%		P-value
				lower Bound	Upper Bound	
CD34	CD105	4.02	1.54	0.269	7.77	0.033
CD34	VEGF	7.97	1.54	4.04	11.54	0.0001
CD105	VEGF	3.77	1.54	0.016	7.52	0.049

**Figure 1.** Immunohistochemical staining by A. VEGF, B. CD34, C. CD105

## Discussion

Very limited studies have been performed to evaluate the sensitivity and specificity of the three most-used angiogenic markers. The results

of this study showed a significant difference between those three, with significantly lower VEGF expression and so higher sensitivity and specificity. Inconsistent with the result of the present study, Nonaka et al.,<sup>(10)</sup> showed a significant relationship between the expression of VEGF, vascular density, and angiogenesis, concluding that higher expression of VEGF was correlated with greater vascular density and higher inflammatory infiltration. Expression of VEGF has also been assessed in pathologic lesions, which is related to the poor prognosis in breast cancers. Moreover, an increase in the expression of VEGF might be contemplated as the first step in metastasis, which resulted changes in the angiogenesis process.<sup>(10)</sup> However VEGF is associated with lower survival rate, its exact mechanism in the tumor advancement is not clear.<sup>(13)</sup> Furthermore, it has been indicated that whenever VEGF is released, it might activate some responses, which result in cell survival, mobilization, or differentiation.

In the present study, MVD based on CD105 marker were significantly less than those with CD34. In agreement with the result of this study, Jamshidi et al.,<sup>(14)</sup> Miyata et al.,<sup>(15)</sup> Kumagai et al.,<sup>(16)</sup> and Czekierdowski<sup>(17)</sup> which contrasted the expression of CD105 and CD34 antibodies in different lesions, have also demonstrated a lower MVD based on CD105 marker. The expression of CD105 is an outstanding specification of recently made vessels; in addition, there is no expression of CD105 in the endothelium of the normal tissue vessels and also in the previously formed vessels<sup>(14, 18)</sup>, hence, based on the results of these studies, the sensitivity and

specificity of CD105 marker are higher than CD34 which is in consistent with the result of our study. In comparison to CD105, CD34 stains the vascular endothelial cells of normal and neoplastic tissues and cannot identify the newly formed blood vessels from the old one.<sup>(8-9,19-20)</sup>

Based on our knowledge, there is no study with the discussion about these three named angiogenic markers, but, something clear is that angiogenesis and its related factors are necessary for pathologic lesions development, so the knowledge of which marker can work better, would greatly help the researchers in the field of angiogenesis.<sup>(21)</sup> The results of the previous researches have shown that when VEGF signals are constrained, angiogenesis and the tumor progression come to an end subsequently. Moreover, tumor extravasation is simplified by VEGF expression as a result of persuading permeability of blood vessels.<sup>(22-25)</sup>

It seems that VEGF has a progenitor trait in comparison with other vascular markers, therefore, due to the mentioned mechanism of VEGF, and with regard to the present results and also in view of strong correlation between these three angiogenic markers, it seems that besides the important role of angiogenesis in the tumor development, it can be considered as induce an increase in vascular density, playing a role in the more aggressive behavior of OKC. Therefore, angiogenesis and evaluation of vascular density might be an important aim for developing treatment modalities based on decreasing vascular density, especially during recurrence of odontogenic tumors.<sup>(11)</sup>

## Conclusion

Although all the three markers have been stained, Something that can be declared, based on the results of the present study, is that VEGF is a more specific and sensitive marker for angiogenic evaluation; hence, it would be much better to use this for further studies.

## Conflict of Interest

The authors declare that they have no conflict of interest.

## Acknowledgments

We would like to thank Zahra Pourhabibi for statistical consultaion.

## References

1. Patidar KA, Parwani RN, Wanjari SP, Patidar AP. Mast cells in human odontogenic cysts. *Biotech Histochem.* 2012; 87(6):397-402.
2. Tsuneki M, Cheng J, Maruyama S, Ida-Yonemochi H, Nakajima M, Saku T. Perlecan-rich epithelial linings as a background of proliferative potentials of keratocystic odontogenic tumor. *J Oral Pathol Med.* 2008; 37(5):287-93.
3. Taghavi N, Modabbernia S, Akbarzadeh A, Sajjadi S. Cyclin d1 expression in odontogenic cysts. *Turk Patoloji Derg.* 2013;29(2):101-7.
4. Mateus GC, Lanza GH, de Moura PH, Marigo Hde A, Horta MC. Cell proliferation and apoptosis in keratocystic odontogenic tumors. *Med Oral Patol Oral Cir Bucal.* 2008;13:E697-702.
5. Chandrangu S, Sappayatosok K. p53, p63 and p73 expression and angiogenesis in keratocystic odontogenic tumors. *J Clin Exp Dent.* 2016; doi:10.4317/jced.52843
6. Puthiyaveetil JS, Kota K, Chakkarayan R, Chakkarayan J, Thodiyil AK. Epithelial - Mesenchymal Interactions in Tooth Development and the Significant Role of Growth Factors and Genes with Emphasis on Mesenchyme - A Review. *J Clin Diagn Res.* 2016; 10(9):ZE05-ZE09.
7. Vinay Kumar D, Hemavathy S, Kulkarni D, Mattighatta Rudraiah P, Sidramayya Mathpati SM, et al. Expression of CD105 in tumor angiogenesis a comparative study (ameloblastoma, keratocystic odontogenic tumor and dentigerous cyst). *J Int Oral Health.* 2015; 7(6): 23–27.
8. Hande AH, Gadbail AR, Sonone AM, Chaudhary MS, Wadhwan V, Nikam A. Comparative analysis of tumour angiogenesis in solid multicystic and unicystic ameloblastoma by using CD 105 (endoglin) *Arch Oral Biol.* 2011;56(12):1635–40.
9. Seifi S, Shafaie S, Ghadiri S. Microvessel density in follicular cysts, keratocystic odontogenic tumours and ameloblastomas. *Asian Pac J Cancer Prev.* 2011;12(2):351–6.
10. Nonaka CF, Maia AP, Nascimento GJ, de Almeida Freitas R, Batista de Souza L, Galvão HC. Immunoeexpression of vascular endothelial growth factor in periapical granulomas, radicular cysts, and residual radicular cysts. *Oral Surg Oral Med Oral Pathol Oral Radiol Endod* 2008;106:896-902.
11. Sadri D, Shahsavari F, Farhadi S, Shahabi Z, Mehran Z. Angiogenesis concept in odontogenic keratocyst: A comparative study. *Indian J of Dent Res.* 2017;28(3):275-280.
12. Fox SB, Harris AL. Histological quantitation of tumour angiogenesis. *APMIS.* 2004;112: 413–430.

13. Amo Y, Masuzawa M, Hamada Y, Katsuoka K. Serum concentrations of vascular endothelial growth factor-D in angiosarcoma patients. *Br J Dermatol* 2004;150:160-1.
14. Jamshidi S, Zargarani M, Baghaei F, Shojaei S, Zare Mahmoodabadi R, Dehghan A, et al. An Immunohistochemical Survey to Evaluate the Expression of CD105 and CD34 in Ameloblastoma and Odontogenic Keratocyst. *J Dent (Shiraz)* 2014;15: 192–198.
15. Miyata Y, Mitsunari K, Asai A, Takehara K, Mochizuki Y, Sakai H. Pathological significance and prognostic role of microvessel density, evaluated using CD31, CD34, and CD105 in prostate cancer patients after radical prostatectomy with neoadjuvant therapy. *Prostate*. 2015;75: 84–91.
16. Kumagai Y, Sobajima J, Higashi M, Ishiguro T, Fukuchi M, Ishibashi K, et al. Angiogenesis in superficial esophageal squamous cell carcinoma: assessment of microvessel density based on immunostaining for CD34 and CD105. *Jpn J Clin Oncol*. 2014;44: 526–533.
17. Czekierdowski A, Czekierdowska S, Czuba B, Cnota W, Sadowski K, Kotarski J, et al. Microvessel density assessment in benign and malignant endometrial changes. *J Physiol Pharmacol*. 2008;59: 45–51.
18. Afshar Moghaddam N, Mahsuni P, Taheri D. Evaluation of Endoglin as an Angiogenesis Marker in Glioblastoma. *Iran J Pathol*. 2015;10:89–96.
19. Nielsen JS, McNagny KM. Novel functions of the CD34 family. *J Cell Sci*. 2008;121(Pt 22): 3683–3692.
20. Goldiș DS, Sferdian MF, Tarță C, Fulger LO, Totolici BD, Neamțu C. Comparative analysis of microvessel density quantified through the immunohistochemistry expression of CD34 and CD105 in rectal cancer. *Rom J Morphol Embryol*. 2015;56:419–424.
21. De Moraes M, de Matos FR, de Souza LB, de Almeida Freitas R, de Lisboa Lopes Costa A. Immunoeexpression of RANK, RANKL, OPG, VEGF, and vWF in radicular and dentigerous cysts. *J Oral Pathol Med* 2013;42:468-73.
22. Liu X, Dreffs A, Díaz-Coránguez M, Runkle EA, Gardner TW, Chiodo VA, et al. Occludin S490 phosphorylation regulates vascular endothelial growth factor-induced retinal neovascularization. *Am J Pathol* 2016;186:2486-99.
23. Liu F, Wang Y, Wang X, Zheng Y, Jin Z, Zhi J. Role of agonistic autoantibodies against type-I angiotensin II receptor in the pathogenesis of retinopathy in preeclampsia. *Sci Rep* 2016;6:29036.
24. Kouchaki E, Otroushi Shahreza B, Faraji S, Nikoueinjad H, Sehat M. The association between vascular endothelial growth factor-related factors with severity of multiple sclerosis. *Iran J Allergy Asthma Immunol* 2016;15:204-11.
25. Sadri D, Farhadi D, Shahabi Z, Sarshar S. Expression of vascular endothelial growth factor in odontogenic cysts: Is there any impression on clinical outcome? *Open Dent J* 2016;10:752-9.