

Craniofacial Fibrous Dysplasia: New Image Findings

Case Report

Ava Nikbin¹, Seiedeh Tahereh Mohtavipour², Alieh Sadat Javadzadeh Haghghat², Saeed Dhjashtyari³, Mohammad Talebzadeh⁴

¹Postgraduated Student, Department of Oral and Maxillofacial Radiology, Faculty of Dentistry, Guilan University of Medical Sciences, Rasht, Iran.

²Assistant Professor, Oro-Maxillofacial Developmental Diseases Research Center, Department of Maxillofacial Radiology, Faculty of Dentistry, Guilan University of Medical Sciences, Rasht, Iran.

³Assistant Professor, Department of Maxillofacial Surgery, Faculty of Dentistry, Guilan University of Medical Sciences, Rasht, Iran.

⁴Postgraduated Student, Department of Maxillofacial Surgery, Faculty of Dentistry, Guilan University of Medical Sciences, Rasht, Iran.

Received: Jan 20, 2017
Accepted: Mar 17, 2017

Corresponding Author:

Ava Nikbin

Address:

Department of Oral and Maxillofacial Radiology, Faculty of dentistry, Guilan University of Medical Sciences, Rasht, Iran.

Telephone: +981333486407

Email: E-mail: nikbinava@yahoo.com

Fax: +981333486423

Abstract

Introduction:

Fibrous dysplasia is a benign fibro-osseous lesion that affects craniofacial bones including the maxilla and mandible. In the most cases of fibrous dysplasia of facial bones, radiographic findings represent lucent or mixed radiolucent-radiopaque lesion with ill-defined borders and gradual blending of its border with adjacent bone. In this presentation, a patient suffering from Polyostotic Fibrous Dysplasia with different radiographic findings has been reported.

Key words:

•Fibrous dysplasia •Polyostotic •Cone-beam computed tomography

Case Report

A 10-year-old girl was referred to the oral and maxillofacial surgery department of Poursina hospital complaining of progressive asymmetric painless swelling of the left side of the maxilla. Extraoral examinations revealed expansile non-tender and bony hard lesion in palpation. This lesion was not painful. Intraoral examination showed expansile alveolar ridge in the left side of the maxilla which was covered with normal mucosa. Laboratory tests were ordered. Panoramic view and cone-beam computed tomography (CBCT), were also requested.

Hematological and biochemistry tests were also ordered in this case. Results of these tests were in the normal range. Panoramic radiography showed opacification of canine fossa and premolar region in the left side of the maxilla. There were two unerupted teeth (canine and second premolar) in this region. Tooth displacement was not evident (Figure 1). CBCT was recommended for better evaluation and localization of the lesion. According to the CBCT (in cross-sectional,

coronal and axial view), a well-defined expansile mixed radiolucent-radiopaque lesion in the left side of the maxilla was obvious, also sphenoid bone and pterygoid plate in the left side were opacified. (Figure 2 and 3) Additionally, there is no evidence of tooth resorption or tooth displacement. On the basis of these radiographic findings fibro-osseous lesions such as fibrous dysplasia and central ossifying fibroma were considered as differential diagnosis. Therefore, the patient was referred to the surgical department.

Treatment was pursued by excisional biopsy, reshape of the bony lesion, and follow-up process. Unfortunately, swelling in the left side of maxilla was seen after one year follow-up.

Microscopic view determined irregular shaped woven bone without osteoblastic rim in a cellular fibrous stroma. Artifactual cleft around the bony trabeculae was present and there is no evident of necrosis, hemorrhage, atypia, mitotic figure or malignancy. Histopathologic findings revealed fibro-osseous lesion, compatible with clinical and radiographic findings of fibrous dysplasia.

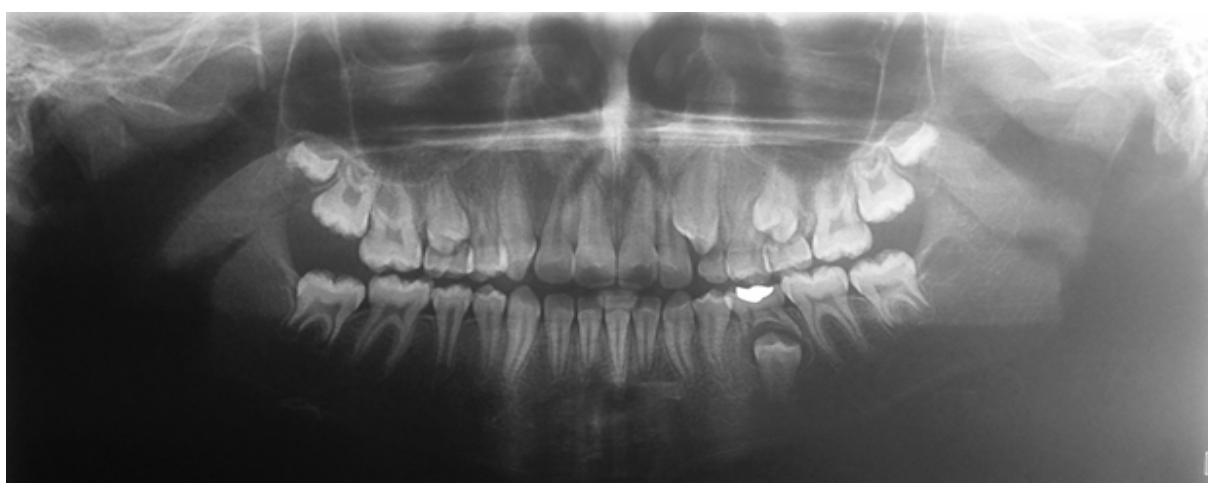

Figure 1. Panoramic view reveals opacification of canine fossa and premolar region in the left side of maxilla.

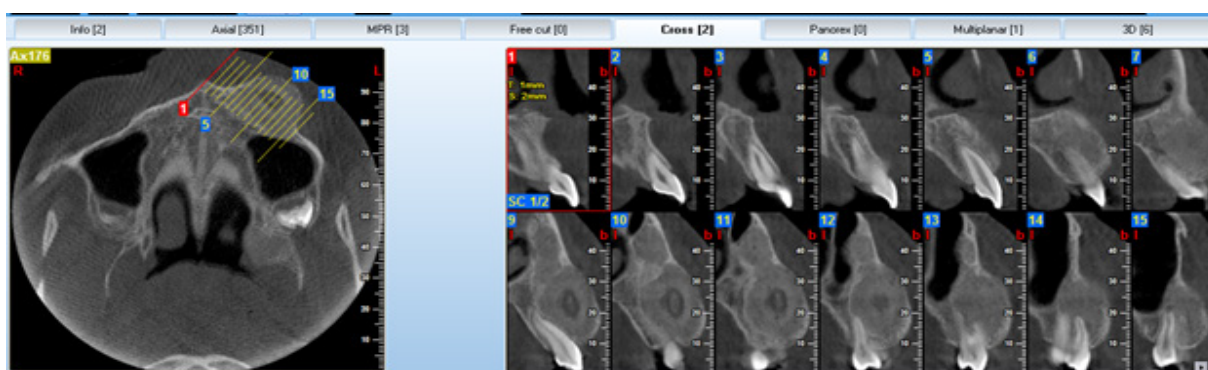


Figure 2. Cross-sectional view reveals well-defined mixed radiolucent radiopaque lesion in the left side of maxilla, which expanded buccal cortex in canine-premolar region.

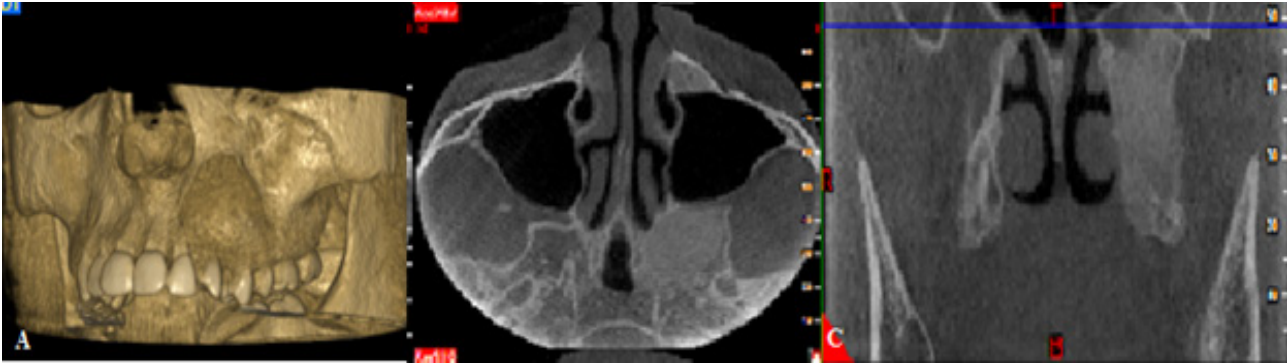


Figure 3. 3D (A), axial (B), and coronal view (C) reveal well-defined expansile radiopaque lesion in the left side of maxilla, sphenoid bone (A, B) and pterygoid plate (C).

Discussion

Fibrous dysplasia (FD) is a developmental disorder of growing bones with unknown etiology. It occurs in two distinct forms: polyostotic and monostotic. Polyostotic form involves several bones and accounts for 30% of the cases. Monostotic form is found predominantly in children and young adult before the age of 30 years, involves a single bone and constitutes 70% of cases but Polyostotic form is commonly seen in children younger than 10 years old.^(1,2) FD could also be classified as solitary or multiple (Jaffe type). Multiple type includes MacCune-Albright Syndrome with specific signs including café au lait spots and hypo-function of one or several endocrine glands.⁽³⁾

Fibrous dysplasia is equally distributed in both genders, except in those patients suffering from MacCune-Albright Syndrome, which affects females almost exclusively.⁽⁴⁾ As discussed before, the case study of this research was a teenage female. With regard to the normality of laboratory tests and pathologic investigations, Jaffe-Lichtenstein was diagnosed. This disease may result in hearing disturbance, visual complications, tooth displacement, and facial asymmetry.⁽⁴⁾ However, in this case, hearing disturbance and visual complications were not evident. Fibrous dysplasia involves the maxilla twice as often as the mandible.^(5,6) It occurs more often in the posterior region. Lesions are commonly unilateral excluding the very rare extensive lesions of the maxillofacial region, which are bilateral.

Fibrous dysplasia is said to occur more readily in membranous bones and involvement of ethmoid and sphenoid is uncommon as they are cartilaginous.⁽⁵⁾ Although sphenoid bone and ptery-

goid plate are uncommon sites for involvement, which was seen in this case study.

The main radiographic feature was a fine ground-glass opacification that results from superimposition of a myriad of poorly-calcified bone trabeculae arranged in a disorganized pattern.⁽⁶⁾ The radiographic features of the lesion are highly dependent on bony components and fibrous tissue in the affected site. These specifications are divided into three different subtypes; pagetoid (56%), sclerotic (23%), and radiolucent (21%).⁽⁷⁾ Sclerotic subtype, which is highly engaged in the facial region, was seen in this patient. Radiolucent and pagetoid subtypes are generally seen in Calvarium bones, which is compatible with our findings. Most commonly, in radiographic view, the periphery of FD lesions is ill-defined, with gradual blending of normal trabecular pattern into abnormal trabecular pattern. Possibly, the boundary between normal pattern and the lesion appears sharp and even corticated especially in young lesions. Plain radiograph shows that the lesion is not well circumscribed. Although the major cases of fibrous dysplasia radiographic findings represent lesions with ill-defined borders and gradual blending⁽²⁾, 3D assessment of the case study of the involved regions with CBCT displays well-defined corticated lesions with sharp border. Radiographic findings are important in diagnosis of fibrous dysplasia due to the similarity of the histopathologic pattern of fibro-osseous lesions. This well-defined radiographic pattern can be the result of accurate assessment of the involve bone with CBCT versus plain radiographic view. In addition, sphenoid bone and pterygoid plate involvement is well specified, but plain radiographic view wasn't useful for detection of all involved site. Although

CBCT alone is insufficient in the diagnosis of fibrous dysplasia, it is the imaging method of the choice because of its most accurate evaluation of the bony details. CBCT and MRI is useful for assessment of the conservative effects of craniofacial fibrous dysplasia on and the neural and vascular canals and paranasal sinuses.⁽⁸⁻¹⁰⁾ In this case study, neural and vascular foramen involvement were not evident. Lesions including traumatic bone cyst, central giant cell granuloma and aneurismal bone cyst can be occur in mature lesion of fibrous dysplasia.⁽³⁾ Therefore, diagnosis and follow-up are important with regard to the probable issues. In addition to the surgical procedure, bisphosphonate-based treatment to control the osteoblastic and osteoclastic activities of bone is another approach to cure fibrous dysplasia.⁽¹¹⁻¹²⁾ In this patient, follow-up process revealed recurrence of the lesion. Reshape and follow-up the case reveals recurrency of the lesion so, prescription of these medicines can be used in next steps of treatment. Currently, having known the genetic base of this disease⁽¹²⁾, there is hope for its final treatment.

References

1. Abdelkarim A, Green R, Starzell J, Preece J. Craniofacial polyostotic fibrous dysplasia: a case report and review of the literature. *Oral Surg Oral Med Oral Pathol Oral Radiol Endod.*2008; 106(1): e49-55.
2. White SC, Pharoah MJ. *Oral radiology.* 7th ed. Canada: Elsevier; 2014:402-8.
3. Araghi HM, Haery C. Fibro-osseous lesions of craniofacial bones. The role of imaging. *Radiol Clin North Am.* 1993; 31(1):121-34.
4. Malaviya P, Choundhary S, Shivhare P. Craniofacial polyostotic fibrous dysplasia with Shepherd's Crook deformity of the proximal part of the femur: A case report. *GJRA.*2016; 5(5):193-5.
5. Eversole R, Su L, ElMofty S. Benign fibro-osseous lesions of the craniofacial complex. A review. *Head Neck Pathol.* 2008;2(3):177-202.
6. Neville B, Damm D, Allen C, Bouquot J. *Oral and maxillofacial pathology.* 2nd ed. Philadelphia: Elsevier;2016:592-5.
7. Machida K, Makita K, Nishikawa J, Ohtake T, Olio M. Scintigraphic manifestation of fibrous dysplasia. *Clin Nucl Med.* 1986;11(6):426-9.
8. Ogbale GI, Akinmoladun VI. Computed tomography evaluation of craniofacial fibrous dysplasia in an African population. *Oral Surgery.*2012;5(3):109-13.
9. Unal Erzurumlu Z, Celenk P, Bulut E, Baris YS. CT Imaging of Craniofacial Fibrous Dysplasia. *Case Rep Dent.* 2015;2015:134123.
10. Guruprasad Y, Prabhakar C. Craniofacial polyostotic fibrous dysplasia. *Contemp Clin Dent.*2010; 1(3):177-9.
11. Chen YR, Chang CN, Tan YC. Craniofacial fibrous dysplasia: an update. *Chang Gung Med J.*2006; 29(6):543-9.
12. Parekh SG, Donthineni-Rao R, Ricchetti E, Lackman RD. Fibrous dysplasia. *J Am Acad Orthop Surg.*2004; 12(5):305-13.

Conclusion

In conclusion, this case report showed that in rare cases, fibrous dysplasia can be seen with a well-defined, even corticated border, also involving of sphenoid bone is considerable in this case report. Therefore, after seeing this radiographic view, fibrous dysplasia should not be out of the mind.

Acknowledgments

We would like to thank the following for their cooperation: employees of Velayat Hospital, with special thanks to Dr. Farnaz Dehabadi.