

# Immunohistochemical analysis of Ki-67 expression in oral lichen planus lesions

## ***Original Article***

Nazanin Bashardoust<sup>1</sup>, Shirin Modabbernia<sup>1</sup>, Sara Bagheri<sup>1</sup>, Atena Shiva<sup>2</sup>, Reza Jalali<sup>3</sup>

<sup>1</sup> Assistant Professor, Department of Oral and Maxillofacial Pathology, Guilan University of Medical Sciences, Rasht, Iran.

<sup>2</sup> Assistant Professor, Department of Oral and Maxillofacial Pathology, Dental Faculty, Mazandaran University of Medical Sciences, Sari, Iran.

<sup>3</sup> Dentist

**Received:** Jun 13, 2015  
**Accepted:** Aug 17, 2015

**Corresponding Author:**  
**Shirin Modabbernia**

**Address:**  
Department of Oral and Maxillofacial Pathology,  
Faculty of Dentistry, Guilan University of Medical  
Sciences

**Telephone:** + 98 1333644828

**Email:** Shirinmodabbernia@yahoo.com

## **Abstract**

### **Introduction:**

Lichen planus is a chronic, relatively common, dermal mucosa disease. The World Health Organization (WHO) has introduced lichen planus as a premalignant condition. Ki-67 is a protein that can be detected in all active phases of the cell cycle, especially in the G2 and M phases. Considering the major role of Ki-67 in the regulation of the cell cycle and the fact that it is one of the conditions for pre-malignant potential and epithelial proliferation, the aim of this study was to evaluate Ki-67 expression in oral lichen planus (OLP) lesions.

### **Materials and methods:**

This study included 32 patients [16 with OLP and 16 with no OLP and a normal epithelium, which were considered the control group (CG)]. Demographic data was extracted from each patient's file and documented in an information form. Immunohistochemistry for Ki-67 was conducted using the EnVision method. P value was significant at <0.05.

### **Results:**

Ki-67 staining quality in the OLP group was significantly greater than the CG group according to both the Mann-Whitney test and quantity ( $p = 0.001$ ). The average percentage of positive cells in the OLP group was 13.11, while the average in the CG group was 2.26. Ki-67 staining in OLPs was 87.5% (++) and 62% with a strong degree of staining. Age and gender differences were compared using the independent t-test; no significant statistical differences were noted between the two groups.

### **Conclusion:**

Considering Ki-67 is a proliferation marker, the increased expression of Ki-67 in the OLP group's epithelium indicates a high proliferation rate in lichen planus lesions.

### **Key words:**

•Lichen Planus •Oral •Ki-67 Antigen •Cell Cycle

## Introduction

Lichen planus is a chronic, relatively common, dermal mucosa disease. Its etiology remains unknown. <sup>(1, 2)</sup> However, medications, dental material, food allergies or even viral or bacterial infections as well as immune deficiency may play a role or contribute to the pathogenesis. There is also a reported connection between oral lichen planus (OLP) and infections caused by Hepatitis C. <sup>(1)</sup> The role of stress as a cause for this disease remains debatable. <sup>(1, 3)</sup>

In 1910, the first case of OSCC (oral squamous cell carcinoma) was reported. Since then, much research has been conducted to detect the progression of OSCC to OLP. The World Health Organization (WHO) has introduced lichen planus as a premalignant or potentially precancerous condition. <sup>(2, 4, 5, 6)</sup>

Severe cellular damage in OLP leads to epithelial proliferation to maintain structural integrity. The transformation that occurs during the cell cycle in OLP causes progression of the lesion towards malignancy. Several different proteins control the cell cycle. Ki-67 is one such protein that can be detected in all active phases of the cell cycle, such as the G1, S, G2, and M phases, with the most prevalent activity in the G2 and M phases. <sup>(7)</sup>

Ki-67 is a nuclear, non-histone protein that can be found in two isoforms with molecular weights of 356 KDa and 320 KDa. The gene is located on chromosome 10 <sup>(6)</sup> and is traceable in the nucleus of all dividing cells. It is not exclusive to neoplastic tissues; it is prevalent in any non-neoplastic area that is affected by uncontrollable proliferation. <sup>(7)</sup> The Ki-67 antibody is used to diagnose neoplastic diseases and is also utilized to predict some kinds of cancer; immunohistochemistry is the most common method used to evaluate this protein. <sup>(7)</sup> The marker indicates the percentage of the nucleus occupied by the protein. Using this marker allows us to reliably evaluate the speed of proliferation. Considering the major role of Ki-67 in the regulation of the cell cycle and the fact that it is one of the conditions for pre-malignant potential and epithelial proliferation, we realized that studies on the role of Ki-67 in the occurrence of OLP are warranted. Therefore, we decided to evaluate the expression of this protein in patients suffering from OLP.

## Materials and Methods

This descriptive study of 32 samples included 16 OLP samples and 16 samples with a normal epithelium and no hyperplastic or dysplastic changes [irritation fibroma (IF)] were done. The samples were collected from the Noor pathobiology lab in Sari, Iran, between 2009 and 2011. Information regarding patient age and gender was extracted from each file and documented in the information form. Samples that lacked sufficient tissue for immunohistochemistry or had insufficient information were excluded.

In order to control the quality of the procedure, negative controls, with the primary antibody deleted, were stained for each section. The positive control for this study was undifferentiated carcinoma.

Thick tissue sections (4  $\mu$ m) were made from 10% formalin-fixed and paraffin-embedded oral lichen planus tissue that was deparaffinized in xylene and rehydrated in graded ethanol series. The sections were heated in 10 mM citrate buffer (pH: 6) twice for 7 and 5 min in a microwave oven at 450 watts and 800 watts, respectively. After cooling to room temperature, the slides were incubated with the following primary antibody: (Clone MIB-1, code N1633, ready-to-use N-series primary antibody, Glostrup, Dako, Denmark) for 60 min. After each section was washed in TBS, it was subjected to the EnVision staining method for 30 min. Subsequently, the sections were washed with the buffer solution for 5 min and then the reaction was revealed through the application of 3,3'-diaminobenzidine tetrahydrochloride (DAB). Finally, the sections were counterstained with Harris hematoxylin stain, then dehydrated and mounted. Cell counts were performed on 100 cells in 10 locations with the highest degree of nuclear staining using a MOT-IC microscope at 400 $\times$ .

Considering the percentage of stained cells (index of positivity), the samples were divided into 4 categories: negative (-); 1-10% positive cells (+), 11-40% positive cells (++), and < 41% positive cells (+++). <sup>(8)</sup>

The staining of the cells was quantitatively identified using the "modified quick score" method. The samples were classified into four categories: 1) Negative (without staining), 2) Weak, 3) Moderate, and 4) Strong. <sup>(9)</sup>

Scoring was performed by two observers. In cases of discrepancy, samples were rechecked and both conclusions were documented. In cases where the antigen occurrence was positive, the sample was regarded as positive. Data analyses were performed using SPSS software version 21 for Windows. The comparison of qualitative and semi-qualitative expression of Ki-67 was conducted between two study groups using the Mann–Whitney U test.

### Results

The average percentage of positive cells in the OLP group was 11 of 13 (85%), while the average IF was 0.26 (Table 1). Index of positivity for Ki-67 In 87.5% of OLP samples was (++) and 62% of the samples showed a strong degree of staining (Tables 2 and 3; Figure 1).

Age and gender differences were compared using the independent t-test. No significant statistical differences were noted between the two groups.

Staining of the Ki-67 marker in the OLP group was significantly greater than the IF group in quality and quantity (P = 0.001), according to the results of the Mann–Whitney test.

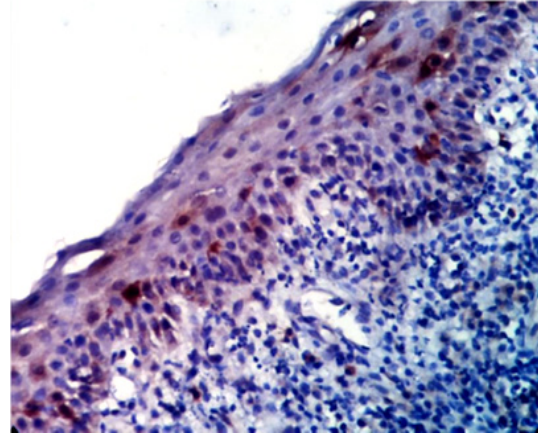


Figure1. Nuclear and cytoplasmic staining by ki-67 X40

Table 1. The average and standard deviation of the number of positive cells in 2 groups

Group	number	The minimum number of the positive cells	The maximum number of the positive cells	The average percentage of positive cells	Standard deviation(SD)
OLP	16	98(9/8%)	190(19%)	13/11%	2/86
IF	16	0(0%)	12(1/2%)	0/26%	0/36
Total	32	0(0%)	190(19%)	66/91%	68/26

Table 2. Index of positivity in 2 groups

Index of postivity Group	Negative(-)	1-10 %(+)	11-40 %(++)	40%> (+++)	total
OLP	0(0%)	2(12/5%)	14(87/5%)	0(0%)	16(100%)
IF	15(93/8%)	1(6/3%)	0(0%)	0(0%)	16(100%)
Total	15(46/9%)	3(9/4%)	14(43/8%)	0(0%)	32(100%)

Table 3. The quantitative expression of ki-67 marker in 2 groups

The intensity of the staining Group	Negative	weak	moderate	strong	Total
OLP	0(0%)	0(0%)	6(37/5%)	10(62/5%)	16(100%)
IF	9(56/3%)	3(18/8%)	4(25%)	0(0%)	16(100%)
Total	9(28/1%)	3(9/4%)	10(31/3%)	10(31/3%)	32(100%)

## Discussion

In our study, Ki-67 expression was positive in all OLP samples. Gonzales,<sup>(10)</sup> in similar research, showed the basal appearance of Ki-67 in 95.7% of OLP samples and 48.9% of sub-epithelial inflammation in OLP lesions. In a study done by Hosseini,<sup>(11)</sup> Ki-67 was detected in 52.67% of OLP cases, while the same study reported this biomarker was found in 7.33% of normal mucosa. The percentage of positive cases in Hosseini's study is much lower compared to our study; this could perhaps be related to the fact that fewer samples were studied in Hosseini's research, or it could be due to a difference in the methods used to evaluate the degree of staining.

Aung et al.<sup>(12)</sup> reported results similar to our study. Staining of Ki-67 in OLP, compared to the control group (normal mucosa), was significantly higher ( $p < 0.05$ ) in keratotic kinds, reticular and bullous, of lichen planus than the atrophic kind ( $p = 0.022$ ). In addition, the level of Ki-67 was related to dysplastic transformations ( $p: 0.037$ ). The results from Aung's study suggest that OLP with intense dysplasia has a higher potential to transform into OSCC.

In Neppelberg's study,<sup>(13)</sup> the intensity of Ki-67 staining in the epithelium was positive (+) in 77.3% of OLP samples and was (++) in 18.2% of OLP samples, which was significantly higher than in normal mucosa ( $p = 0.022$ ). The results obtained in the above study were similar to ours. Zargarani et al. (14) found that Ki-67 expression in OLP and epithelial dysplasia were similar and reported significantly higher levels in oral cellular carcinoma. This study showed that, in OLP, the risk of turning into malignancy is similar to the risk in epithelial dysplasia. Therefore, regular checkups are recommended.

Ki-67 has also been studied in other malignant and pre-malignant lesions, including leukoplakia and OSCC.<sup>(15, 16, 17, 18)</sup> Dragmir et al.<sup>(19)</sup> found a higher occurrence of Ki-67 in squamous cell carcinomas. Histopathological studies showed that dysplastic mucosa exists in all OSCC lesions. The presence of Ki-67 in dysplastic tissues without malignant transformation can indicate the importance of Ki-67 in the diagnosis of malignancy potential in pre-malignant lesions.<sup>(15)</sup> In a study by Vang et al.,<sup>(16)</sup> several markers, including Ki-67, were used in the early diagnosis of

esophagus squamous cell carcinomas. This was studied in normal tissues, reactive hyperplasia, and esophagus squamous cell carcinoma with high and low degrees of malignancy. Only in tumors with a high level of malignancy was a strong Ki-67 expression reported, demonstrating the sensitivity of this antigen for the identification of abnormal/normal tissues. Homayon et al.<sup>(20)</sup> evaluated the occurrence of Ki-67 in pre-malignant lesions and OSCC. Nearly all cases of OSCC and pre-malignant lesions, including leukoplakia and sub-mucous fibrosis, were positive for Ki-67.

This marker's occurrence in normal mucosa, however, was negative, matching our results. Staining for Ki-67 in most samples was limited to basal cells, except in OSCC, which showed staining in all layers, demonstrating that, when Ki-67 increases, normal mucosa transforms into dysplastic and malignant mucosa. In Premalata's study,<sup>(18)</sup> the amount of Ki-67 in OSCC was evaluated as high, average, or low. All samples were positive and a statistically significant difference was shown between the Ki-67 level in OSCC that was categorized as "high" differentiation and that which was categorized as "low" differentiation.

The most important factor indicating whether a lesion is progressing towards malignancy is the presence and intensity of dysplasia. Therefore, it is crucial to find markers of these changes.<sup>(19)</sup> Cellular proliferation in OLP is either similar to or greater than that in normal oral mucosa.

In a study by Neppelberg,<sup>(13)</sup> the high Ki-67 level in epithelium affected by OLP indicates increased proliferation. This is a result of the damage done to keratinocytes by inflammation. Ki-67 is a valuable marker of the capacity to proliferate. Most research shows that the production of this biomarker increases the probability of malignant and premalignant lesions of the oral cavity. The epithelium proliferation activity in OLP changes due to the effects of inflammation, causes damage to the genetic material of the cells, and necrotizes keratinocytes.<sup>(12)</sup> Nasser et al.<sup>(21)</sup> found that Ki-67 expression was detected in 45.9% of leukoplakia that presented without dysplasia. Leukoplakia has been proven to be a premalignant lesion and, in the present study, Ki-67 expression was seen in nearly all OLP samples, suggesting that lichen planus has the

potential to transform into malignancy. In Sadri et al.'s <sup>(22)</sup> study, 45% of esophageal SCC cases and 10% of OSCC cases showed strong Ki-67 expression. Their figures were lower than those reported in our study.

Since the expression of Ki-67 in OLP was greater than in normal mucosa, our conclusion is that Ki-67 in OLP, as a pre-malignant lesion, is a predictor of its transformation into OSCC. Some studies evaluated the role of other important proliferation factors, such as P16, P53, P63, P27, and bcl-2 in malignant and pre-malignant lesions of the oral cavity, like leukoplakia and OSCC.<sup>(20)</sup> In Zhong's study,<sup>(23)</sup> biomarkers P16, P53, and PCNA were evaluated in OLP, leukoplakia, and OSCC. Their studies showed a P53 gene mutation and, consequently, an increase in P53 expression along with decreased P16 expression and increased PCNA expression, which play a role in the progression of pre-malignant lesions of the oral cavity towards OSCC.

Staining for Ki-67 demonstrates the presence of this protein, but does not indicate the rate of proliferation. Therefore, an additional marker, like

CDK6, CDK4, or Cyclin D and a proliferation index, such as silver-stained nuclear-organized regions (Agnor) can be considered useful and effective in the future for the evaluation of this parameter.<sup>(12)</sup>

In some studies, contrary to the present one, decreased cell proliferation in OLP has been found. The protein, SMAD3, is active in the TGF- $\beta$  pathway and increased expression is seen in many cancers.<sup>(21)</sup> This protein, along with E-Cadherin and occluding factors, is also consequential in tumor progression.

On the whole, the results obtained in this study showed a significant increase in expression of Ki-67 in the epithelium of the OLP group, as compared to the IF group. Considering Ki-67 is a proliferation marker, this increased expression in epithelium affected by OLP indicates a high proliferation rate in this lesion. There has not been sufficient research in this area, and contradictory results have been reported. More studies in the malignancy potential of oral lichen planus are needed.

## References

1. Montebugnoli L, Venturi M, Gissi DB, et al. Immunohistochemical expression of p16 (INK4A) protein in oral lichen planus. *Oral Surg Oral Med Oral Pathol Oral Radiol Endod* 2011;112(2):222-7.
2. Poomsawat S, Buajeeb W, Khovidhunkit SO, et al. Overexpression of cdk4 and p16 in oral lichen planus supports the concept of premalignancy. *J Oral Pathol Med* 2011;40(4):294-9.
3. Bombeccari GP, Guzzi G, Tettamanti M, et al. Oral lichen planus and malignant transformation: a longitudinal cohort study. *Oral Surg Oral Med Oral Pathol Oral Radiol Endod* 2011;112(3):328-34.
4. Buajeeb W, Poomsawat S, Punyasingh J, et al. Expression of p16 in oral cancer and premalignant lesions. *J Oral Pathol Med* 2009;38(1):104-8.
5. Neville BW, Damm DD, Allen CM, Bouquot JE. *Oral and maxillofacial pathology*. 3rd ed. St. Louis: Saunders; 2009. p.380-420,765-90.
6. Regezi JA, Sciubba JJ, Jordan CK. *Oral pathology: Clinical pathologic correlations*. 6th ed. St. Louis: Saunders; 2012. p.51-73,97-102.
7. Mithani SK, Mydlarz WK, Grumbine FL, et al. Molecular genetics of premalignant oral lesions. *Oral Dis* 2007;13(2):126-33.
8. Kose O, Lalli A, Kutulola AO, et al. Changes in the expression of stem cell markers in oral lichen planus and hyperkeratotic lesions. *J Oral Sci* 2007;49(2):133-9.
9. Rubin E, Rubin R, Aaronson S. Neoplasia. In: Rubin E, Gorstein F, Rubin R, Schwarting R, Strayer D, editors. *Rubin's pathology clinicopathologic foundations of medicine*. 8th ed. USA: LWW; 2009. p.284-9.
10. González-Moles MA, Bascones-Ilundain C, Gil Montoya JA, et al. Cell cycle regulating mechanisms in oral lichen planus: molecular bases in epithelium in predisposed to malignant transformation. *Arch Oral Biol* 2006; 51:1093-103.
11. Agha-Hosseini F, Khalili M, Rohani B. Immunohistochemistry analysis of P53 and Ki-67 proteins in oral lichen planus and normal oral mucosa. *Iranian J Publ Health* 2009; 38:37-43.
12. Aung W, Htwe M, Win S. Evaluation of epithelial cell proliferation in oral lichen planus by using Ki-67 cell proliferative marker. *Myanmar Dent J* 2011; 18(1):40-9.
13. Neppelberg E. *Pathological mechanisms in oral lichen planus. A study of apoptosis-regulatory proteins and risk markers for malignant transformation* [ PhD Thesis]. Norway: Institute of Oral Sciences, Oral Pathology and Forensic

Odontology and Oral Surgery and Oral Medicine, Faculty of Dentistry, University of Bergen; 2007.

14.Zargaran M, Jamshidi S, Eshghyar N, et al. Suitability/unsuitability of cell proliferation as an indicator of malignant potential in oral lichen planus: an immunohistochemical study. *Asian Pac J Cancer Prev* 2013;14(11):6979-83.

15.Roopashree MR, Gondhalekar RV, Shashikanth MC, et al. Pathogenesis of oral lichen planus—a review. *J Oral Pathol Med* 2010;39(10):729-34.

16.Tsai CH, Yang CC, Chou LS, et al. The correlation between alteration of p16 gene and clinical status in oral squamous cell carcinoma. *J Oral Pathol Med* 2001;30(9):527-31.

17.Ramasubramanian A, Ramani P, Sherlin HJ, et al. Immunohistochemical evaluation of oral epithelial dysplasia using cyclin-D1, p27 and p63 expression as predictors of malignant transformation. *J Nat Sci, Biol Med* 2013;4(2):349-58.

18.Premalatha BR, Uma K. Analysis of Ki-67 antigen in human oral squamous cell carcinoma—an immunohistochemical study. *J Int Oral Health* 2010; 2(1):9-16.

19.Dragomir LP, Simionescu C, Margaritescu CL, et al. P53, p16 and Ki-67 immunoexpression in oral squamous carcinomas. *Rom J Morphol Embryol* 2012; 53(1):89-93.

20.Humayun S, Ram Prasad V. Expression of p53 protein and Ki-67 antigen in oral premalignant lesions and oral squamous cell carcinomas: an immunohistochemical study. *Nat J Maxillofac Surg* 2011; 2(1):38-46.

21.Nasser W, Flechtenmacher C, Holzinger D, et al. Aberrant expression of p53, p16INK4a and Ki-67 as basic biomarker for malignant progression of oral leukoplakias. *J Oral Pathol Med* 2011;40(8):629-35.

22.Sadri D, Shahsavari F, Alavi S. Expression of Ki-67 antigen in oral and esophagus squamous cell carcinoma. *Res Dent Sci* 2011; 8(1):34-40.

23.Zhong Li YF, Zhang Wei. Study on the expression of p53, p16 protein and PCNA in oral precancerous lesion and oral squamous cell carcinoma. *J Xinjiang Med Univ* 2002; (01):325-28.