

Endodontic Retreatment of a Maxillary First Molar with Unusual Palatal Root Canal Morphology: A Case Report

Case Report

Seyed Farooqh Ghotbi Rad¹, Seyed Roholla Havaei¹,
Elnaz Mousavi², Reza Kazemian¹

¹Department of Endodontics, Zahedan University of Medical Sciences, Zahedan, Iran.

²Department of Endodontics, Guilan University of Medical Sciences, Guilan, Iran.

Received: May 19, 2015

Accepted: Jun 21, 2015

Corresponding Author:

Seyed Roholla Havaei

Address: Department of Endodontics, Zahedan university of Medical Sciences, Zahedan, Iran

Telephone: +989215257093

Email: marty_zl@yahoo.com

Abstract

Introduction:

Variations in root canal morphology pose a challenge for successful endodontic treatment. The root canal anatomy of the maxillary first molar has been often described as three roots with four canals (two mesio-buccal, one distobuccal, and one palatal). The occurrence of two palatal canals in one palatal root is quite rare. This report represents the case of a maxillary first molar with unusual canal morphology in the palatal root and highlights the importance of thorough root canal exploration for successful endodontic treatment.

Key words:

•*Anatomic Variation* •*Molar* •*Root Canal Therapy*

Case Report

A 29-year-old male presented to the endodontics department of the Zahedan dental school with the chief complaint of pain in the preceding week. His medical history was noncontributory. On clinical examination, the left maxillary first molar (Tooth #14) was found to be without restoration. The tooth was also found to be sensitive to heat and tender upon percussion. No periodontal pockets or sinus tract was detected and tooth mobility was within normal limits. Radiographic examination showed previous endodontic treatment. A diagnosis of acute periapical periodontitis following an initial root canal treatment was made for tooth #14 (Figure 1). Following the administration of lidocaine 2% with 1:100000 epinephrine (Daroupakhsh, Tehran, Iran), the tooth was isolated with a rubber dam. The temporary filling was removed and access cavity was refined. The removal of the existing gutta-percha was carried out using a ProTaper rotary system (Dentsply Maillefer), and chloroform. The canals were explored using a #10 K-file, upon which a bifurcation was detected in the apical third of the palatal canal. Working length was determined and radiographically confirmed (Figure 2). The cleaning and shaping of the canals was performed using a Pro Taper rotary system (Dentsply Maillefer), except for the apical third of the palatal canal, which was prepared using precurved K-files. Copious irrigation with sodium hypochlorite 2.5% was maintained throughout the instrumentation pro-

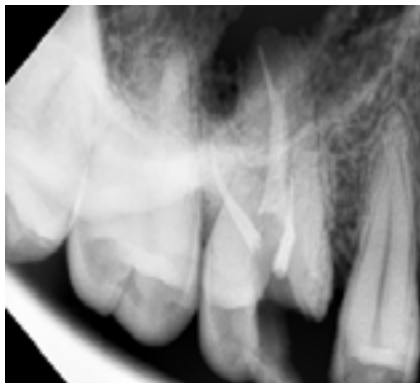


Figure 1. Left maxillary first molar (#14) with previous endodontic treatment.

cedure. Thereafter, calcium hydroxide (Daroupakhsh, Tehran, Iran) was placed in the canals, and the access cavity was sealed using Cavit (ESPE, Seefeld, Germany). One week later, the tooth was found to be asymptomatic, and the canals were obturated with a cold lateral condensation technique using gutta-percha (Gapadent, Hamburg, Germany) and AH plus sealer (Dentsply, Maillefer) (Figures 3 & 4). The tooth was temporarily sealed using Cavit, and the patient was referred for permanent restoration (Figure 5).

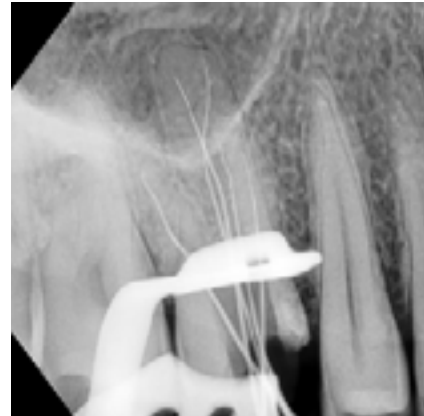

Figure 2. Removal of gutta-percha and detection of the missed canal in tooth #14.

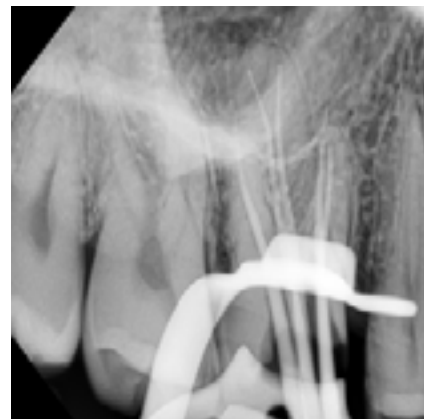

Figure 3. Placement of master cones in tooth #14.

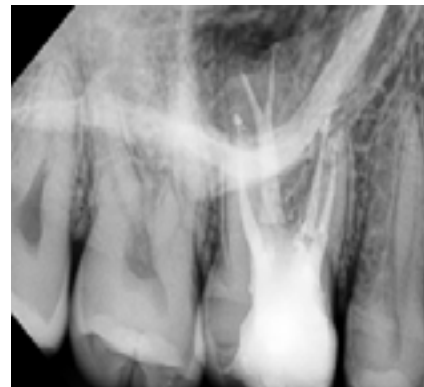


Figure 4. Final obturation of tooth #14.

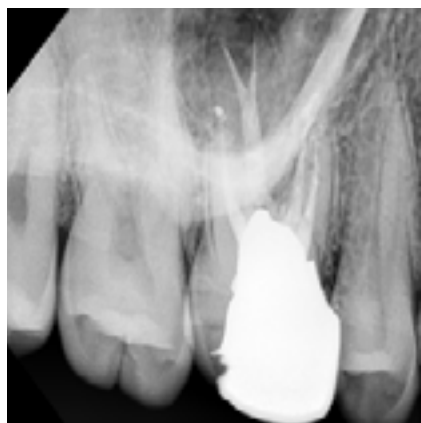

Figure 5. Final restoration of tooth #14.

Discussion

Successful endodontic therapy requires adequate cleaning, shaping, and obturation of the entire root canal system to thoroughly remove bacteria. The main cause of endodontic failure has been attributed to the presence of microorganisms inside the root canal system.⁽¹⁾ Therefore, a thorough knowledge of both normal and abnormal root canal morphology can prevent endodontic failure due to incomplete instrumentation and obturation of the root canal system.⁽¹⁾ Numerous variations in terms of canal number and morphology have been reported in maxillary molars.⁽²⁾ The majority of maxillary molars have roots with three or four canals (two mesiobuccal canals, one distobuccal canal, and one palatal canal). The presence of a second mesiobuccal canal has been shown to be the most common variation with an incidence of 18–96.1%.^(3, 4) Beatty reported a maxillary first molar with three canals in the mesiobuccal root.⁽⁵⁾ In a report by Bond et al., a maxillary first molar with six root canals (two canals in each of the mesiobuccal, distobuccal, and palatal roots) was presented.⁽⁶⁾ Maggiore et al. reported a case of a maxillary first molar with six root canals (three in the palatal, two in the mesiobuccal, and one in the distobuccal root).⁽⁷⁾

In a study by Christie et al., a double palatal root was reported in maxillary molars; this phenomenon was mostly limited to maxillary second molars.^(8, 9) Similar configurations were reported separately by Su-Jung-Shin et al. and Ghoddusi et al.^(10, 11)

The prevalence of variations in palatal canal

morphology is not very common in maxillary molars.⁽¹²⁾ In particular, a very low incidence has been reported for the presence of two canals in a single palatal root.⁽¹³⁻¹⁷⁾ Using the clearing technique, Wasti et al. found a high incidence of 33% for bifurcation of palatal canals in the maxillary first molar.⁽¹⁸⁾ This was in contrast to the findings in a review by Cleghorn et al., who reported palatal roots with one canal and one foramen in 99% and 98% of cases, respectively.⁽¹⁹⁾ Meanwhile, in a study of 125 maxillary first molars, Rouhani et al. found only two teeth with palatal canals presenting configurations other than type II, which included one tooth with type IV and one with type II variations.⁽²⁰⁾

Stone and Stoner found multiple variations in the palatal roots of maxillary molars. They reported a single palatal root containing two separate orifices and apical foramina, two separate roots with single canals each and, finally, one single palatal root with one orifice, a bifurcated canal, and two foramina.⁽²¹⁾ Holderrieth reported four cases of maxillary first and second molars with palatal canals having type IV and V configurations, as defined by Vertucci.⁽²²⁾ The current case report represents a maxillary first molar with unusual palatal root morphology and underlines the importance of knowledge of the anatomy of root canal systems.

Conclusion

Bearing in mind the limitations of preoperative radiographs with regards to interpretation, a strong emphasis should be placed on the exploration of the pulp chamber floor using high magnification and illumination as well as that of the root canal walls via precurved hand files. Regardless of the relatively low prevalence of root canal variations, knowledge of their anatomy is essential in the prevention of incomplete cleaning and shaping procedures related to missed canals.

References

1. Kakehashi S, Stanley H, Fitzgerald R. The effects of surgical exposures of dental pulps in germ-free and conventional laboratory rats. *Oral Surg Oral Med Oral Pathol* 1965;20:340-9.
2. Wong M. Maxillary first molar with three palatal canals. *J Endod* 1991;17(6):298-9.
3. Kulid JC, Peters DD. Incidence and configuration of canal systems in the mesiobuccal root of maxillary first and second molars. *J Endod* 1990;16(7):311-7.
4. Buhrley LJ, Barrows MJ, BeGole EA, Wenckus CS. Effect of magnification on locating the MB2 canal in maxillary molars. *Journal of Endodontics*. 2002;28(4):324-7.
5. Beatty RG. A five-canal maxillary first molar. *J Endod* 1984;10(4):156-7.
6. Bond JL, Hartwell G, Portell FR. Maxillary first molar with six canals. *J Endod* 1988;14(5):258-60.
7. Maggiore F, Jou Y, Kim S. A six-canal maxillary first molar: Case report. *Int Endod J* 2002;35(5):486-91.
8. Peikoff M, Christie W, Fogel H. The maxillary second molar: Variations in the number of roots and canals. *Int Endod J* 1996;29(6):365-9.
9. Jacobsen E, Nii C. Unusual palatal root canal morphology in maxillary molars. *Endod Dent Traumatol* 1994; 10(1):19-22.
10. Shin S-J, Park J-W, Lee J-K, Hwang S-W. Unusual root canal anatomy in maxillary second molars: Two case reports. *Oral Surg Oral Med Oral Pathol Oral Radiol Endod* 2007;104(6):e61-5. Epub 2007 Oct 17.
11. Ghoddusi J, Mesgarani A, Gharagozloo S. Endodontic re-treatment of maxillary second molar with two separate palatal roots: a case report. *Iran Endod J* 2008 Summer;3(3):83-5. Epub 2008 Jul 10.
12. Alavi A, Opananon A, Ng YL, Gulabivala K. Root and canal morphology of Thai maxillary molars. *Int Endod J* 2002;35(5):478-85.
13. Christie W, Peikoff M, Fogel H. Maxillary molars with two palatal roots: A retrospective clinical study. *J Endod* 1991;17(2):80-4.
14. Baratto-Filho F, Fariniuk L, Ferreira E, Pecora J, et al. Clinical and macroscopic study of maxillary molars with two palatal roots. *Int Endod J*. 2002;35(9):796-801.
15. Çalışkan MK, Pehlivan Y, Sepetçioğlu F, Türkün M, et al. Root canal morphology of human permanent teeth in a Turkish population. *J Endod*. 1995;21(4):200-4.
16. Thomas R, Moule A, Bryant R. Root canal morphology of maxillary permanent first molar teeth at various ages. *Int Endod J* 1993; 26(5):257-67.
17. Barbizam JVB, Ribeiro RG, Tanomaru Filho M. Unusual anatomy of permanent maxillary molars. *J Endod* 2004;30(9):668-71.
18. Wasti F, Shearer A, Wilson N. Root canal systems of the mandibular and maxillary first permanent molar teeth of South Asian Pakistanis. *Int Endod J* 2001;34(4):263-6.
19. Cleghorn BM, Christie WH, Dong CC. Root and root canal morphology of the human permanent maxillary first molar: A literature review. *J Endod* 2006;32(9):813-21.
20. Rouhani A, Bagherpour A, Akbari M, Azizi M, et al. Cone-beam computed tomography evaluation of maxillary first and second molars in Iranian population: A morphological study. *Iran Endod J* 2014;9(3):190.
21. Stone LH, Stroner WF. Maxillary molars demonstrating more than one palatal root canal. *Oral Surg Oral Med Oral Pathol* 1981; 51(6):649-52.
22. Holderrieth S, Gernhardt CR. Maxillary molars with morphologic variations of the palatal root canals: A report of four cases. *J Endod* 2009;35(7):1060-5.