

Evaluation of the Elongation and Calcification Patterns of the Styloid Process with Digital Panoramic Radiography

Original Article

Khojastepour Leila¹, Dastan Farivar², Ezoddini-Ardakani Fatemeh³

¹ Professor, Department of Oral and Maxillofacial Radiology, Faculty of Dentistry, Shiraz University of Medical Science, Shiraz, Iran.

² Dental student. Department of Oral and Maxillofacial Radiology Faculty of Dentistry, Shiraz University of Medical Sciences, Shiraz, Iran.

³ Professor. Department of Oral and Maxillofacial Radiology Faculty of Dentistry, Shahid Sadough University of Medical Sciences Yazd, Iran .

Received: 17 May 2015

Accepted: 25 Jun 2015

Corresponding Author:

Fatemeh Ezoddini Ardakani

Address: Department of Oral and Maxillofacial Radiology, Faculty of Dentistry, Daheye Fajr Bouly, Imam Ave, Yazd, Iran.

Telephone: + 98 351 6255881-4

Email: + 98 351 6250344

Abstract

Introduction:

The styloid process (SP) has the potential for calcification and ossification. The aim of this study was to investigate the prevalence of different patterns of elongation and calcification of the SP.

Materials and methods:

In this cross-sectional study, 400 digital panoramic radiographs taken for routine dental examination in the dental school of Shiraz University were evaluated for the radiographic features of an elongated styloid process (ESP). The apparent length of SP was measured with Scanora software on panoramic of 350 patient who met the study criteria, (204 females and 146 males). Lengths greater than 30mm were considered as ESP. ESP were also classified into three types based on Langlais classification (elongated, pseudo articulated; and segmented). Data were analyzed by the Chi squared tests and Student's t-tests.

Results:

ESP was confirmed in 153 patients including 78 males and 75 females (43.7%). The prevalence of ESP was significantly higher in males. 53.8% of males and 36.8% of female patients has ESP (P value < 0.05). ESP was also significantly more common in the older age group (p < 0.05). There was no statistically significant difference between the occurrence of unilateral and bilateral ESP (p > 0.05). Type I and Type II ossification pattern had almost equal frequency (42.5% and 43.8% respectively)

Conclusion:

ESP and calcification of stylohyoid ligament can be easily detected in panoramic radiographs and is more common in older patients.

Key words:

•Tooth Calcification •Radiography •Panoramic •Eagle syndrome

Introduction

The styloid process is a part of the temporal bone, which arises downwards, forwards, and slightly medially in front of the stylomastoid foramen, and its name is derived from the Greek word “stylos” meaning a pillar.⁽¹⁾ The SP develops from Reichert’s cartilage of the second brachial arch.⁽²⁾ The attached structures are the stylohyoid, stylopharyngeus, and styloglossus muscles, and the stylomandibular ligaments. Many nerves and vessels, including the carotid arteries, are adjacent to the SP.⁽³⁻⁵⁾ Elongated SP (ESP) has been drawing the attention of researchers since long ago. In 1937 Eagle was the first one who documented a cases in which elongation of the styloid process (over 25 cm), or calcification of the stylohyoid ligament, appeared to be the cause of pharyngeal and cervical pain.⁽⁶⁾ The normal length of the SP is about 20–30 mm; SPs that are >30 mm are considered as elongated styloid processes (ESPs).⁽⁷⁻¹⁰⁾ ESP can cause symptoms such as dull pain in the ears or mastoid region, and it may cause the sensation of a foreign body in the pharynx and, thus, discomfort while swallowing. In addition, it can sometimes cause symptoms of temporomandibular dysfunction, e.g., limited or asymmetric jaw movements and clicks.⁽¹¹⁾ Rarely, ESP may lead to stroke because of compression of the carotid arteries.⁽¹²⁾ ESP is diagnosed by both radiographical and physical examinations. Panoramic radiography is one of the most useful radiographs that show the stylohyoid process and used commonly for routine dental examinations. it could be also useful for early diagnosis of ESPs and referring the patients forward for additional tests.⁽¹³⁾ Several studies have been conducted on the prevalence of ESP and its features in different geographical and ethenical place ,and most of them were done based on to panoramic radiographs.^{7, 14-23)} somehow different results however were obtained even in the same region. Considering this issue in our country based on available litterateur in English and Persian there were different report for prevalence. of ESP, as well as its age and sex distribution.^(19, 20, 23, 24) Few information also was reported about the type of this calcification.^(19, 24) So the aim of this study was to assess the prevalence of SP elongation and its calcification pattern in relation to gender and age.

Materials and Methods

In this cross sectional study, 400 digital panoramic radiographs taken for routine dental examination were evaluated in dental school of shiraz university for the presence and radiographic features of elongated SP. All panoramic radiographs were acquired using a CRANEX D digital panoramic device (SOREDEX, Finland Helsinki). Only those radiographs showing SP of both sides were included. Positioning errors, positive history of fracture or developmental anomalies were considered as exclusion criteria. The apparent length of the styloid process was measured by measurement tools of the Scanora software (Scanora Soredex) in a total of 350 digital panoramic radiographs which fulfilled the study criteria belonging to 204 females and 146 males. The magnification factor of panoramic machine(1.26) was considered to assess actual SP length. The length of styloid process was measured according to method, described by Ilgüy et al.⁽⁸⁾ as the distance from the point where the styloid left the tympanic plate to the tip of the process, regardless of whether or not the styloid process was segmented. The styloid process measuring more than 30 mm was considered as elongated.⁽⁷⁻⁹⁾ Stylohyoid or stylomandibular ligaments ossification were measured along with SP, as a part of the elongated SP. Radiographic features of the type of elongation of SP was recorded based on Langlais⁽²⁵⁾ classification in three categories as followed:

Type I: elongated SP (appear as uninterrupted integrity: Figure I)

Type II: pseudo articulated SP (apparently joined to the styloid process or stylohyoid ligament)

Type III: segmented SP. either short or long non continuous portion/interrupted segments of mineralization.

Figure 2 illustrate Type II ESP in left and Type III ESP in right side respectively .

The prevalence of elongated SP as well as the types of elongation were compared between two age groups (> 40 and ≤40 years old).

Statistical Analysis: The prevalence of different types of calcification of ESP in different age and sex groups were assessed using Chi square and the prevalence of left and right sides in both age and sex groups were compared using “Student’s t-test”. Statistical software package SPSS V.15.0

(Chicago, IL) was used for analyzing data. The significance level was set at 0.05.

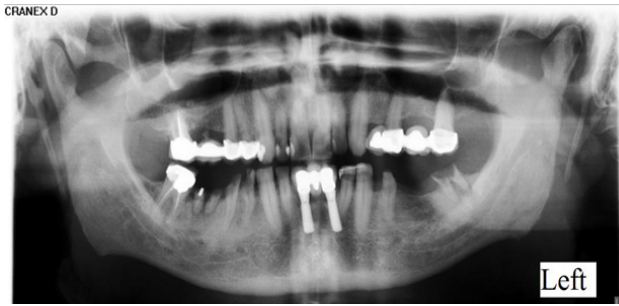


Figure 1. Bilateral Type I, ESP (ESP with uninterrupted integrity)

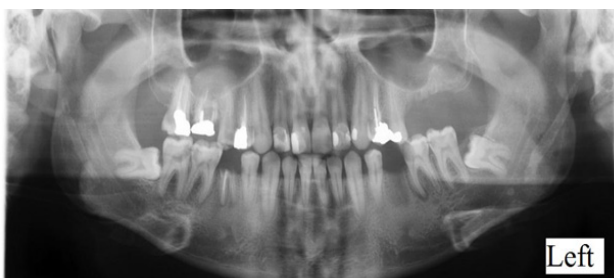

Figure 2. Type II, Pseudo articulated SP or apparently joined elongated styloid process in left side. Type III or Segmented ESP (interrupted segments of mineralization) in right side

Results

The mean age of patients with elongated SP was 46.7 ± 9.2 age range. The mean lengths of elongated SP was 3.70 ± 0.64 mm.

Table 1. Prevalence of Calcification according to the type of calcification among study population in different sex and age group

	Type I N (%)	Type II N (%)	Type III N (%)	P value#
Female	31(41.3)	32(42.7)	12(16)	0.72
male	34(43.6)	35(44.9)	9(11.5)	
<40	13(37.1)	16(45.7)	6(17.1)	0.99
>40	52(44.1)	51(43.2)	15(12.7)	

Chi square Test ($\alpha = 0.05$)

Table 2. Mean length of the left and right styloid process in different genders.

Gender	Right		Left	
	N (%)	Mean± SD	N (%)	Mean± SD
Female	57 (47%)	3.61±0.68	53(50%)	3.63±0.54
male	62(53%)	3.87±0.87	53(50%)	3.76±0.71
P value#	0.07		0.29	

Student T test ($\alpha = 0.05$), SD: Standard Deviation

One hundred and fifty three patients(43.7%) out of 350 had ESP (more than 30 mm). Among them, 36.8%(75) were females and 53.8% (78) were males. The prevalence of ESP was significantly higher in males ($p < 0.05$).

Elongated SP was also significantly more common in older age group ($p < 0.05$). Thirty five (37.2%) out of 153 cases with ESP were 40 years old or younger and 118 (46.3%) cases were more than 40 years old. There was no statistically significant difference between unilateral and bilateral occurrence of ESP. A total of 82 (23.4%) subjects had unilateral SPE and 71 (20.3%) had bilateral ESP. ($P > 0.05$).

The numbers of right side ESP were more than left side ESP (table 1). The right side SP was longer in men, and the left side was equal in both genders but difference was not statistically significant (table 1).

In the ESP cases, 65(42.5%) were Longlais type I, 67 (43.8%) were type II, and 21 (13.7%) were type III. In both of male and female groups, Longlais pattern I and II were approximately equal and they were more than pattern III (table 2). In the younger age group, pattern type II (45.7%) was more common than pattern type I (37.1%) and type III (17.1%).

Table 3. Mean length of the left and right styloid process in the different ages.

Age Group	Right		Left	
	N (%)	Mean± SD	N (%)	Mean± SD
≤40	27(23%)	3.72±0.54	23(21%)	3.61±0.53
>40	92(77%)	3.75±0.85	83(78%)	3.72±0.66
P value#	0.87		0.49	

Student T test ($\alpha = 0.05$), SD: Standard Deviation

Discussion

SP is a part of temporal bone with important adjacent organs. Therefore, the solidification of SP and ligament causes pain in the oropharynx and face. The ESP can be diagnosed by either plain radiography (panoramic, PA skull, Lateral skull, Town) or advanced imaging such as CT, CBCT.^(24, 26, 27) The widespread use of panoramic radiography in dentistry and good visualization of styloid process in properly taken panoramic make it an favorable image for evaluation the prevalence and type of ESP and for these reasons we used panoramic views in present study. The pathogenesis of elongation of the styloid process or calcification of the stylohyoid ligament, is still remain unknown however it could be consider as a possible cause of pharyngeal and cervical pain and practitioners, especially dentists should be aware of its prevalence and the related radiological features.⁽²⁸⁾

the reported percentage for Stylohyoid ligament calcification varied between 4% and 84.4%.^(6, 17)

Many researchers have compared the prevalence and severity of mineralized area in stylohyoid ligament with age and sex and different results are obtained. In the present study, we observed that the length of SP increased by age and it is consistent with most of the previous studies^(5, 16-22, 29) and in contrast to few others which denied any relation between ESP and age.^(14, 15, 24)

Based on the present study, we found that the prevalence of ESP was higher in males and it was statistically significant. However, these findings were against the results of a similar study conducted by Ferrario et al⁽¹⁷⁾ and Roopashri et al.⁽¹⁾ Roopashri et al⁽¹⁾ found that ESP was more common in female and by comparing their result to

Ferrario et al⁽¹⁷⁾ study proposed that it could be related to endocrine disorders of women during menopause. The results of similar studies in Iran did not support this idea. According to present study as well as Ghafarriet al reports ESP is more common among male patients. Shakibaei et al,⁽²⁴⁾ Zangoi et. Al.⁽²³⁾ and Anbiaei et al.⁽²⁰⁾ also did not find any significant differences between the prevalence of ESP in different genders.

According to our results there was no significant difference between the prevalence of various type of ESP while the percentage of type I and type II were almost equal. Our results in this regard is very similar to Roopashri et al⁽¹⁾ and inconsistent with the result of (Ghaffari et al⁽¹⁹⁾ and More et al⁽³⁰⁾ studies in which they reported type I ESP in more than 80% of their cases.^(19, 30) Different quality of digital Panoramic radiographs and conventional ones could explain the difference between our result and Ghaf-faei et al.

Although ESP in the right side was a little more than the left side, based on the present study It was not significant and our results in this regards was similar to zangoei et al⁽²³⁾ and More et al⁽³⁰⁾ studies. , we found that unilateral elongation (23.4%) was more prevalent than bilateral elongation (20.3%), but it was not statistically significant. It is in accordance with zangoei et al⁽²³⁾ and in contrast with Roopashri et al⁽¹⁾ studies. Panoramic radiography could be considered as the first imaging choice for screening the orofacial pain. Considering mentioned controversy further study with larger sample sizes and possible clinical examination could be helpful to estimated the relevance of panoramic radio-

graph finding about ESP, its type and pattern of calcification with patients pain and discomfort in orofacial region .

Conclusion

ESP and calcification of stylohyoid ligament can be easily detected in panoramic radiographs. Therefore it can help us to distinguish this problem from the other types of maxillofacial pain such as: pharyngeal, muscular, tonsillar and dental pain. Detecting the true origin of pain can help the clinician to manage the problem correctly.

References

- 1.Roopashri G, Vaishali M, David MP, Baig M, Shankar U. Evaluation of elongated styloid process on digital panoramic radiographs. *J Contemp Dent Pract* 2012;13(5):618-22.
- 2.Reddy RS, Kiran CS, Madhavi NS, Raghavendra MN, et al. Prevalence of elongation and calcification patterns of elongated styloid process in south India. *J Clin Exp Dent* 2013 Feb 1;5(1):e30-5. doi: 10.4317/jced.50981. eCollection 2013.
- 3.Casale M, Rinaldi V, Quattrocchi C, Bressi F, et al. Atypical chronic head and neck pain: don't forget Eagle's syndrome. *Eur Rev Med Pharmacol Sci* 2008 Mar-Apr;12(2):131-3.
- 4.BOZKIR MG, BOĞA H, DERE F. The evaluation of elongated styloid process in panoramic radiographs in edentulous patients. *Turk J Med Sci* 1999;29(4):481-6.
- 5.Gözil R, Yener N, Calgüner E, Arac M, et al. Morphological characteristics of styloid process evaluated by computerized axial tomography. *Ann Anat* 2001 Nov;183(6):527-35.
- 6.EAGLE WW. Elongated styloid process: symptoms and treatment. *AMA Arch Otolaryngol* 1958 Feb;67(2):172-6.
- 7.Correll RW, Jensen JL, Taylor JB, Rhyne RR. Mineralization of the stylohyoid-stylomandibular ligament complex: A radiographic incidence study. *Oral Surg Oral Med Oral Pathol.* 1979 Oct;48(4):286-91.
- 8.İlgüy M, İlgüy D, Güler N, Bayirli G. Incidence of the type and calcification patterns in patients with elongated styloid process. *J Int Med Res* 2005 Jan-Feb;33(1):96-102.
- 9.Kaufman SM, Elzay RP, Irish EF. Styloid process variation: radiologic and clinical study. *A Arch Otolaryngol* 1970 May;91(5):460-3. 1970;91(5):460-3.
- 10.Krennmair G, Piehslinger E. Variants of ossification in the stylohyoid chain. *Cranio* 2003 Jan;21(1):31-7.
- 11.Gokce C, Sisman Y, Sipahioğlu M. Styloid Process Elongation or Eagle's Syndrome: Is There Any Role for Ectopic Calcification? *Eur J Dent* 2008 Jul;2(3):224-8.
- 12.Bernhardt O, Gesch D, Schwahn C, Bitter K, et al. Signs of temporomandibular disorders in tinnitus patients and in a population-based group of volunteers: results of the Study of Health in Pomerania. *J Oral Rehabil* 2004 Apr;31(4):311-9.
- 13.Faivre A, Abdelfettah Z, Rodriguez S, Nicoli F. Bilateral internal carotid artery dissection due to elongated styloid processes and shaking dancing. *J Neurol Neurosurg Psychiatry* 2009 Oct;80(10):1154-5. doi: 10.1136/jnnp.2008.159954
- 14.Rizzatti-Barbosa CM, Ribeiro MC, Silva-Concilio LR, Di Hipolito O, et al. Is an elongated stylohyoid process prevalent in the elderly? A radiographic study in a Brazilian population. *Gerodontology* 2005 Jun;22(2):112-5.
- 15.Scaf G, Freitas DQd, Loffredo LdCM. Diagnostic reproducibility of the elongated styloid process. *J Appl Oral Sci* 2003 Jun;11(2):120-4.
- 16.Carroll MKO. Calcification in the stylohyoid ligament. *Oral Surg Oral Med Oral Pathol*1984;58(5):617-21.
- 17.Ferrario VF, Sigurta D, Daddona A, Dalloca L, et al. Calcification of the stylohyoid ligament: incidence and morpho-quantitative evaluations. *Oral Surg Oral Med Oral Pathol* 1990;69(4):524-9.
- 18.Shaik MA, Naheeda SMK, Wahab A, Hameed S. Prevalence of elongated styloid process in Saudi population of Aseer region. *Eur J Dent* 2013 Oct;7(4):449-54. doi: 10.4103/1305-7456.120687.
- 19.ghafari R, Dalili Z, Abdolapur S. A study on the frequency of elongated styloid process and eagle's syndrome among patients admitted to Guilan dental school clinic (2005-2006). 2010.
- 20.Anbiaee N, Javadzadeh A. Elongated styloid process: Is it a pathologic condition? *Indian J Dent Res* 2011 Sep-

Acknowledgement

This manuscript has been extracted from Ms. Farivar Dastan's DDS thesis that was conducted under the supervision of Dr. Leila Khojastepour. The study was approved, registered with ID 09-01-21-7460, and supported by Office of Vice Chancellor for Research of Shiraz University of Medical Sciences. The authors wish to thank Dr.Mehradad Vossoghi, for the statistical analysis.

Oct;22(5):673-7. doi: 10.4103/0970-9290.93455.

21. Jaju P, Suvarna P, Parikh N. Eagles syndrome. An enigma to dentists. *J Indian Acad Oral Med Radiol* 2007;19(3):424-9.
22. Al-Khateeb TH, Ma'mon al Dajani T, Al Jamal GA. Mineralization of the stylohyoid ligament complex in a Jordanian sample: a clinicroadiographic study. *J Oral Maxillofac Surg* 2010 Jun;68(6):1242-51. doi: 10.1016/j.joms.2009.07.090. Epub 2009 Dec 14.
23. Zangouei Booshehri M, Ezoddini Ardakani F, Rasooli A, Sarayedar Baser R, et al. Incidence of Stylohyoid Ligament Calcification and Its Length in an Iranian Adult Population. *The Journal of Shahid Sadoughi university of Medical Sciences* 2011, 19(2): 211-218. Persian.
24. Shakibaei Z, Tohidi E, Salemi F, Saati S. Prevalence of Stylohyoid Ligament Calcification on Panoramic Radiographs in an Iranian Population. *JDMT*2014;4(1):21-8.
25. Langlais RP, Miles DA, Van Dis ML. Elongated and mineralized stylohyoid ligament complex: a proposed classification and report of a case of Eagle's syndrome. *Oral Surg Oral Med Oral Pathol* 1986;61(5):527-32.
26. Khairallah A. CBCT Findings of Complete Calcification of the Stylohyoid Ligament: Case Reports. *J Dent Health Oral Disord Ther* 2015;2(2):00040.
27. Öztunç H, Evlice B, Tatli U, Evlice A. Cone-beam computed tomographic evaluation of styloid process: a retrospective study of 208 patients with orofacial pain. *Head Face Med* 2014; 10: 5.
28. Kosar M, Atalar M, Sabanclogullari V, Tetiker H, et al. Evaluation of the length and angulation of the styloid process in the patient with pre-diagnosis of Eagle syndrome. *Folia Morphol (Warsz)* 2011 Nov;70(4):295-9.
29. Gokce C, Sisman Y, Ertas ET, Akgunlu F, et al. Prevalence of styloid process elongation on panoramic radiography in the Turkey population from cappadocia region. *Eur J Dent* 2008 Jan;2(1):18-22.
30. More CB, Asrani MK. Evaluation of the styloid process on digital panoramic radiographs. *Indian J Radiol Imaging* 2010 Nov; 20(4): 261-265.