

Associations between Impaction Depth of the Mandibular Third Molar and Pathological Conditions

Original Article

Mokhtar Ali ¹, Bronoosh Pegah ², Haghnegahdar Abdolaziz ³

¹ Resident of Orthodontics at Islamic Azad University, Dental Faculty, Tehran, Iran

² Oral and Maxillofacial Radiologist at Alborz Radiology Center, Karaj, Iran

³ Assistant Professor at Shiraz University of Medical Sciences, Oral and Maxillofacial Radiology Department, Shiraz, Iran

Received: 11 Apr 2015

Accepted: 21 Jun 2015

Corresponding Author:

Ali Mokhtar

Address:

Department of Orthodontics, Islamic Azad University, Dental Branch, Tehran, Iran, PO Box 19585-175

Email: ali.mokhtar1989@gmail.com

Telephone: +982122526237

Abstract

Introduction:

Impacted and partially erupted third molars can cause various symptoms and pathologies. The aim of this study was to determine the association between commonly observed pathological conditions and the impaction depth of lower third molar teeth.

Materials and methods:

In this retrospective study, 370 panoramic radiographs including 724 lower third molars were evaluated to assess several pathologies according to impaction depth. The patients were also examined clinically for pericoronitis. Impaction depth was defined according to horizontal indices in class I, II, or III, where none, less than half, or more than half of the crown was in the ramus of the mandible, respectively. The vertical indices for teeth, classes A, B, and C, were defined by the highest portion of the tooth being on a level with or above the occlusal plane, below the occlusal plane but above the cervical line of the second mandibular molar, or below the cervical line of the second mandibular molar, respectively. The data were analyzed using Chi-squared tests.

Results:

Of the teeth analyzed, 57%, 28.4%, and 14.6% were at vertical level A, B, and C, respectively. Of the 605 mandibular third molars, 363 (60%) were in horizontal class I, 212 (35%) were in class II, and 31 (5%) were in class III. Incidence of pericoronitis was significantly associated with partially erupted third molars and impactions of class II ($P = 0.028$). Class A impaction showed a stronger association than classes B or C with all conditions ($P = 0.04$) except for bone loss and root resorption of second molars ($P = 0.07$).

Conclusion:

Class A impaction depth, where the highest portion of the tooth was on a level with or above the occlusal plane, was associated with more pathological conditions than classes B or C.

Key words:

•Molar •Third. Tooth •Impacted. Radiography •Panoramic.

Introduction

Impacted and partially erupted third molars can cause various symptoms and pathologies such as bone loss, root resorption of adjacent teeth, odontogenic cysts and tumors, pericoronitis, and systemic infections (Figures 1–5).^(1–6)

Currently, there is a huge debate in the dental literature regarding clinical management of impacted third molars.^(1, 2, 6) Although the decision to remove a symptomatic third molar is a straightforward one, the prophylactic removal of asymptomatic third molars remains a controversial issue.⁽⁶⁾

The decision to remove asymptomatic third molars is based on the likelihood of these teeth developing a pathological condition. The development of symptoms and pathologies can be affected by the impaction depth and angulation of impacted teeth.^(1, 5, 7) The eruption issues of the third molars can also depend on factors such as race or diet.^(8, 9) Therefore, evaluating the impaction of third molars and the commonly associated complications across various countries and populations is important. To date, no study has investigated the prevalence of pathological conditions associated with impacted mandibular third molars in an Iranian population. Thus, the aim of this study was to assess, in Iranian patients, the prevalence of symptoms and pathologies, including pericoronitis, second molar caries, second molar bone loss, third molar caries, root resorption, osteitis, follicular space, and temporomandibular disorders (TMD), associated with impacted mandibular third molars in relation to their impaction depth.

Materials and Methods

In total, 370 healthy patients (i.e., without any systemic disease), including 149 men and 221 women between 25 and 40 years old, who had been referred for any reason to the oral and maxillofacial radiology department of Shiraz Dental School between January and July 2012, were taken as the sample in this study.

Panoramic radiographs (Planmeca Proline XC, Finland) acquired from the sample patients were examined separately by an experienced oral radiologist and a dental student for evidence of six pathologic conditions: root resorption, bone loss, caries of the third molar, distal caries of second

molar, osteitis, and follicular space abnormality. An experienced oral and maxillofacial radiologist and a dental student conducted separate clinical evaluations of the patients for evidence of pericoronitis. Since TMD can mimic many symptoms of an impacted third molar⁽¹⁰⁾, the presence of TMD was also evaluated in this study. Patients with masticatory muscle spasm, periauricular/intra-acoustic tenderness, or joint sound were considered as TMD positive. The level of impaction of the mandibular third molars was categorized using the Pell and Gregory classification.⁽¹¹⁾ Horizontal indices were defined as follows: class I: none of the crown was in the ramus of the mandible; class II: less than one-half of the crown was in the ramus; class III: more than half of the crown was in the ramus. Vertical indices were also defined as one of three classes: class A: the highest portion of the tooth was level with or above the occlusal plane; class B: the highest portion of the tooth was below the occlusal plane but above the cervical line of the second mandibular molar; and class C: the highest portion of the tooth was below the cervical line of the second mandibular molar.

Data were statistically analyzed in the Statistical Package for Social Sciences (SPSS version 13, SPSS Inc, Chicago, USA), with the Chi-squared test used to test for significant differences. Inter-observer reliability was assessed by using the kappa statistic, which was determined as kappa = 0.86 so there was an acceptable degree of interobserver reliability present.

Results

For eruption levels, i.e., the vertical indices, of the 605 mandibular third molars incorporated in this study, 345 (57%) were at level A, 172 (28.4%) at level B, and 90 (14.6%) at level C. The level A eruption class was found in 45.7% of females and 54.7% of males (Table 1).

There was no significant difference between genders in the impaction level of the mandibular third molars ($P = 0.328$). Of the 605 mandibular third molars, 363 (60%) were defined as class I cases, 212 (35%) as class II, and 31 (5%) as class III. Class I cases were observed in 50.6% of females and 54.2% of males (Table 2).

Pericoronitis was significantly related to partially erupted third molars and impactions of class AII ($P = 0.028$).

Table 1. Number of teeth presenting with pathologies according to the level of impaction

	A	B	C	Total
Pericoronitis	57	36	2	95
2 nd molar caries	36	8	3	47
2 nd molar bone loss	51	72	51	174
3 rd molar caries	85	6	1	92
Root resorption	3	4	7	14
Osteitis	49	16	6	71
Follicular space	0	0	0	0
TMD	62	30	20	112
Total	345	172	90	605

class A: the highest portion of the tooth was level with or above the occlusal plane; class B: the highest portion of the tooth was below the occlusal plane but above the cervical line of the second mandibular molar; and class C: the highest portion of the tooth was below the cervical line of the second mandibular molar

Table 2. Number of teeth presenting with pathologies according to retromolar space.

	I	II	III	Total
Pericoronitis	40	52	3	95
2 nd molar caries	36	10	1	47
2 nd molar bone loss	91	70	13	174
3 rd molar caries	84	6	2	92
Root resorption	8	5	2	14
Osteitis	40	28	3	71
Follicular space	0	0	0	0
TMD	64	41	7	112
Total	363	212	31	605

class I: none of the crown was in the ramus of the mandible; class II: less than one-half of the crown was in the ramus; class III: more than half of the crown was in the ramus

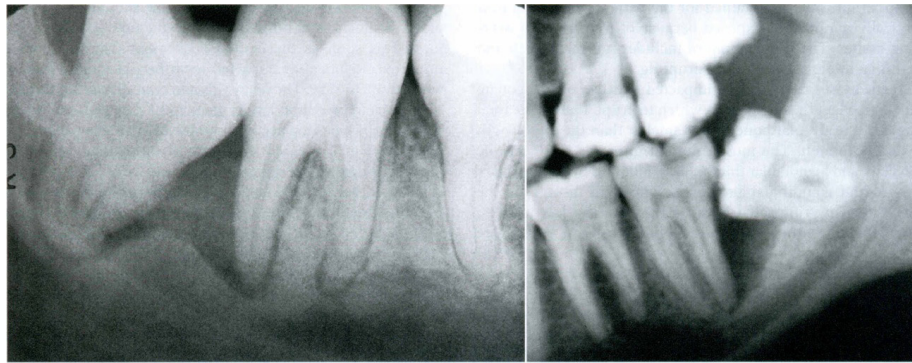


Figure 1. Bone loss mesial to impacted mandibular third molars

For the association between the eight pathological conditions and mandibular third molar impaction depth, when compared with classes B and C, class A cases showed stronger statistical associations with all conditions ($P = 0.04$) except for bone loss and root resorption of second molars ($P = 0.07$). Furthermore, class AI impactions had substantially greater pathological potential when all data were accumulated and analyzed together ($P = 0.35$).

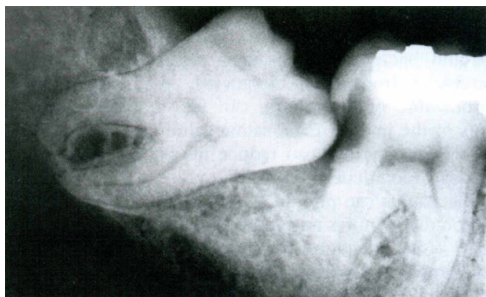

Figure 2. Semi-erupted third molar and adjacent second molar showing evidence of caries

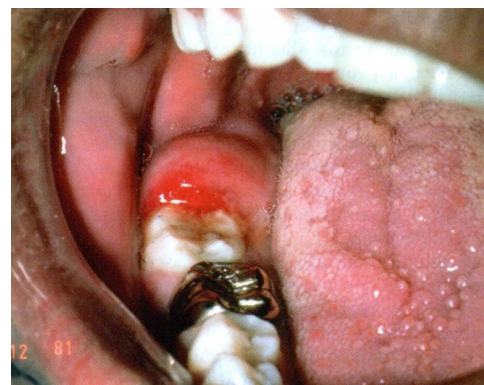


Figure 3. Clinical manifestation of pericoronitis on a semi-erupted third molar

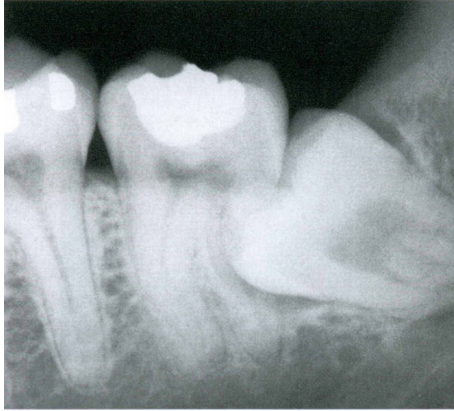


Figure 4. Second molar root resorption due to impacted third molar

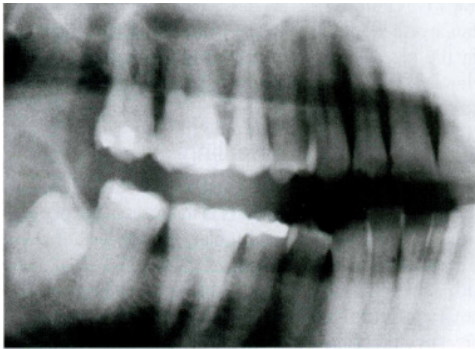


Figure 5. Cystic hyperplasia of impacted molar follicle

Discussion

Although the decision to remove impacted third molars may be one of the most frequent decisions faced in dental practice, controversy remains surrounding the removal of asymptomatic third molars. (1, 12, 13) Some authors believe that all impacted third molars should be extracted whether they are symptomatic or not, because if they later become symptomatic, the risk of post-extraction complications can increase with the patient's age. (14-16) Conversely, other authors believe that due to lack of evidence and knowledge about the incidence of pathologies or the low rate of most complications associated with third molars, the decision to remove asymptomatic third molars is questionable. (13, 14, 17-21) Recent studies suggest that incidence of pathologies associated with retained third molars is low; hence, the most appropriate treatment for asymptomatic impacted third molars in young adults might be observa-

tion instead of prophylactic removal. (5, 17, 22, 23)

The majority of cases in our study presented at least one pathological condition. This is in agreement with most studies showing a high rate of complications. For example, Knutsson et al. (17) observed pericoronitis in 64% of Swedish cases and third molar caries in 31% of cases. Al-Khateeb et al. (6) reported that the prevalence of radiographic lesions around impacted third molars of Jordanians was 46.4%, with caries being the most common type. Another study calculated high probabilities for complications in Spain: 71% for pericoronitis and 47% for cystic complications. (3) In addition, 78% of English patients showed distal cervical caries on at least one mandibular second molar (which are caused by impacted third molars). (4) Furthermore, incidence of cystic changes in the follicle of impacted mandibular third molars has previously been reported at 46%. (24) However, we note that our results were not in agreement with all previous studies. For example, Polat et al. (5) found only 26.5% prevalence of at least one complication in Turkish people. In their study, the most common complication was caries of second molars (12.6%). Two other studies evaluating Turkish people reported only 20% prevalence of distal caries of second molars adjacent to impacted third molars (24), and that the most common complications of impacted third molars were pain (34.3%) and pericoronitis (29.3%). Oenning et al. (25) evaluated the prevalence of external root resorption on distal surface of the second molars and mesial surface of impacted third molars of Brazilian dental patients. They found that, despite conventional radiographs showing only a 5.4% prevalence of external root resorption, cone beam computed tomography (CBCT) showed 22.9% external root resorption on distal surface of second molars. The controversies surrounding these issues suggest that, rather than applying a single guideline to all cases, local protocols are needed to aid decision making for the treatment and monitoring of impacted third molars in different geographical areas. Third molar impaction can have greater importance in particular countries, races, or genders with higher rates of impaction. Such differences can be related to genetics, race, diet, or masticatory forces. (8, 9) For example, in Nigerians, mandibular third molars may erupt as early as 14 years of age (26), where-

as eruption can be delayed until the age of 26 in Europeans.⁽²⁷⁾ Additionally, gender differences in the age at which the third molar erupts and in impaction rates have also been observed.^(8, 27-29) We acknowledge that the present study has some limitations. The study subjects were dental patients, and this could have introduced bias because there might have been a higher chance of observing dental anomalies in this population rather than in a random sample taken from the Iranian population.⁽³⁰⁾ However, following consultation with an ethical committee, we considered it unethical to expose a random group of healthy subjects, who did not require dental treatments, to potentially carcinogenic X-rays for research purposes only.⁽³⁰⁾ The panoramic radiography used in this study is also somewhat limited because it does not properly reveal mild bony or dental/follicular changes such as initial external resorption or caries.⁽²⁵⁾ However, the use of higher resolution devices, such as CBCT, was not possible because of budget limitations. In addition, the cross-sectional nature of study did not allow follow-ups, and sampling from one center limited the results to the population of Shiraz city.

Future studies would ideally use a larger sample size collected from multiple centers, and a more comprehensive set of complications could be reliably investigated by using high-resolution equipment, e.g., CBCT.

Conclusion

In conclusion, impaction depth of the third molars should be taken into consideration when making a decision for prophylactic extraction. Based on the results of our study, prophylactic removal is suggested in cases with class AI impaction.

Acknowledgments

We would like to thank the vice-chancellery of Shiraz University of Medical Sciences for supporting this research. This paper has been developed from the thesis of Dr. Ali Mokhtar and research conducted under the supervision by Dr. Pegah Bronoosh. We also thank Dr. Vossoughi from the Dental Research Development Center for assistance with statistical analysis.

References

1. Akarlan ZZ, Kocabay C. Assessment of the associated symptoms, pathologies, positions and angulations of bilateral occurring mandibular third molars: is there any similarity? *Oral Surg Oral Med Oral Pathol Oral Radiol Endod* 2009;108(3):e26-32.
2. Doğan N, Orhan K, Günaydin Y, Köymen R, et al. Unerupted mandibular third molars: symptoms, associated pathologies, and indications for removal in a Turkish population. *Quintessence Int* 2007;38(8):e497-505.
3. Almendros-Marqués N, Berini-Aytés L, Gay-Escoda C. Influence of lower third molar position on the incidence of preoperative complications. *Oral Surg Oral Med Oral Pathol Oral Radiol Endod* 2006;102(6):725-32.
4. McArdle LW, Renton TF. Distal cervical caries in the mandibular second molar: an indication for the prophylactic removal of the third molar? *Br J Oral Maxillofac Surg* 2006; 44(1):42-5.
5. Polat HB, Özan F, Kara I, Özdemir H, Ay S. Prevalence of commonly found pathoses associated with mandibular impacted third molars based on panoramic radiographs in Turkish population. *Oral Surg Oral Med Oral Pathol Oral Radiol Endod* 2008;105(6):e41-7.
6. Al-Khateeb TH, Bataineh AB. Pathology associated with impacted mandibular third molars in a group of Jordanians. *J Oral Maxillofac Surg* 2006;64(11):1598-602.
7. Yamalik K, Bozkaya S. The predictivity of mandibular third molar position as a risk indicator for pericoronitis. *Clin Oral Investig* 2008;12(1):9-14.
8. Juodzbaly G, Daugela P. Mandibular third molar impaction: review of literature and a proposal of a classification. *J Oral Maxillofac Res* 2013;4(2):e1.
9. Alling CC, Alling RD. Indications for management of impacted teeth. In: Alling CC, Helfrick JF, Alling RD, editors. Philadelphia: W.B. Saunders; 1993. p. 49-54.
10. DeAngelis AF, Chambers IG, Hall GM. Temporomandibular joint disorders in patients referred for third molar extraction. *Aust Dent J* 2009;54(4):323-5.
11. Adeyemo WL. Do pathologies associated with impacted lower third molars justify prophylactic removal? A critical review of the literature. *Oral Surg Oral Med Oral Pathol Oral Radiol Endod* 2006;102(4):448-52.

12. Song F, Landes DP, Glenny AM, Sheldon TA. Prophylactic removal of impacted third molars: an assessment of published reviews. *Br Dent J* 1997;182(9):339-46.
13. Eliasson S, Heimdahl A, Nordenram Å. Pathological changes related to long-term impaction of third molars. A radiographic study. *Int J Oral Maxillofac Surg* 1989;18(4):210-2.
14. Güven O, Keskin A, Akal UK. The incidence of cysts and tumors around impacted third molars. *Int J Oral Maxillofac Surg* 2000;29(2):131-5.
15. Hinds EC, Frey KF. Hazards of retained third molars in older persons: report of 15 cases. *J Am Dent Assoc* 1980;101(2):246-50.
16. Haraji A, Rakhshan V. Single-dose intra-alveolar chlorhexidine gel application, easier surgeries, and younger ages are associated with reduced dry socket risk. *J Oral Maxillofac Surg* 2014;72(2):259-65.
17. Knutsson K, Brehmer B, Lysell L, Rohlin M. Pathoses associated with mandibular third molars subjected to removal. *Oral Surg Oral Med Oral Pathol Oral Radiol Endod* 1996;82(1):10-7.
18. Kostopoulou O, Brickley MR, Shepherd JP, Newcombe RG, et al. Intra-observer reliability regarding removal of asymptomatic third molars. *Br Dent J* 1998;184(11):557-9.
19. van der Linden W, Cleaton-Jones P, Lownie M. Diseases and lesions associated with third molars: review of 1001 cases. *Oral Surg Oral Med Oral Pathol Oral Radiol Endod* 1995;79(2):142-5.
20. Worrall SF, Riden K, Haskell R, Corrigan AM. UK National Third Molar project: the initial report. *Br J Oral Maxillofac Surg* 1998;36(1):14-8.
21. Mercier P, Precious D. Risks and benefits of removal of impacted third molars: a critical review of the literature. *Int J Oral Maxillofac Surg* 1992;21(1):17-27.
22. Berge TI, Bøe OE. Symptoms and lesions associated with retained or partially erupted third molars: some variables of third-molar surgery in Norwegian general practice. *Acta Odontol Scand* 1993;51(2):115-21.
23. Berge TI. Third molars in Norwegian general dental practice. *Acta Odontol Scand* 1992;50(1):17-24.
24. Saravana GH, Subhashraj K. Cystic changes in dental follicle associated with radiographically normal impacted mandibular third molar. *Br J Oral Maxillofac Surg* 2008;46(7):552-3.
25. Oenning ACC, Neves FS, Alencar PNB, Prado RF, et al. External root resorption of the second molar associated with third molar impaction: comparison of panoramic radiography and cone beam computed tomography. *J Oral Maxillofac Surg* 2014;72(8):1444-55.
26. Odusanya SA, Abayomi IO. Third molar eruption among rural Nigerians. *Oral Surg Oral Med Oral Pathol* 1991;71(2):151-4.
27. Kruger E, Thomson WM, Konthasinghe P. Third molar outcomes from age 18 to 26: findings from a population-based New Zealand longitudinal study. *Oral Surg Oral Med Oral Pathol Oral Radiol Endod* 2001;92(2):150-5.
28. Hattab FN, Abu Alhaija ESJ. Radiographic evaluation of mandibular third molar eruption space. *Oral Surg Oral Med Oral Pathol Oral Radiol Endod* 1999;88(3):285-91.
29. Yuasa H, Sugiura M. Clinical postoperative findings after removal of impacted mandibular third molars: prediction of postoperative facial swelling and pain based on preoperative variables. *Br J Oral Maxillofac Surg* 2004;42(3):209-14.
30. Amini F, Rakhshan V, Babaei P. Prevalence and pattern of hypodontia in the permanent dentition of 3374 Iranian orthodontic patients. *Dent Res J (Isfahan)*. 2012; 9(3):245-50.