

Pharyngeal Airway: An Analysis Using 2D vs. 3D Images in Different Malocclusions

Original Article

Bronoosh Pegah¹, Khojastepour Leila², Charlie Mohammad Shabnam³

¹Assistant Professor, Department of Oral and Maxillofacial Radiology, Dental School, Shiraz University of Medical Science, Shiraz, Iran.

²Professor, Department of Oral and Maxillofacial Radiology, Faculty of Dentistry, Shiraz University of Medical Science, Shiraz, Iran.

³Students' Research Committee, Dental school, International Branch, Shiraz University of Medical Science, Shiraz, Iran.

Received: 4 Mar 2015

Accepted: 18 May 2015

Corresponding Author:

Leila Khojastepour

Address:

Department of Oral and Maxillofacial Radiology, Dental School, Shiraz University of Medical Science, Shiraz, Iran.

E-mail: khojastl@sums.ac.ir

Telephone: +989173158331

Abstract

Introduction: The aim of this study was to compare information regarding pharyngeal airway sizes in adolescent subjects with different malocclusion classes obtained from lateral cephalograms and 3-dimensional (3D) cone-beam computed tomography (CBCT) scans.

Materials and methods: In this prospective cross-sectional study, CBCT scans and lateral cephalograms of 35 subjects, taken within one week, were included. Measurements of the pharyngeal airway area from the lateral cephalograms and airway volume from the CBCT scans were analyzed using one-way ANOVA; post-hoc tests were used for comparison of the airway area and volume in different malocclusion classes. A linear regression of the airway area to volume was performed to discern associations and determine correlation coefficients. Descriptive statistics for airway dimensions were determined.

Results: No significant differences were detected between the sexes for any measurement; therefore, all data were combined. Regression analysis showed that for every mm² increase in airway area, there was a corresponding 11.94-mm³ increase in mean airway volume. One-way ANOVA and post-hoc tests demonstrated significant differences in airway area and volume between the three malocclusion classes ($p < 0.001$). The highest mean airway area and volume was observed in class III malocclusion, followed by classes I and II malocclusion.

Conclusion: Pharyngeal airway area, as measured on the lateral cephalogram, concurs with volumetric data. However, accurate determination of airway volume and shape is achieved by 3D imaging, owing to great variability in the shape of the pharyngeal air space.

Key words:

•Cephalometry •Cone-Beam Computed Tomography •Pharynx

Introduction

The relationship between respiratory pattern disorders and changes in facial morphology has been extensively debated in the literature.^(1, 2) Neuromuscular adaptations, nasopharyngeal obstruction, growth, breathing, and speech are seriously affected by airway function.⁽³⁾ Further, upper airway dimensions have been considered to be contributing factors to obstructive sleep apnea. This factor is very important, particularly in growing patients with skeletal discrepancies and clinical signs of adenoid facies.⁽⁴⁾

Therefore, early diagnosis of any change in normal airway function is critical to ensure normal facial development.

Brusse seems to be the first person to have reported that airway disorder is a common cause of malocclusion and leads to the classic appearance of adenoid facies.⁽⁵⁾ Other studies evaluated the upper airway in patients with different skeletal patterns.⁽⁶⁻¹⁰⁾ Commonly, lateral cephalograms have been used to analyze the dimensions of the upper airway in patients with different sagittal and vertical skeletal facial morphologies.⁽⁹⁻¹¹⁾

Lateral cephalograms still play an important role in the early assessment of the pharyngeal airway⁽¹²⁾; however, this diagnostic approach to examine anatomical features of the airway is inadequate.⁽¹³⁾ A 2-dimensional (2D) representation of a 3-dimensional (3D) structure causes severe limitations such as distortion, differences in magnification, and superimposition of bilateral craniofacial structures.⁽¹⁴⁻¹⁶⁾ Another limitation of this radiograph is the lack of information regarding cross-sectional area and volume.

In recent times, cone-beam computed tomography (CBCT) technology has aided in the evaluation of airways and acted as a diagnostic instrument in this area. With CBCT, 3D objects are reconstructed from raw data; hence, magnification is not an issue.

The image generated by CBCT is isotropic and linear, and angular measurements are reliable and anatomically accurate.⁽¹⁷⁾

Our aim, in this study, was to compare imaging information about pharyngeal airway size obtained from lateral cephalograms and CBCT scans of adolescent subjects with different malocclusion classes.

Materials and Methods

All consecutive adolescents referred to a private imaging center for CBCT imaging were included in this study over eight months. The project was approved by the Committee on Research at Shiraz University of Medical Science, International Branch.

All subjects had a CBCT scan and lateral cephalograms taken less than 1 week apart. Subjects were excluded from the study if they wore a bite splint, had a documented craniofacial anomaly, or had undergone orthognathic surgery. The most common reason for exclusion of a subject was that the two imaging procedures were not performed within 1 week of each other. We examined 98 possible subjects, and only 35 met the inclusion criteria.

The 2D lateral cephalograms were taken under standardized conditions with a magnification of 1.3%. All radiographs were scanned using Adobe Photoshop 6.0 (Adobe Systems, San Jose, CA, USA) with the following settings: document source, TPU for positive film; image type, 24-bit color; resolution, 150 dots per inch (dpi); and 1200 × 1600 pixels.

Three-dimensional CBCT volume scans were performed using the NewTom VGi computed tomography machine (Quantitative Radiology, Verona, Italy) with maximum field of view (FOV = 15 × 15 cm).

Lateral cephalograms studies of the airway have included both linear and area measurements based on specific cephalometric landmarks and classification of malocclusion.

In our study, The following anatomical structures, as seen on the lateral cephalograms, were used to define the boundaries of the pharyngeal airway in all subjects: (1) the superior border was defined by the edge of the hard palate to the posterior of the pharynx (extension of anterior nasal spine to posterior nasal spine); (2) the inferior border was determined by the tip of the epiglottis on a plane parallel to line 1; and (3) the plane extending from the posterior nasal spine to the inferior border and perpendicular to the line 1 and 2 marked the anterior border (Figure 1A). The same planes were transferred to the 3D scans to measure airway volume over the same anatomical boundaries (Figure 1B).

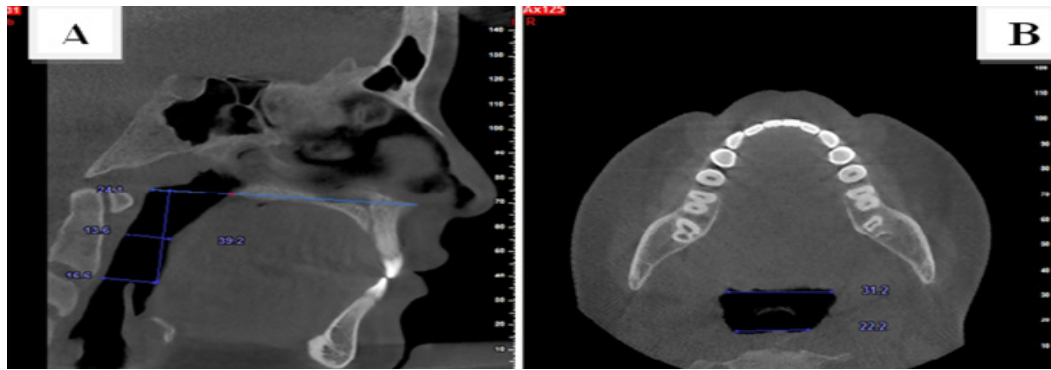

Figure 1. (A) sagittal cross section through mid sagittal plane shows the superior & inferior border of region of interest. (B) Axial cross section through epiglottis show area of region of interest at the level of epiglottis.

The CBCT axial reconstruction plane was re-oriented for each subject based on three reference planes: axial, coronal, and sagittal. Airway volumes were determined from the summation of the airway area by using 1 mm axial CBCT slices over the vertical height of the pharyngeal airway determined from the lateral cephalograms. The skeletal malocclusions of the subjects were then classified as per Angle’s classification (Classes I–III) using the lateral cephalograms. Thereafter, the following measurements of the pharyngeal airway were obtained: (a) airway area of the region of interest from the lateral cephalograms; and (b) airway volume over the same of region of interest from the CBCT scan, with all segmented 3D volumes included in this study.

A linear regression of the airway area to volume was performed to discern associations and determine correlation coefficients. Descriptive statistics for airway dimensions were determined. All statistical analyses were performed using SPSS v.18 (SPSS Inc., Chicago, IL, USA).

Results

The comparison of 3D and 2D measurements of the pharyngeal airway between the two sexes revealed that both area and volume were greater in male subjects but not statistically significant.

The area measurements obtained using the lateral cephalometric approach and volumetric measurements obtained using CBCT indicated a distinct difference between the two approaches. There was more variability in volume than in area, when analyzed as a percentage of the mean values. There was also a much wider range in the volume when determined as a percentage of the mean values (Table 1).

The overall area-to-volume linear regression (Figure 2) demonstrated a positive association between the measurements with a moderately high correlation coefficient value ($r = 0.831$; $p < 0.001$). Regression analysis showed that for every mm^2 increase in mean airway area, there is a corresponding 11.94-mm^3 increase in mean airway volume.

Table 1. Descriptive statistics of airway area and volume according to malocclusion type.

Malocclusion type	measure ment	n	Mean± SD	Max	Min	r	P value
Total	Area mm2	35	325.24±85.38	540.13	205.2100	0.831	0.000
	Volume mm3	35	3398.11±1226.85	5876.12	1835.23		
classI	Area mm2	7	361.281 ±36.07	403.05	316.1400	0.327	0.474
	Volume mm3	7	4223.265±388.978	4834.20	3711.700		
classII	Area mm2	19	263.002±33.764	315.23	205.2100	0.374	0.115
	Volume mm3	19	2383.05±361.493	2989.80	1835.2300		
classIII	Area mm2	9	428.633±71.299	540.13	322.3500	0.125	0.748
	Volume mm3	9	4899.25±641.562	5876.12	3827.3500		

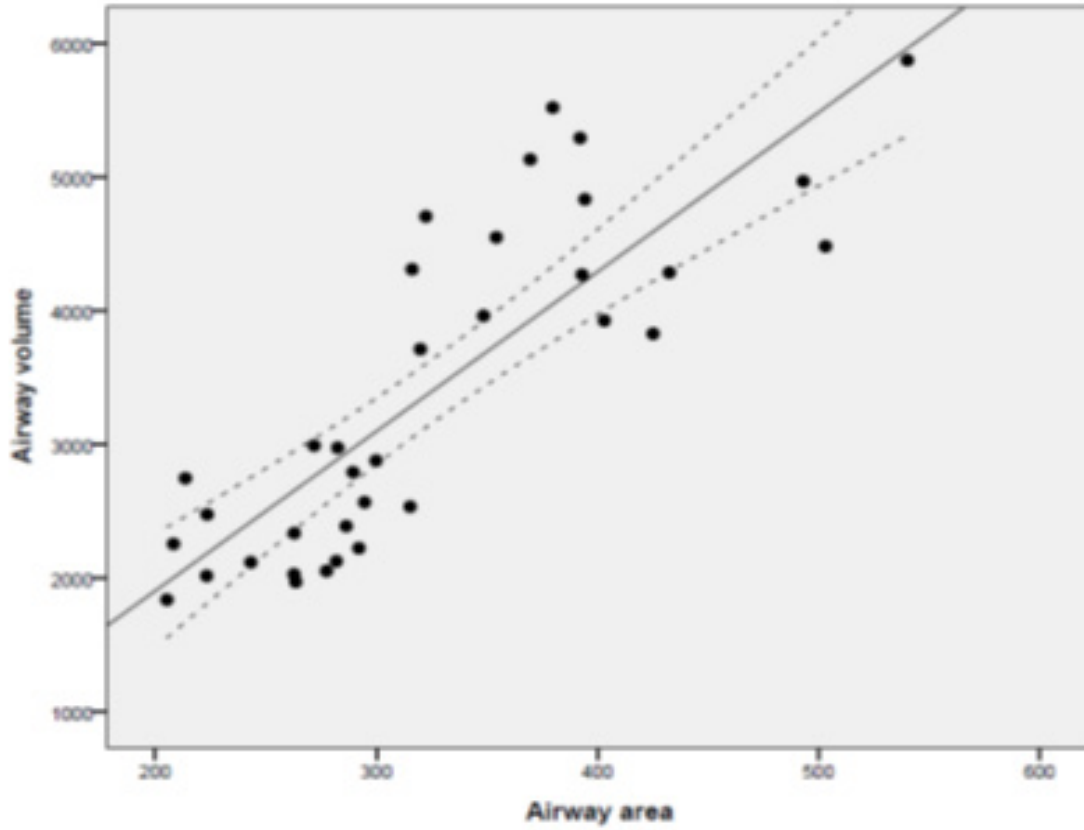


Figure 2. Linear regression plot comparing area with volume.

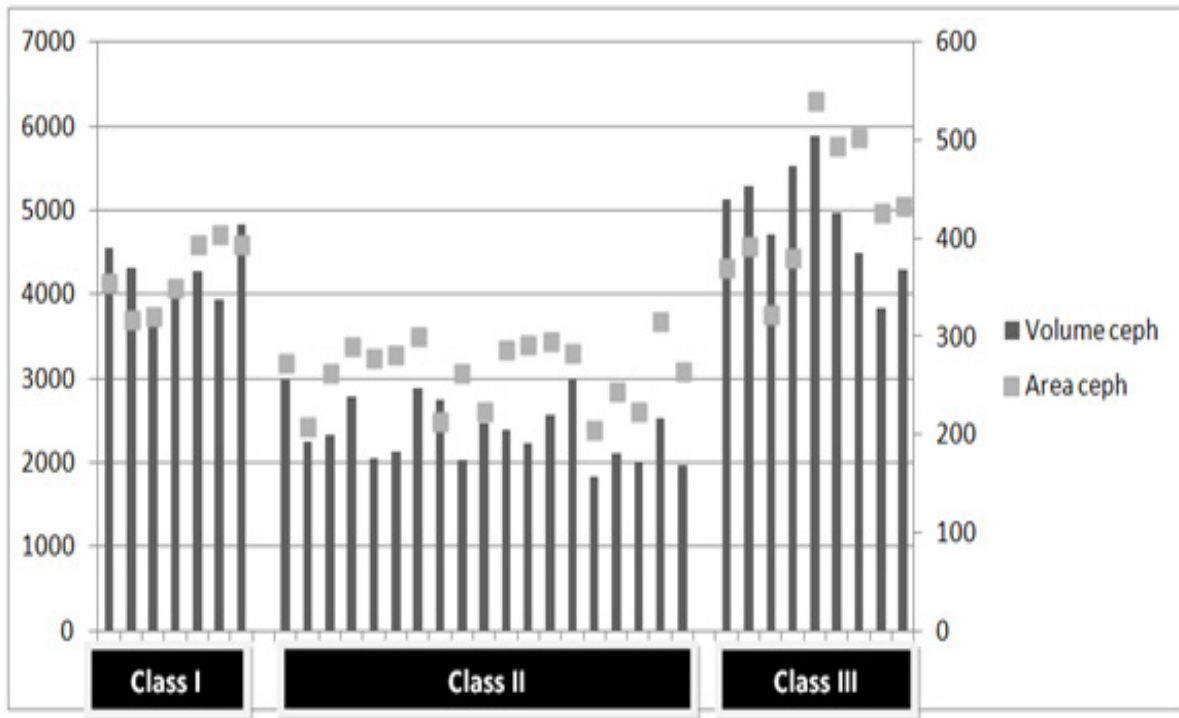


Figure 3. Area and volume in increasing order for the subjects with the same malocclusion type.

One-way ANOVA and post-hoc tests showed that there were significant differences in area and volume among the three classes of malocclusion ($P < 0.001$). The highest mean values for airway area and volume were observed in class III malocclusion, followed by classes I and II (Table 1). As the area-to-volume regression plot shows a moderately high correlation, much airway volume variability could be seen over high changes in airway area when the individual data were viewed and sorted, based on the type of malocclusion (Table 1). Over the midrange of the sample, there was much variability in the airway volume for similar airway areas (Fig 3). The area varied over a narrow range, between 250 and 400 mm², for many subjects; yet, the volume varied from 2000 to 6000 mm³, with most values in the range of 2000 to 3000 mm³.

Discussion

Previous studies on the airway attempted to quantify airway restriction and function by morphologic or functional measurements.⁽¹⁸⁻²²⁾ Lateral cephalometric films have been mostly used for upper airway evaluation in orthodontics, with specific landmarks to characterize the airway.⁽²²⁾ This study was primarily designed to determine the clinical value of cephalometric films as a tool for pharyngeal airway assessment, compared with quantification of the 3D morphology of the pharyngeal airway using CBCT scans. Our data were retrospective and cross-sectional, so no attempt was made to correlate the subjects' facial morphology with individual airway size.

CBCT scans in the present study were taken in an upright position to avoid airway space modification between radiographs taken in supine and upright positions. The overall patency of the pharyngeal airway can be assessed through cephalometric films. However, there is a notion that 2D view of the airway space does not give an accurate indication of the complexity of this structure or its true size. Results of the present study showed that subjects with smaller airway area, as seen on the lateral cephalograms, had smaller corresponding airway volume; thus, the lateral cephalograms can provide valuable information about severe airway restriction, as well as the morphology of the airway space. Unfortunately, we cannot generalize the results owing to the limitations of a small sample size and single

imaging center.

The results also showed that there were significant differences in airway area and volume between the three classes of malocclusion. The highest mean values for both area and volume were observed in class III malocclusion, followed by classes I and II. This is a starting point for enhancing the ability of anesthesiologists to manage the airway in patients known or suspected to be difficult to intubate. In these cases, a lateral cephalograms may be of more value than clinical tools such as history and examination. CBCT technology gives a new insight into anatomical landmarks not visible on 2D cephalograms. It allows measurement of real distances and angles that help to evaluate correctly the growth and development of the craniofacial complex.⁽²³⁾

Clinical malocclusion is a 3D manifestation; however, a clinician usually focuses on anteroposterior correction instead of evaluating vertical and transverse dimensions as well. Therefore, besides airway assessment from a 3D aspect, CBCT images have the potential for description of a 3D malocclusion.

Since we did not perform functional tests in this study, we cannot introduce a threshold to demonstrate to what extent airway volume can affect function. Further studies are needed to expand our understanding of this subject.

Some studies admit that resistance to airflow is related to both size and shape of the airway passage.^(24, 25) Three-dimensional evaluation of the airway may also help to better discriminate the pharyngeal airway shape and diagnose airway problems more effectively.

Conclusion

There is a significant positive relationship between pharyngeal airway area on a lateral cephalogram and its true volumetric size on a CBCT scan. However, accurate determination of airway volume and shape is achieved by 3D imaging, owing to great variability in the shape of the pharyngeal air space.

Acknowledgment

This paper has been extracted from Ms. Shabnam Charlie's DDS thesis that was conducted under the supervision of Dr. Bronoosh P. and advisory of Dr. Khojastepour L. The study was ap-

proved and registered with the ID 8693064. We would like to thank the vice-chancellor of Shiraz University of Medical Sciences, International Branch, for supporting this research. We also thank Dr. Mehrdad Vossoughi from the Dental Research Development Center for the statistical analyses.

References

1. McNamara JA. Influence of respiratory pattern on craniofacial growth. *Angle Orthod* 1981; 5:269–300.
2. Vig KW. Nasal obstruction and facial growth: the strength of evidence for clinical assumptions. *Am J Orthod Dentofacial Orthop* 1998; 113:603–11.
3. McNamara JA. Naso-Respiratory Function and Craniofacial Growth. Ann Arbor, MI, University of Michigan: Craniofacial Growth series; 1979.
4. Haskell JA, McCrillis J, Haskell BS, Scheetz JP, et al. Effects of mandibular advancement device (MAD) on airway dimensions assessed with cone-beam computed tomography. *Semin Orthod* 2009; 15:132–58.
5. Brusse AB. Orthodontics as an aid to the rhinologist. *Int J Orthod and Dent for Childr* 1935; 21:646–8.
6. Grauer D, Cevidanes LS, Styner MA, Ackerman JL, et al. Pharyngeal airway volume and shape from cone-beam computed tomography: relationship to facial morphology. *Am J Orthod and Dentofacial Orthop* 2009;136:805–14.
7. Iwasaki T, Saitoh I, Takemoto Y, Inada E, et al. Evaluation of upper airway obstruction in Class II children with fluid-mechanical simulation. *Am J Orthod and Dentofacial Orthop* 2011;139:e135–e45.
8. Kim YJ, Hong JS, Hwang YI, Park YH. Three-dimensional analysis of pharyngeal airway in preadolescent children with different anteroposterior skeletal patterns. *Am J Orthod and Dentofacial Orthop* 2010;137:306–e1.
9. Muto T, Yamazaki A, Takeda S. A cephalometric evaluation of the pharyngeal airway space in patients with mandibular retrognathia and prognathia, and normal subjects. *Int J Oral and Maxillofac Surg* 2008;37:228–31.
10. Zhong Z, Tang Z, Gao X, Zeng XL. A comparison study of upper airway among different skeletal craniofacial patterns in nonsnoring Chinese children. *Angle Orthod* 2010;80:267–74.
11. Farid MM, Metwalli N. Computed tomographic evaluation of mouth breathers among pediatric patients. *Dentomaxillofac Radiol* 2010; 39:1–10.
12. Major MP, Flores-Mir C, Major PW. Assessment of lateral cephalometric diagnosis of adenoid hypertrophy and posterior upper airway obstruction: a systematic review. *Am J Orthod Dentofacial Orthop* 2006; 130:700–8.
13. Vig PS, Hall DJ. The inadequacy of cephalometric radiographs for airway assessment. *Am J Orthod* 1980; 77:230–3.
14. Baumrind S, Frantz RC. The reliability of head film measurements. 1. Landmark identification. *Am J Orthod* 1971; 60:111–27.
15. Baumrind S, Frantz RC. The reliability of head film measurements. 2. Conventional angular and linear measures. *Am J Orthod* 1971; 60:505–17.
16. Ahlqvist J, Eliasson S, Welander U. The effect of projection errors on cephalometric length measurements. *Eur J Orthod* 1986; 8:141–8.
17. Baumgaertel S, Palomo JM, Palomo L, Hans MG. Reliability and accuracy of cone-beam computed tomography dental measurements. *Am J Orthod Dentofacial Orthop* 2009; 136:19–25.
18. Holmberg H, Linder-Aronson S. Cephalometric radiographs as a means of evaluating the capacity of the nasal and nasopharyngeal airway. *Am J Orthod* 1979; 76:479–90.
19. Schwab RJ, Goldberg AN. Upper airway assessment: radiographic and other imaging techniques. *Otolaryngol Clin North Am* 1998; 31:931–68.
20. Linder-Aronson S. Adenoids: their effect on mode of breathing and nasal airflow, and their relationship to characteristics of the facial skeleton and the dentition. A biometric, rhinomanometric, and cephalometro-radiographic study on children with and without adenoids. *Acta Otolaryngol Suppl* 1970; 265:1–132.
21. Linder-Aronson S, Henrikson C. Radiocephalometric analysis of anteroposterior nasopharyngeal dimensions in 6 to 12-year-old mouth breathers compared with nose breathers. *ORL J Otorhinolaryngol Relat Spec* 1973;35(1):19-29.
22. Schwab R. Upper airway imaging. *Clin Chest Med* 1998; 19:33–54.
23. Mah JK, Huang JC, Choo H. Practical applications of cone-beam computed tomography in orthodontics. *J Am Dent Assoc* 2010; 141 Suppl 3:7S–13S.
24. Sorensen H, Solow B, Greve E. Assessment of the nasopharyngeal airway. A rhinomanometric and radiographic study in children with adenoids. *Acta Otolaryngol* 1980; 89:227–32.
25. Montgomery W, Vig P, Staab E, Matteson S. Computed tomography: a three-dimensional study of the nasal airway. *Am J Orthod* 1979; 76:363–75.